

AN ATLAS OF
ANIMAL ANATOMY
FOR ARTISTS

BY W. ELLENBERGER, H. BAUM AND
H. DITTRICH

Second Revised and Expanded Edition

Edited by LEWIS S. BROWN, Exhibition Department, American Museum of Natural History

DOVER PUBLICATIONS, INC., NEW YORK

COPYRIGHT © 1949, 1956 BY DOVER PUBLICATIONS, INC.

All rights reserved under
Pan American and International Copyright Conventions.

Published in Canada by General Publishing Company, Ltd., 30 Lesmill Road,
Don Mills, Toronto, Ontario.

An Atlas of Animal Anatomy for Artists, first published in 1949 by Dover Publications, Inc., is a new English translation by Helene Weinbaum of *Handbuch der Anatomie der Tiere für Künstler*, originally published by Theodore Weicher, Leipzig, in 1901.

The second revised English edition, edited by Lewis S. Brown and first published in 1956 by Dover Publications, Inc., contains a new Preface, 25 additional plates and an enlarged bibliography.

International Standard Book Number: 0-486-20082-5

Library of Congress Catalog Card Number: 56-14001

Manufactured in the United States of America

DOVER PUBLICATIONS, INC.

180 Varick Street


New York, N. Y. 10014

Preface to Second Revised American Edition

I have undertaken with a glad heart the preparation of this new edition of the incomparable Ellenberger, Baum, and Dittrich ATLAS OF ANIMAL ANATOMY FOR ARTISTS. When Dover Publications first approached me, they told me they intended to enrich the book by the addition of plates by George Stubbs and others, as well as a bibliography to suggest further study. I appreciate the freedom they have given me in my efforts to carry out those wishes.

Our first edition contained all of the plates from the original Ellenberger work, published in 1901 in five volumes. Only a part of the German text was omitted, most of it more technical than is generally warranted by the needs of artists. The real message is contained in the plates themselves. It is a larger message than may be apparent at first, including, as it does, the directive to compare the different forms as well as to study them separately. The choice of the horse, the dog, the cow, and the lioness was not an accident. Although all are of the class *Mammalia*, each is a member of a different order. The horse is of the order *Perissodactyla* (*perissos*—odd, *dactylos*—toe), an animal having an odd number of toes. It includes the zebra, the tapir, and the rhinoceros as well as the horse. The cow belongs to a larger order, *Artiodactyla* (*artios*—even, *dactylos*—toe). Other animals of this order are the pig, the camel, the antelope, the goat, the deer, the giraffe, and the hippopotamus, to mention a few. The lioness and the dog are of the order *Carnivora* (*carno*—flesh, *vorare*, to eat). The first two orders, you will notice, are based on the development of the legs while the third is based on the teeth.

In selecting material to expand this edition, I have kept in mind this comparative aspect. The quality of the Ellenberger plates is so fine that it has not been easy to find even a few more, strictly anatomical, studies from which could be made selections worthy to stand beside them. The engravings of the horse by George Stubbs are taken from his *ANATOMY OF THE HORSE*, published in 1776. George Stubbs has taken his place among England's great sporting artists. Although these anatomical studies were made under conditions that would be considered almost impossible today, his results speak for themselves. The $\frac{3}{4}$ view and the rear view form an excellent supplement to the Ellenberger plates on the horse. In the original work, numbered and lettered tracings accompany the anatomical plates to designate the names of the bones and muscles. The functions of the muscles were not understood in Stubbs' day as they are now, so



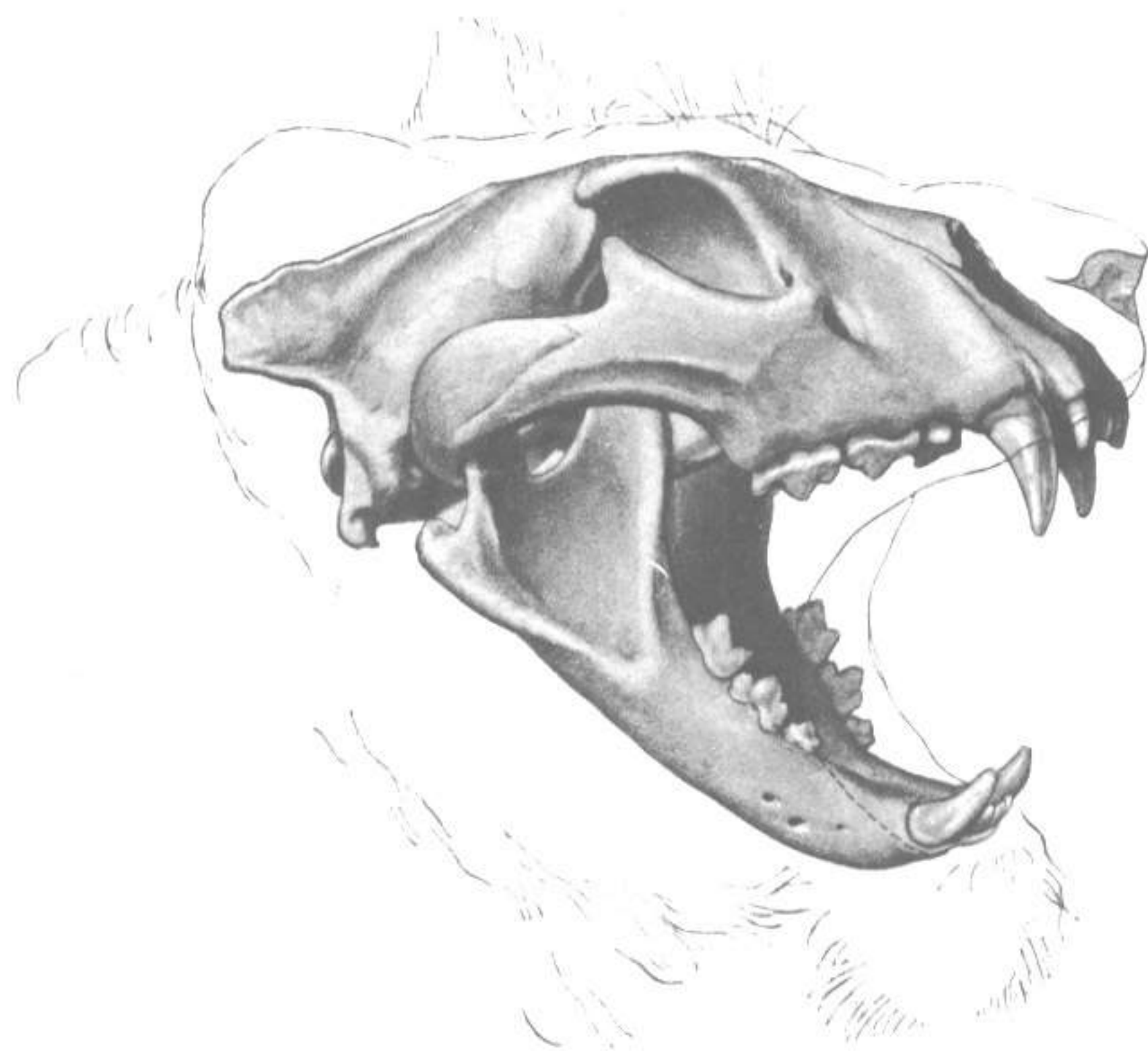
that much of the anatomical description does not agree with later (and present-day) descriptions as found in Ellenberger. To include them would probably be more confusing than helpful to the student.

The four plates on the anatomy of the cat are selected from the *ANATOMIE DESCRIPTIVE ET COMPARATIVE DU CHAT* by Hercole Straus-Durckheim, published in 1845. The same objection to the designations of the muscle names exists as in the case of Stubbs. Consequently, no names are given. The Cuvier plates are from *ANATOMIE COMPARÉE* by George Cuvier and M. Laurillard, published in 1849. This is a giant volume which contains many more plates of equal merit, but the ones selected allow us to extend our study of comparisons to four more orders of mammals. The hare and the flying squirrel are of the order *Rodentia* (*rodere*—to gnaw); the rat kangaroo, of the order *Marsupialia* (*marsupium*—pouch); the bat, of the order *Chiroptera* (*chiro*—hand, *pteron*—wing). The monkey, like man, belongs to the order *Primates* (*primus*—first). Although the seal, because of its teeth, is classed with the carnivores, it is worth including because it is a mammal that has adapted itself to the sea. The flying squirrel is a link between the earth and the air while the bat, as much a mammal as the rest, has made itself entirely independent of the ground.

The amazing thing to me about all this is how much alike these animals are. The parts which they have in common far exceed those which each has alone. All are built around much the same skeletons. It is easy to locate a scapula, an elbow, a wrist on every one although the wrist on a monkey or man, may be called a knee on the horse or the cow. That is merely a confusion of terms, not a difference in structure. If one cared to look carefully enough, he would find that the attachments of the muscles in the different animals are the same. True, the sizes and shapes of the bones and muscles differ, and some of each have been discarded when no longer needed. The bones and muscles in the feet of horses are simpler and are easier to understand than those of most of the rest.

This leads us naturally into the subject of evolution. All the mammals shown in this book, or in any other for that matter, had a common ancestor which we are convinced lived in the closing ages of the huge reptilian dinosaurs. From it have arisen such different forms as the bat, the horse, the whale; a small animal that flies through the air, a large animal that runs across the land, and a huge animal that never leaves the water. Of all the animals included in this book, the rat kangaroo most resembles the common ancestor form.

Ernest Thomson Seton in his book, *ANIMAL ANATOMY FOR ARTISTS*, instructed his readers to consider the dog as the average mammal and to make it a first study from which to branch out into the study of other forms. This is a sensible suggestion as the dog is not as specialized as, for instance, the horse. However, for a number of reasons, I, myself, did my initial study of animal anatomy on the horse. It is, first of all, one of the simplest animals in structure. It is highly specialized with but a single toe on each foot and a fusion of bones in the legs. It has specialized joints which greatly limit the possible action. Secondly, there is a comparative wealth of easily accessible material on it. In addition, there are several



good comparisons of the horse form to the human form which allow the student readily to use what knowledge of human anatomy he may already possess to understand the quadripedal form. For these reasons, I have included more material in the appendix and in the bibliography on the horse than on any other animal.

Lastly, I have inserted a trifle on the sizes of the animals shown. I have added from the original edition those measurements by Ellenberger which pertain to horses of a kind to be found in this country at the present time. All the measurements are given in feet and inches.

A NOTE ON STRUCTURE

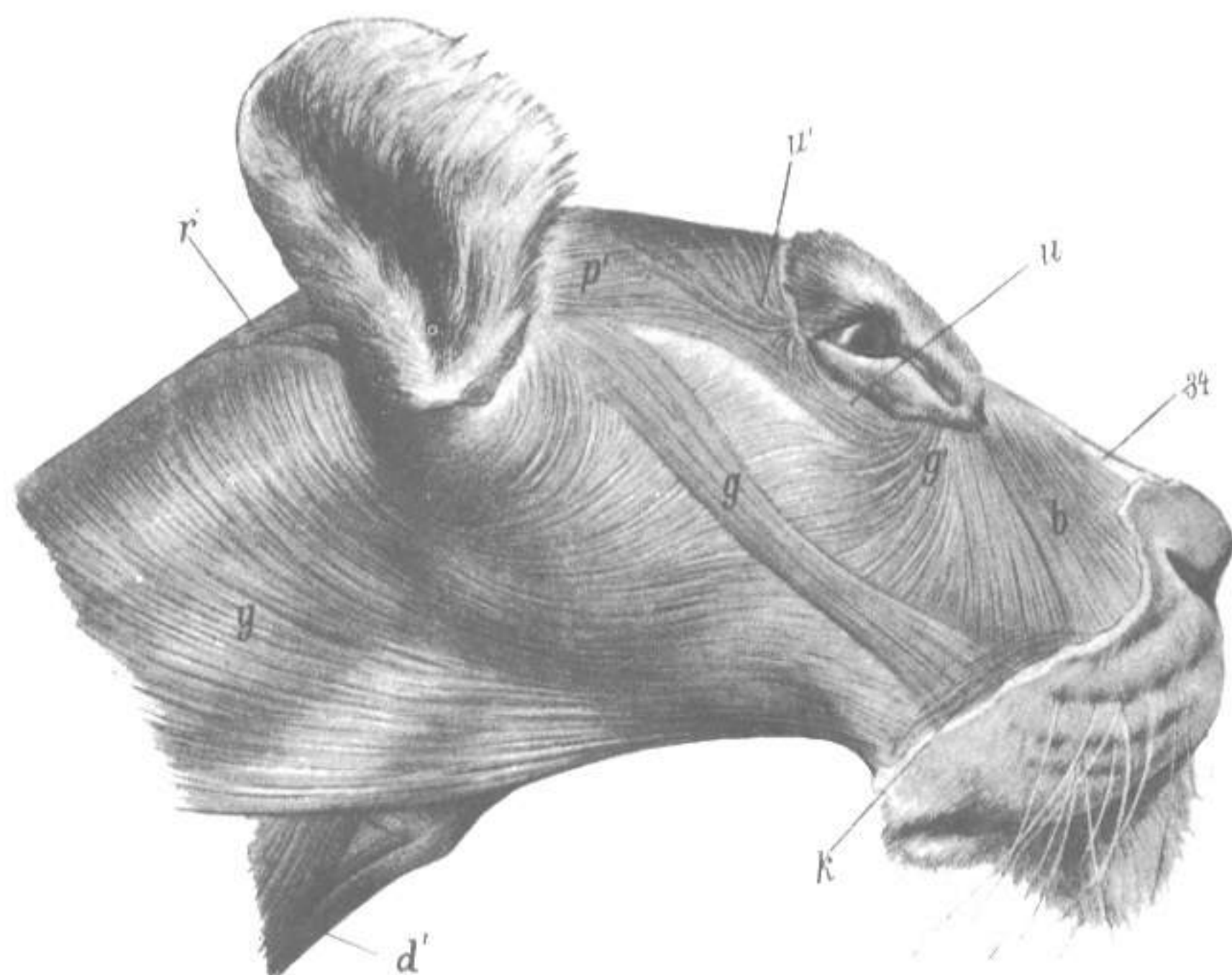
All of the plates in this volume, designed primarily for the artist, deal only with the bones and muscles. In the Ellenberger, Baum, and Dittrich plates, a uniformity of part designations exists. For instance, the last muscle shown in the side view of the body of the horse, the dog, the lioness, the cow, the goat, the stag, and the roe is the *M. Semitendonsis*, and in each case designated by the small letter *r*. With few exceptions, numbers are used for the bones and letters for the muscles.

The animals shown have in common a skeleton framework comprised of a series of bones joined together and placed at certain definite angles to each other. At the joints, the bones are held together by ligaments. A ligament is a band of white fibrous tissue, pliant and flexible, to allow movement at the joint, but tough, strong, and inelastic. It does not contract as does a muscle. Between the bones at the joints is a padding or cushion of cartilage, a pearly white, gristly substance. It is also found in passages which must be kept open such as the nostrils and the ears.

The muscles are the motors of the body which cause movement. They are formed by bundles of reddish fibers endowed with the property of contractability. The muscles are connected to the bones, cartilage, or ligaments either directly or by tendons or aponeuroses. Tendons are white, glistening, fibrous cords varying in thickness and in length, sometimes round, sometimes long and flattened, of considerable strength and slight elasticity. Aponeuroses are fibrous membranes similar in structure to tendons. Tendons and aponeuroses are connected to the muscles at one end and to the movable bones, cartilage, and ligaments at the other.

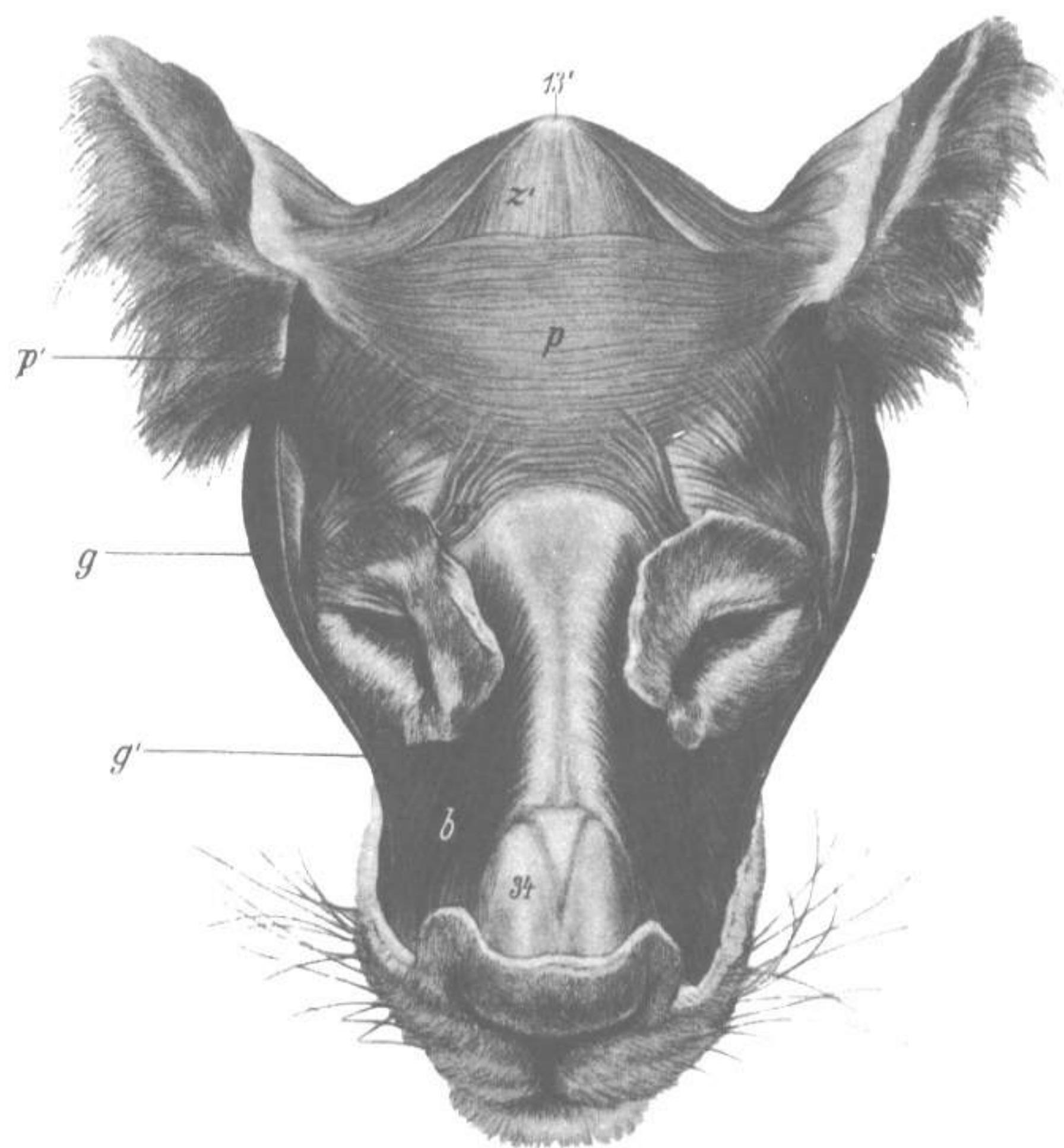
Muscles act in pairs. For every muscle pulling in one direction, there must be a corresponding one pulling in the opposite direction. A muscle on the left side of the body is matched by a similar one on the right side.

In Plate 3 of the horse No. 1, the scapula, forms slightly more than a right angle with No. 4, the humerus, which joins it. If these two bones move toward each other, the angle decreases. The muscles causing this action are called flexors. If the scapula and humerus straighten, the muscles causing this would be called extensors. However, the same muscle which helped flex the scapula



and humerus might extend the humerus and radius. In one action it would be called a flexor, in the other, an extensor. This dual function of some muscles, with their several attachments, creates a difficulty in naming them and describing their functions. Adduction and abduction refer to the position of the bone or bones in relation to the center line of the body. Adduction means toward the center-line; abduction means away from the center-line.

LEWIS S. BROWN



The Horse




FIG. 1

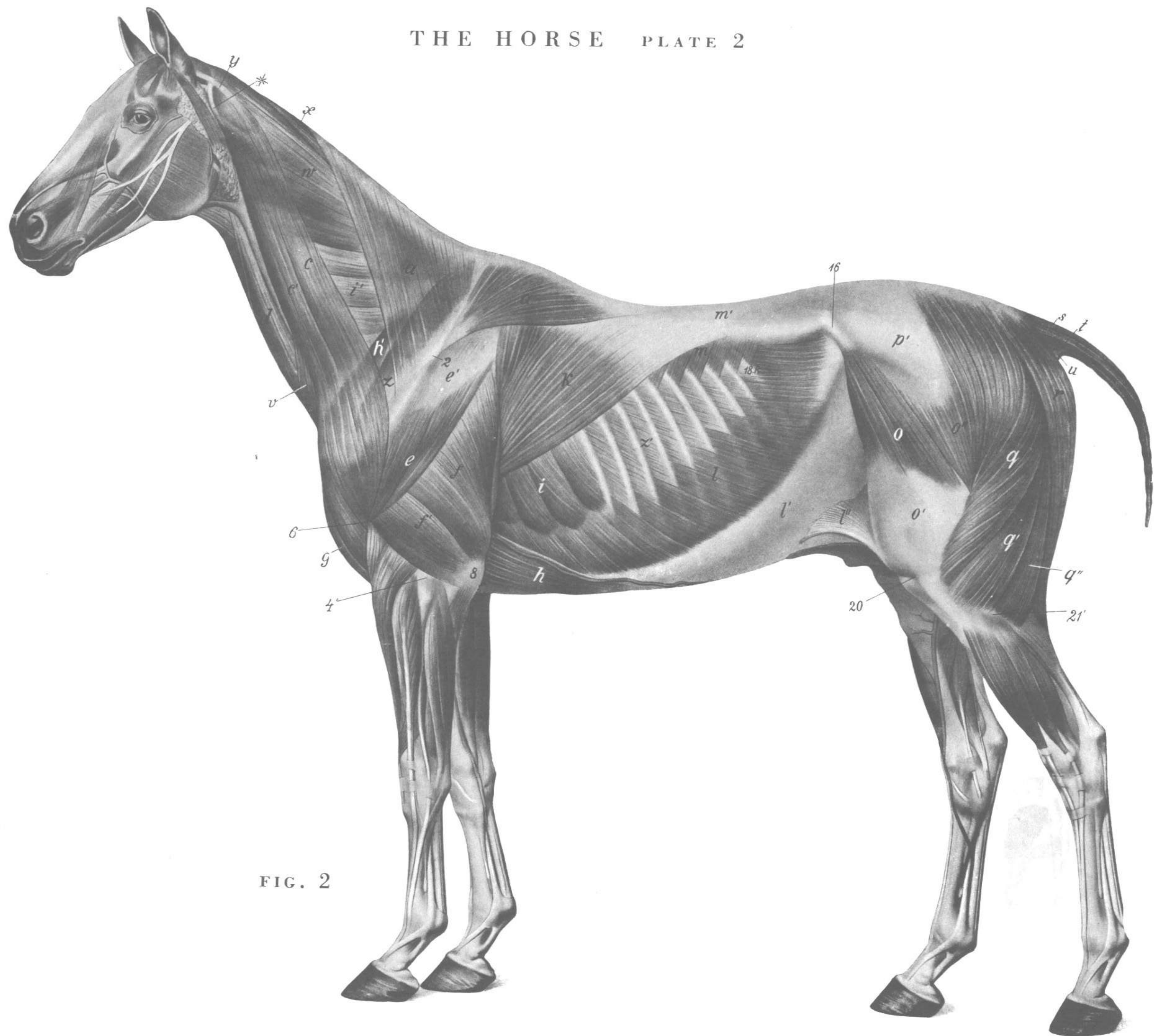


FIG. 2

THE HORSE PLATE 3

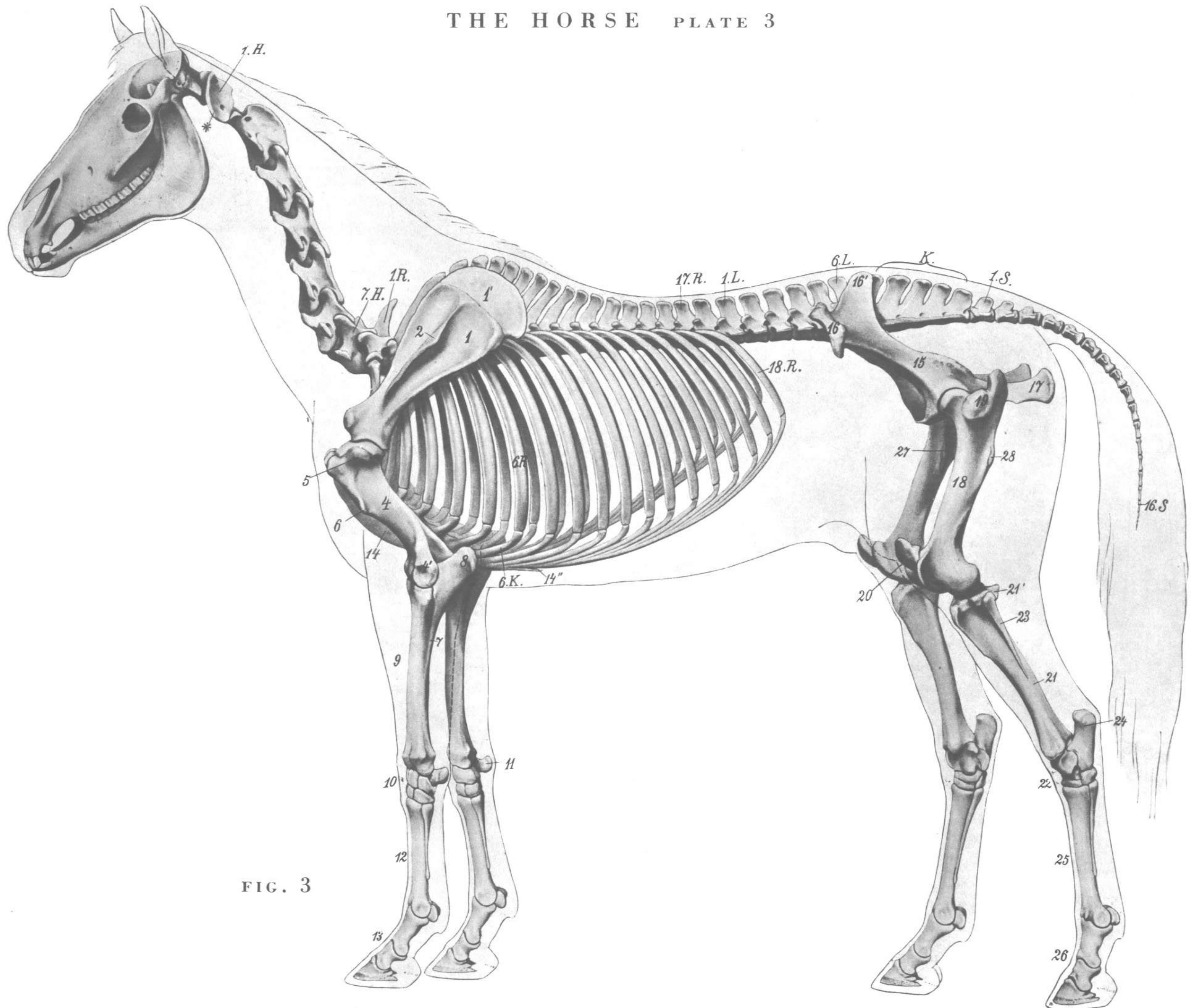


FIG. 3

[9] THE HORSE - PLATE 4

FIGURES 4 5 6

a—*M. trapezius*
 c, c'—*M. cleidomastoideus*
 d—*M. sternomandibularis*
 f, f'—*Caput longum et laterale tricipitis brachii*
 g—Clavicular part of *M. pectoralis major*
 g'—Sternal part of *M. pectoralis major*
 h'—Scapular part of *M. pectoralis minor*
 v—Cervical subcutaneous muscle, (cervical
 panniculus)
 z—*M. supraspinatus*

1R—1st rib
 1—Scapula
 1'—*Cartilago scapulae*
 2—*Spina scapulae*
 4—Humerus
 4'—External epicondyle of humerus
 5—External tuberosity of humerus
 6—Deltoid tuberosity of humerus (*Rotator*)
 9—Radius
 10—Carpus

12—Metacarpus
 13—Phalanges of anterior digit
 14—Sternum
 14'—Cariniform cartilage
 29—*M. omoyoideus*
 30—*M. sternohyoideus*
 31—*V. jugularis*
 32—Cutaneous vein

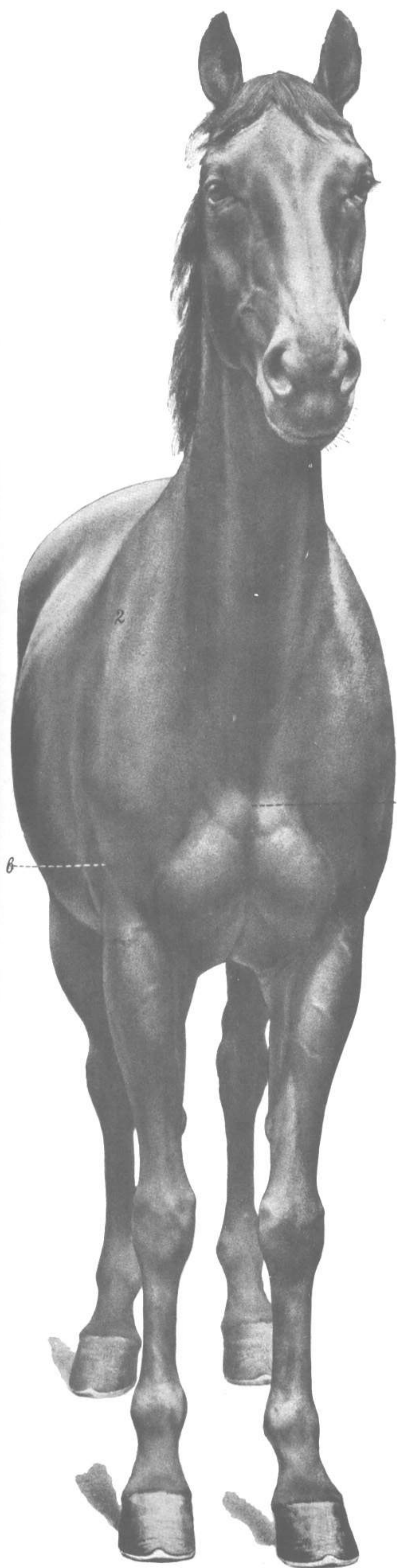


FIG. 4

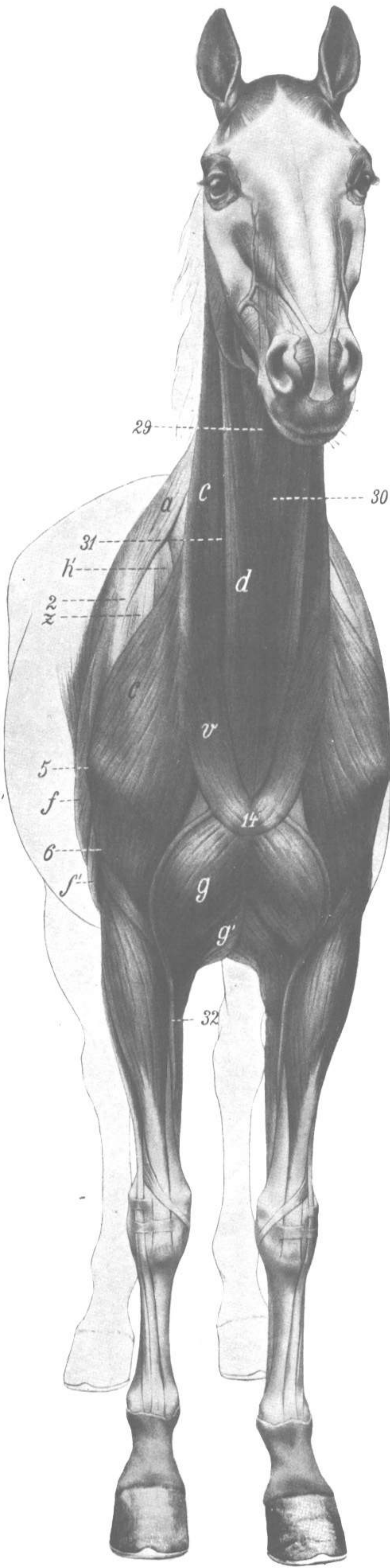


FIG. 5

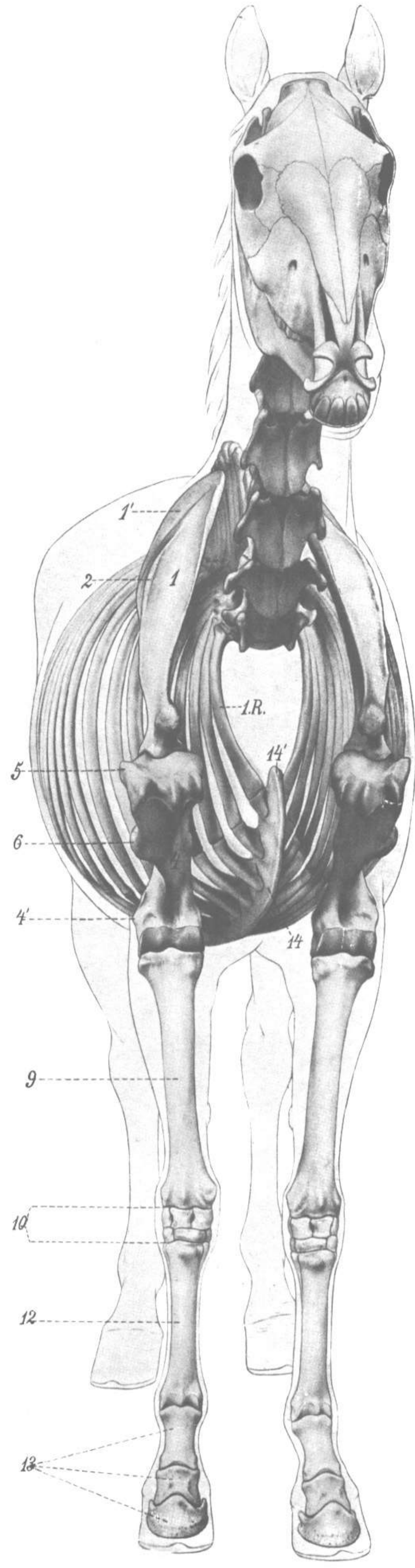


FIG. 6

FIGURES 7 8 9

a—Inner terminal tendon of *M. tibialis anterior*
 d—*M. extensor digitorum pedis lateralis*
 e—*M. flexor digitorum profundus*
 e'—Deep flexor tendon
 e''—*M. tibialis posterior*
 f—Terminal part of the united *Mm. gastrocnemii*
 f'—*Tendo achillis*
 f''—*M. soleus*
 g—Superficial flexor tendon
 h—*M. interosseus medius*
 m—*M. flexor digitorum pedis longus*
 o—*M. tensor fasciae latae*
 o''—*M. glutaeus maximus*
 p'—Fascia glutaea
 q, q', q''—*M. biceps femoris*
 r—*M. semitendinosus*

s, t—Muscles of the tail
 v—*M. semimembranosus*
 w—*M. gracilis*
 K—Sacrum
 1 S—1st caudal vertebra
 16 S—16th caudal vertebra
 15—Ossa pelvis
 16—Tuber coxae
 16'—Tuber sacrale
 17—Tuber ischii
 18—Femur
 18'—External condyle of the femur
 19—Trochanter major of the femur
 20—Patella
 21—Tibia
 21'—External condyle of the tibia
 22—Tarsus

23—Fibula
 24—Tuber calcanei
 25—Large cannon bone (3rd metatarsal bone)
 25'—External small cannon or splint bone
 (4th metatarsal bone)
 25''—Capitulum
 27—Internal trochanter of the femur
 28—External trochanter of the femur
 29—Sesamoid bones of the 1st digital joint
 30—Phalanx prima
 31—Phalanx secunda
 32—Phalanx tertia
 33—Sesamoid bone of the 3rd digital joint
 34—Anus
 35—Vulva

FIG. 7

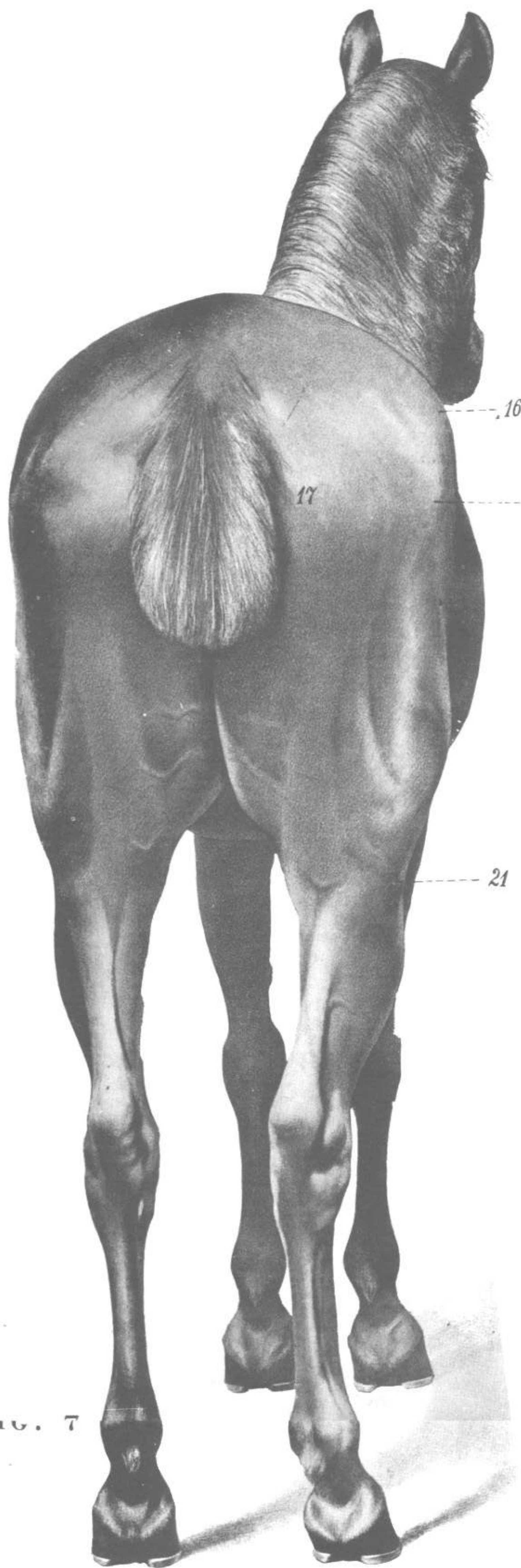


FIG. 8

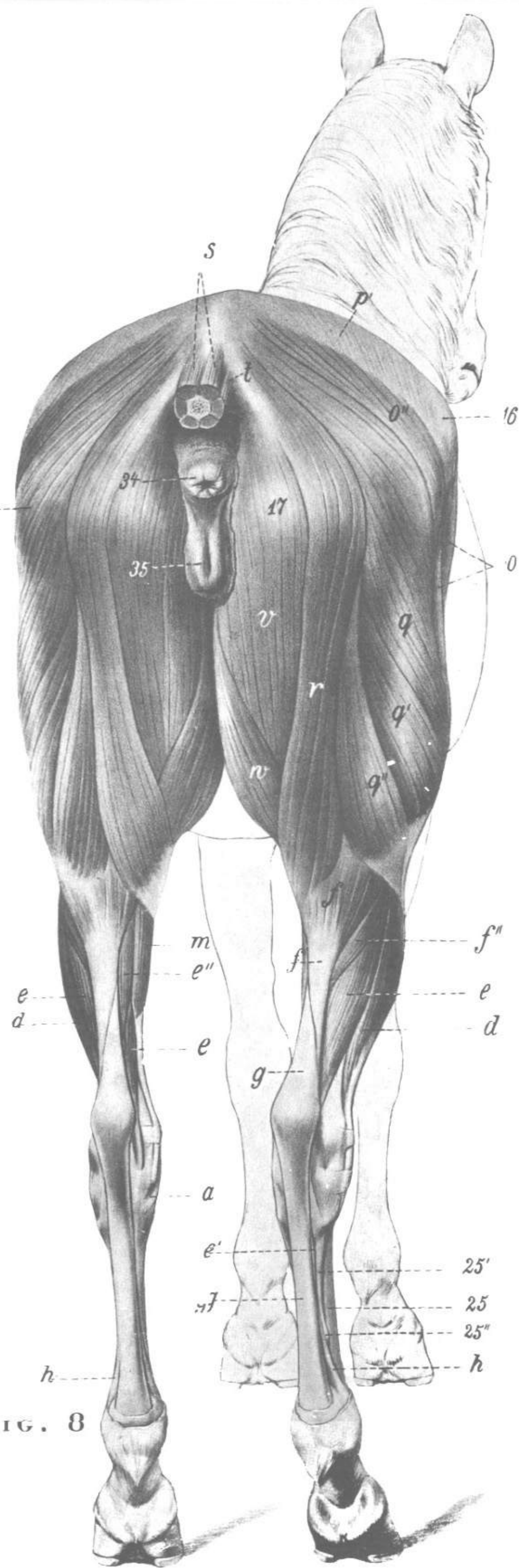
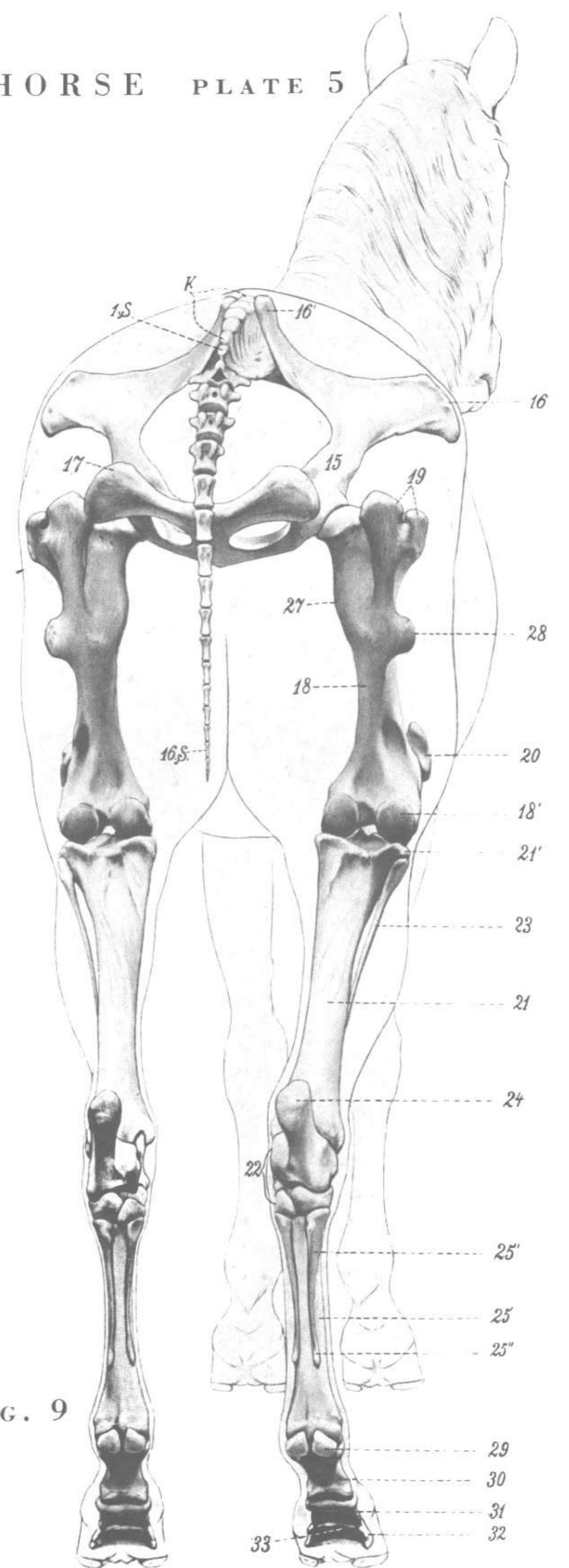


FIG. 9



THE HORSE - PLATE 6

FIGURES 10 11 12

- a, a'—*M. trapezius*
 c—*M. cleidomastoideus*
 e'—Tendon of origin of the *M. deltoideus*
 f—*Caput longum tricipitis brachii*
 i'—Cervical part of the *M. serratus anterior*
 k—*M. latissimus dorsi*
 l—Dorsal part of the *M. oblique abdominis externus*
 m—*M. serratus posterior*
 m'—Lumbo-dorsal fascia
 o''—*M. glutaeus maximus*
 p—*M. glutaeus medius*
 p'—Fascia glutaea
 q—Vertebral head of the *M. biceps femoris*
 r—Vertebral head of the *M. semitendinosus*
 s, t—Short and long levators of the tail
 w—*M. splenius*
 1 H—1st cervical vertebra (*Atlas*)
 7 H—7th cervical vertebra
 1 L—1st lumbar vertebra
 6 L—6th lumbar vertebra
 K—Sacrum
 1 R—1st thoracic (dorsal) vertebra
 6 R—6th rib
 17 R—17 thoracic (dorsal) vertebra
 18 R—18th rib
 1 S—1st caudal vertebra
 *—Ala border of the atlas
 1—Scapula
 1'—Cartilago scapulae
 2—Spina scapulae
 4—Humerus
 5—External tuberosity
 6—Deltoid tuberosity of the humerus
 8—Olecranon
 15—Pelvis
 16—Tuber coxae
 16'—Tuber sacrale
 17—Tuber ischii
 18—Os femoris
 19—Trochanter major of the femur
 24—Tuber calcanei
 27—Os occipitale
 27'—External occipital tuberosity
 28—Os parietale
 30—Transverse processes of the lumbar vertebrae
 36—*M. longissimus dorsi*



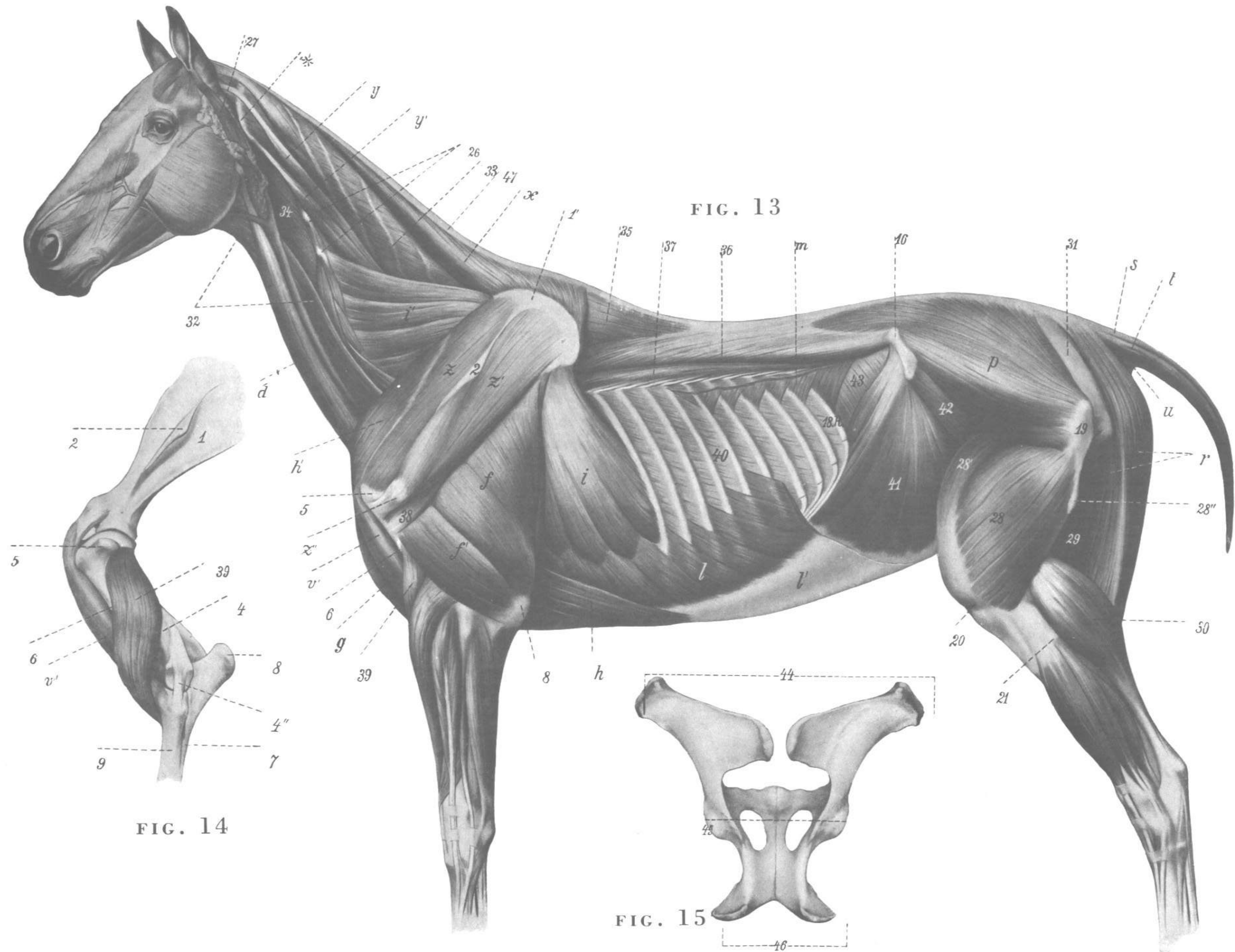
THE HORSE - PLATE 7

FIGURES 13 14 15

d—*M. sternomandibularis*
 f, f'—*M. triceps brachii*
 g—Anterior portion of the *M. pectoralis major*
 h—Posterior portions of the *M. pectoralis minor*
 h'—Scapular portion of the *M. pectoralis minor*
 i—Thoracic portion of the *M. serratus anterior*
 i'—Cervical portion of the *M. serratus magnus*
 l—Part of the *M. obliquus abdominis externus*
 l'—Tendon of the *M. obliquus abdominis externus*
 m—*M. serratus posterior*
 p—*M. glutaeus medius*
 r—*M. semitendinosus*
 s, t—Short and long levators of the tail
 u—Abductor muscle of the tail
 v'—*M. biceps brachii*
 x—*M. rhomboideus*
 y—*M. longissimus capitis*
 y'—*M. longissimus atlantis*
 z—*M. supraspinatus*
 z', z''—*M. infraspinatus*
 18 R —18th rib

*—Border of the atlas
 1—Scapula
 1'—Cartilago scapulae
 2—Spina scapulae
 4—Humerus
 4''—External lateral ligament of the elbow joint
 5—External tuberosity of the humerus
 6—Deltoid tuberosity of the humerus
 7—Ulna
 8—Olecranon
 9—Radius
 16—Tuber coxae
 19—Trochanter major of the femur
 20—Depression over the lower part of the patella
 21'—External condyle of the tibia
 26—Articular processes of the cervical vertebrae
 27—Depressor muscle of the auricle
 28, 28'—*M. quadriceps femoris*
 28''—Trochanter tertius femoris
 29—A part of the *M. semimembranosus*
 30—*Mm. gastrocnemii*
 31—Posterior part of the sacro-sciatic ligament

32—*M. omohyoideus*
 33—*M. complexus*
 34—*M. longus capitis*
 35—*M. spinalis et semispinalis dorsi et cervicis*
 36—*M. longissimus dorsi*
 37—*M. iliocostalis*
 38—*M. teres minor*
 39—*M. brachialis internus*
 40—*M. intercostalis*
 41—*M. obliquus abdominis internus*
 42—*M. iliacus*
 43—*M. transversus abdominis*
 44—Dotted line indicating the distance between the two external angles of the ilium, upper view of the pelvis of a stallion
 45—Dotted line indicating the distances between the two hip joints, upper view of the pelvis of a stallion
 46—Dotted line indicating the distance between the tuberosities of the ischia, upper view of the pelvis of a stallion
 47—Cervical ligament cord



THE HORSE - PLATE 8

FIGURES 16 17 18 19

c—Lower marginal part of the *M. mastoideo-humeralis*

d—*M. sternomandibularis s. sternocephalicus*

g—Anterior portion of the *M. pectoralis major*

g'—Posterior portion of the *M. pectoralis major*

h—Posterior part of the *M. pectoralis minor*

i—Teeth of origin of the *M. serratus magnus*

k—Marginal part of the *M. latissimus dorsi*

l—*M. obliquus abdominis externus*

l'—Aponeurosis of the *M. obliquus abdominis externus*

l''—The fold of the groin caused by the *M. panniculus carnosus*

r—End of the *M. semitendinosus*

s'—Flexor muscles of the tail

t—*M. pectineus*

u—End of the *M. iliopsoas*

v—End of the *M. semimembranosus*

v'—Cervical subcutaneous muscle (cervical panniculus)

w—*M. gracilis*

x—*M. sartorius*

y, y'—*M. quadriceps femoris*

z, z'—*Mm. adductores femoris*

1 H—1st cervical vertebra

7 H—7th cervical vertebra

1 R—1st thoracic (dorsal) vertebra

*—Edge of the atlas

1—Scapula

1'—Cartilago scapulae

2—Juncular part of the ligamentum nuchae

3—Wide section of the ligamentum nuchae

4—Lamellar part of the ligamentum nuchae

8—Olecranon

9—Zygomatic arch

10—Supraorbital depression (temporal fossa)

12—Orbital arch

14—Lower edge of the sternum

14'—Manubrium sternali

19—Orbital cavity

20—Patella

27—Zygomatic or facial crest

29—End of the *M. omohyoideus*

30—End of the *M. sternohyoideus*

51—Upper eyelid with its eyelashes

51'—Lower eyelid

52—Cartilago nictitans

53—Caruncula lacrimalis

54—Lacus lacrimalis

55, 55'—Eyeball

56—Pupil

56'—Corpora nigra

57—Pigmented marginal band along the junction of the sclera with the cornea

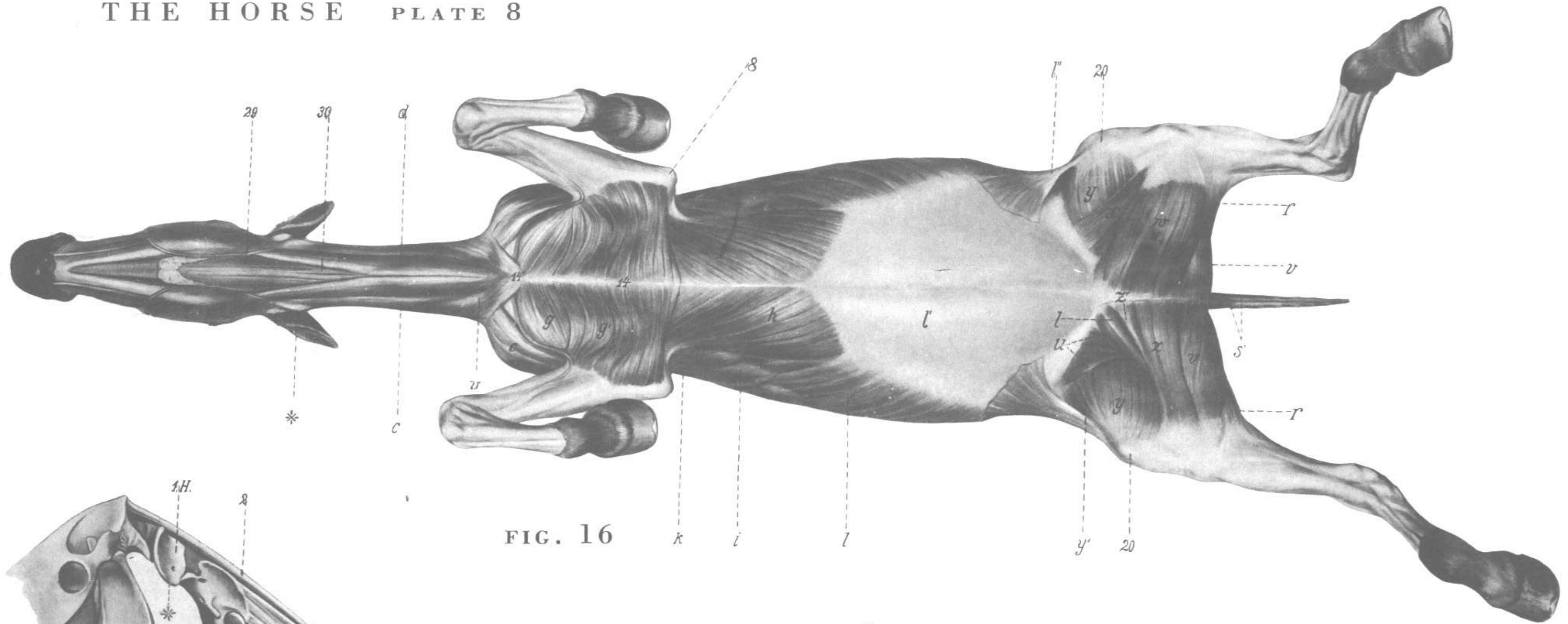


FIG. 16

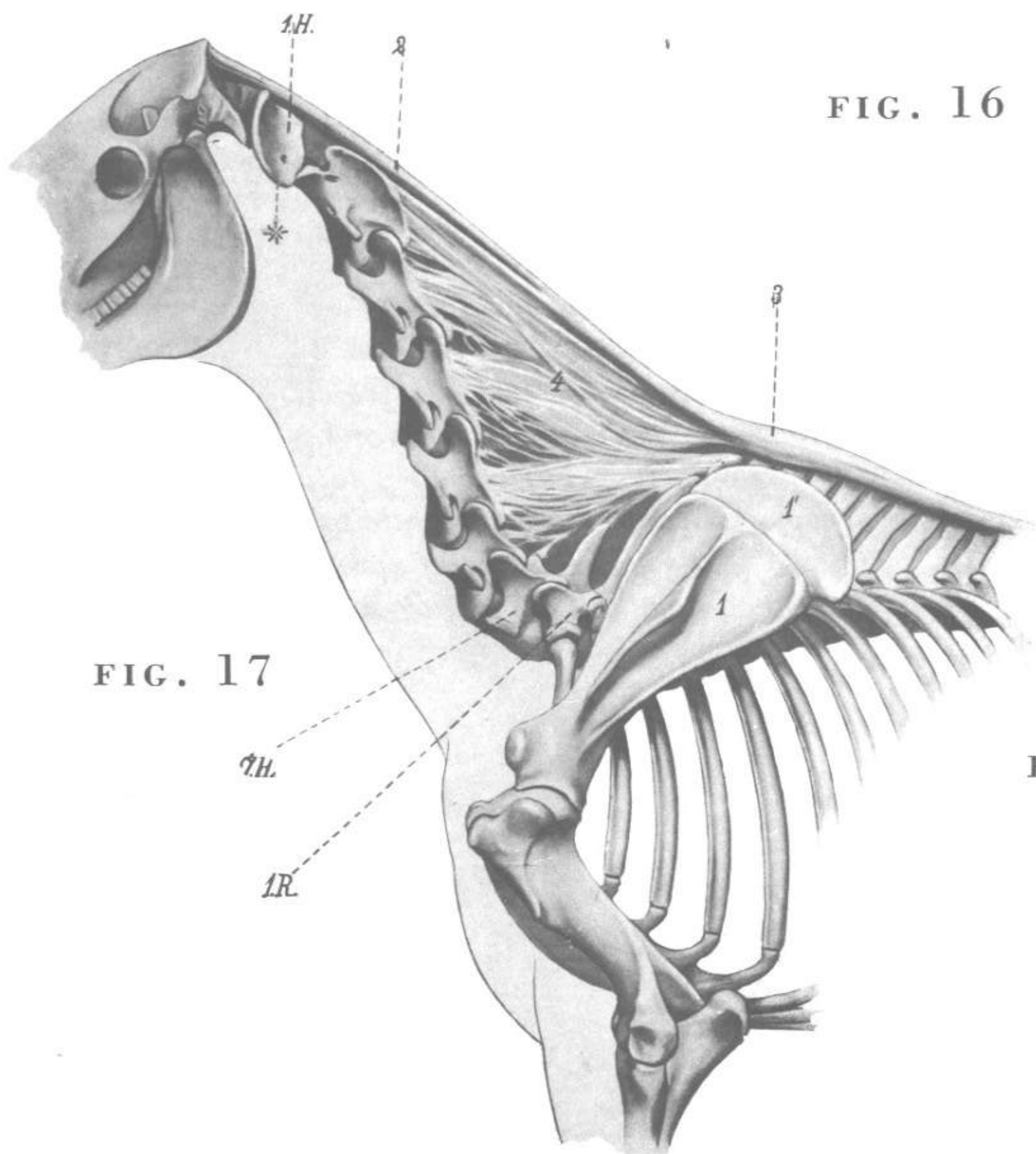


FIG. 17

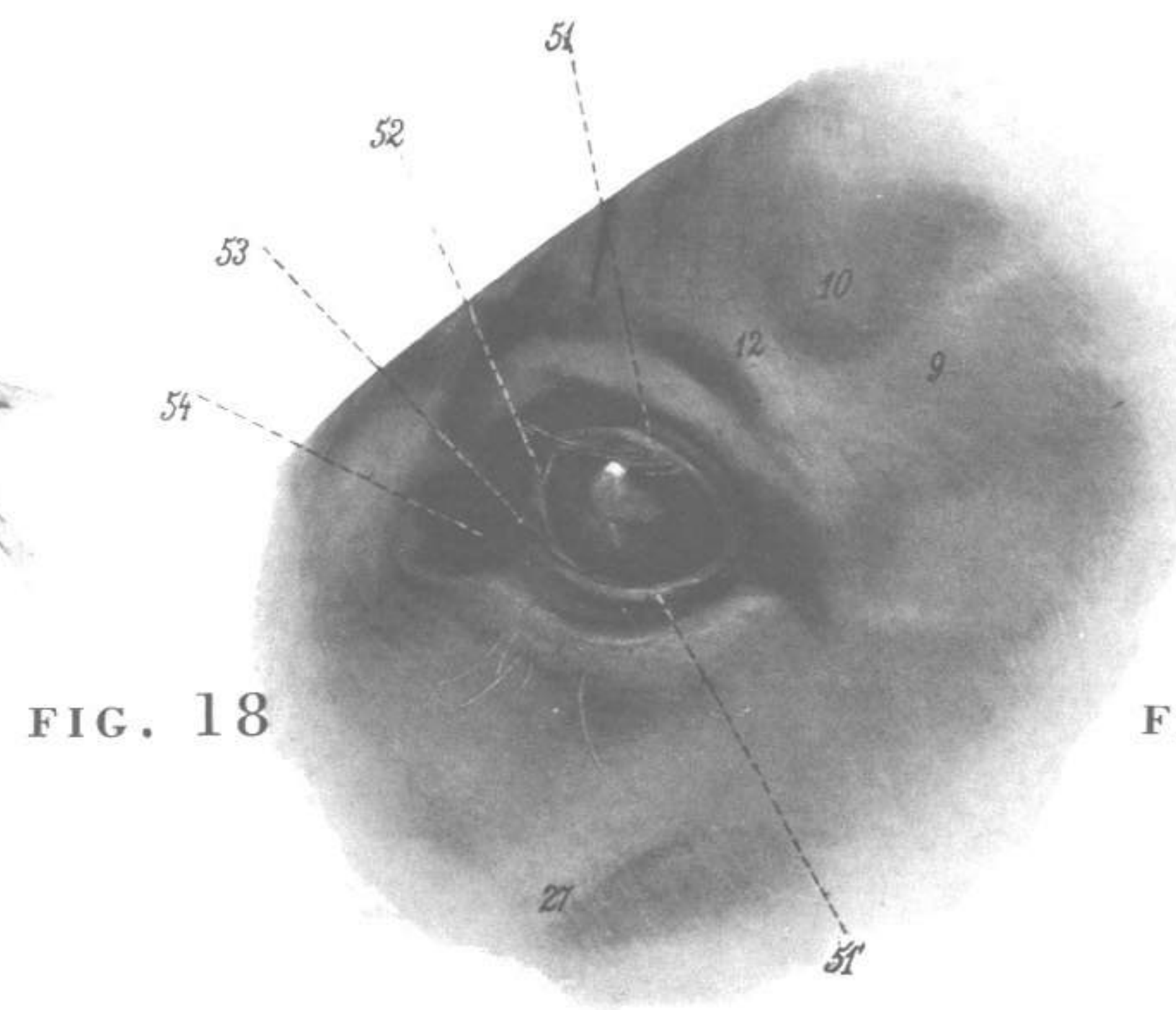


FIG. 18

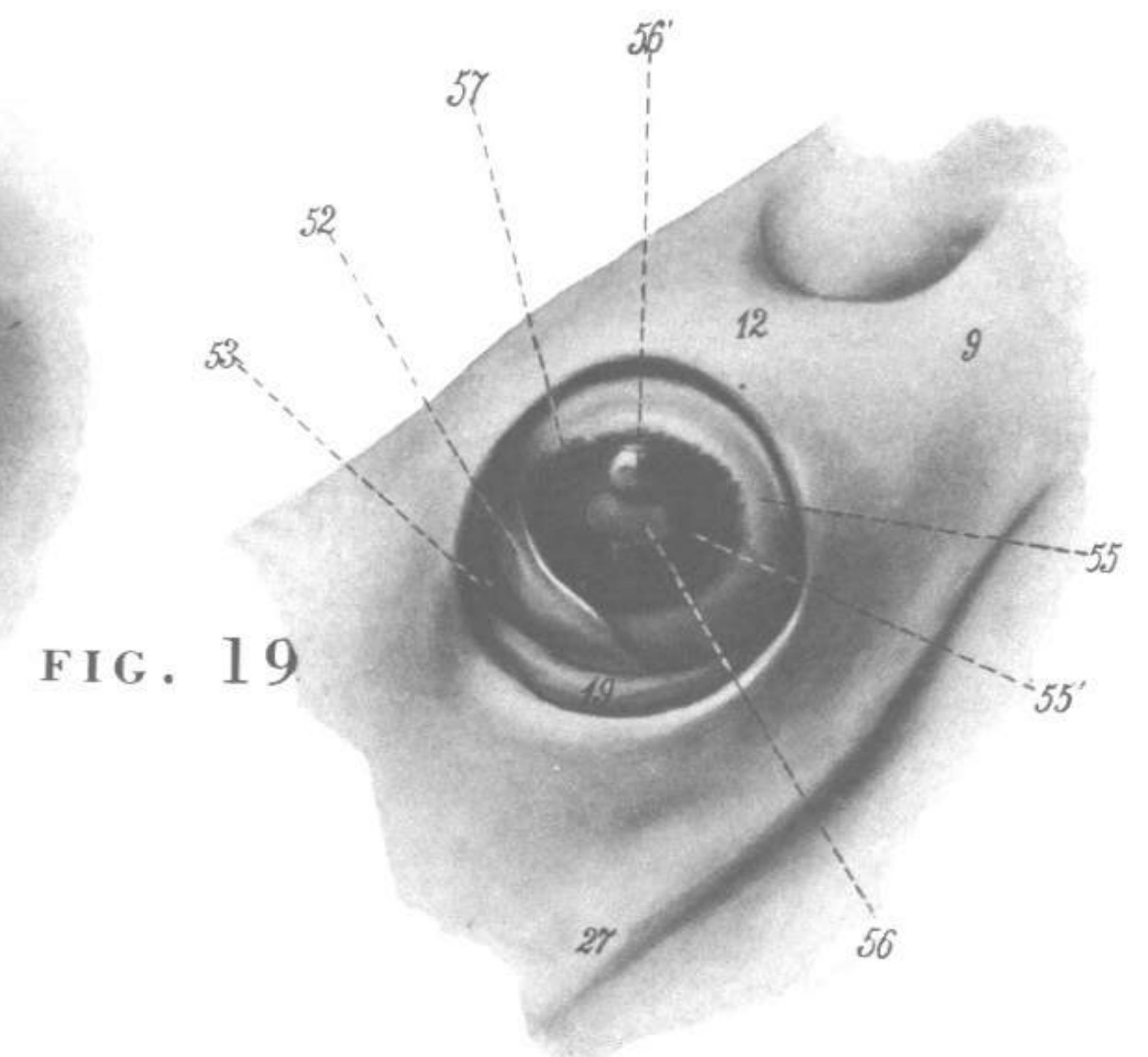


FIG. 19

THE HORSE - PLATES 9 10

FIGURES 20 21 22 23 24 25 26 27 28 29

a—*M. levator labii sup. propius*
 a'—Uniting tendon
 b—*M. levator labii sup. alaeque nasi*
 c—Origin of the *M. sterno-cleidomastoideus*
 d—End of the *M. sterno-mandibularis*
 d'—Tendon at the end of *M. sterno-mandibularis*
 e—Terminal parts of the combined *Mm. omo-hyoidei et sterno-hyoidei*
 f—*M. caninus s. pyramidalis nasi*
 g—*M. zygomaticus major*
 h—*M. buccinator*
 i—*M. quadratus labii inferioris*
 k—*M. orbicularis oris*
 l—*M. dilatator nasi*
 m—*M. masseter*
 n—Depressor of the auricle
 o—External adductor of the auricle
 o'—Inferior adductor of the auricle
 o''—Superior adductor of the auricle
 p, p'—*M. scutularis*
 q—Abductor of the auricle
 r—Levator of the auricle
 s—*M. obliquus capitis superior*
 t—*M. splenius*
 u—*M. corrugator supercilii*
 v—*M. biventer maxillae; M. digastricus*
 x—*M. transversus nasi*
 y—Tendon of the *M. longissimus capitis et atlantis*

*—Ala border of atlas
 1—Auricula or cartilage of the ear
 2—External or posterior edge of auricle
 3—Internal or anterior edge of auricle
 4—Incisura intertragica
 5—Base of auricle
 6—Styloid process of auricle
 7—Cartilago annularis
 8—Scutellum
 9—Arcus zygomaticus
 10—Temporal fossa
 11—Proc. coronoideus of the lower jawbone
 12—Orbital arch
 13—Os occipitale
 13'—Crest of os occipitale
 13''—Jugular process of os occipitale
 13'''—Condyle of the os occipitale
 14—Os parietale
 14'—Crest of the os parietale
 15—Os frontale
 15'—Frontal crests
 16—Os temporale
 17—Meatus acusticus externus
 18—Temporo-maxillary joint
 19—Orbita
 20—Os jugale
 21—Os lacrimale
 22—Os nasale
 23—Os intermaxillare s. incisivum

24—Upper incisor teeth
 25—Upper canine tooth
 26—Os maxillare sup.
 27—Zygomatic or facial crest
 28'—Body of the lower jawbone
 29—Lower canine tooth, exposed from the alveolus
 29'—Incisor tooth, exposed from the alveolus
 30—Branch of the lower jaw
 30'—Angle of the lower jaw
 31—Condyle process of the lower jaw
 32—1st cervical vertebra (Atlas)
 33—2nd cervical vertebra
 34—Lateral cartilage of the nose
 35, 35'—The X shaped or alar cartilage of the nose
 37—*V. maxillaris externa*
 38—*V. jugularis*
 39—*V. facialis*
 40—Ductus parotideus
 41—Transverse facial vein
 42—Masseteric vein
 43—Facial nerve
 44—Glandula parotis
 45—Chin
 46—Enamel ridge of the incisor tooth as seen from the masticatory surface
 47—Mark or cup characteristic of the incisor tooth




FIG. 20

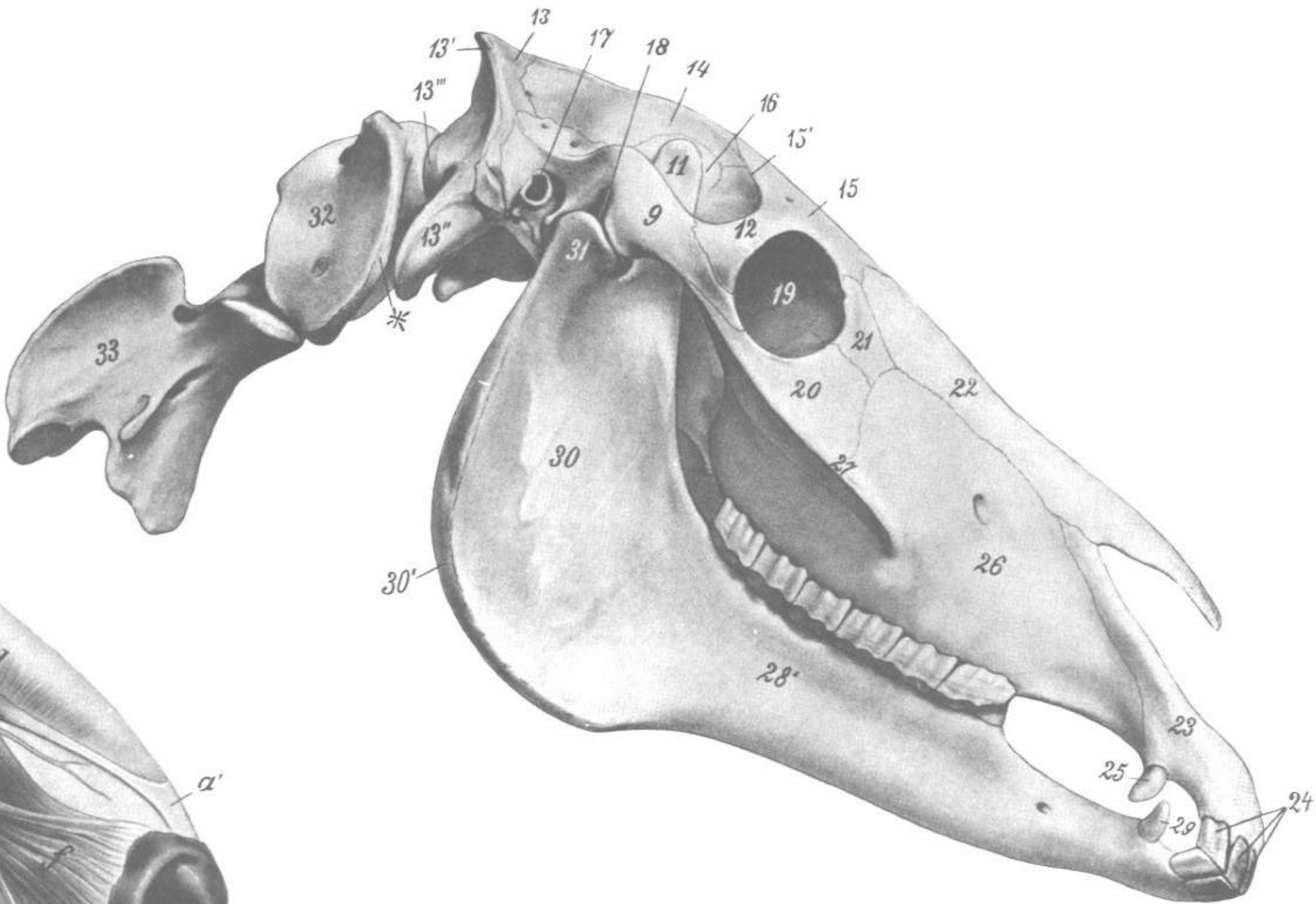


FIG. 21

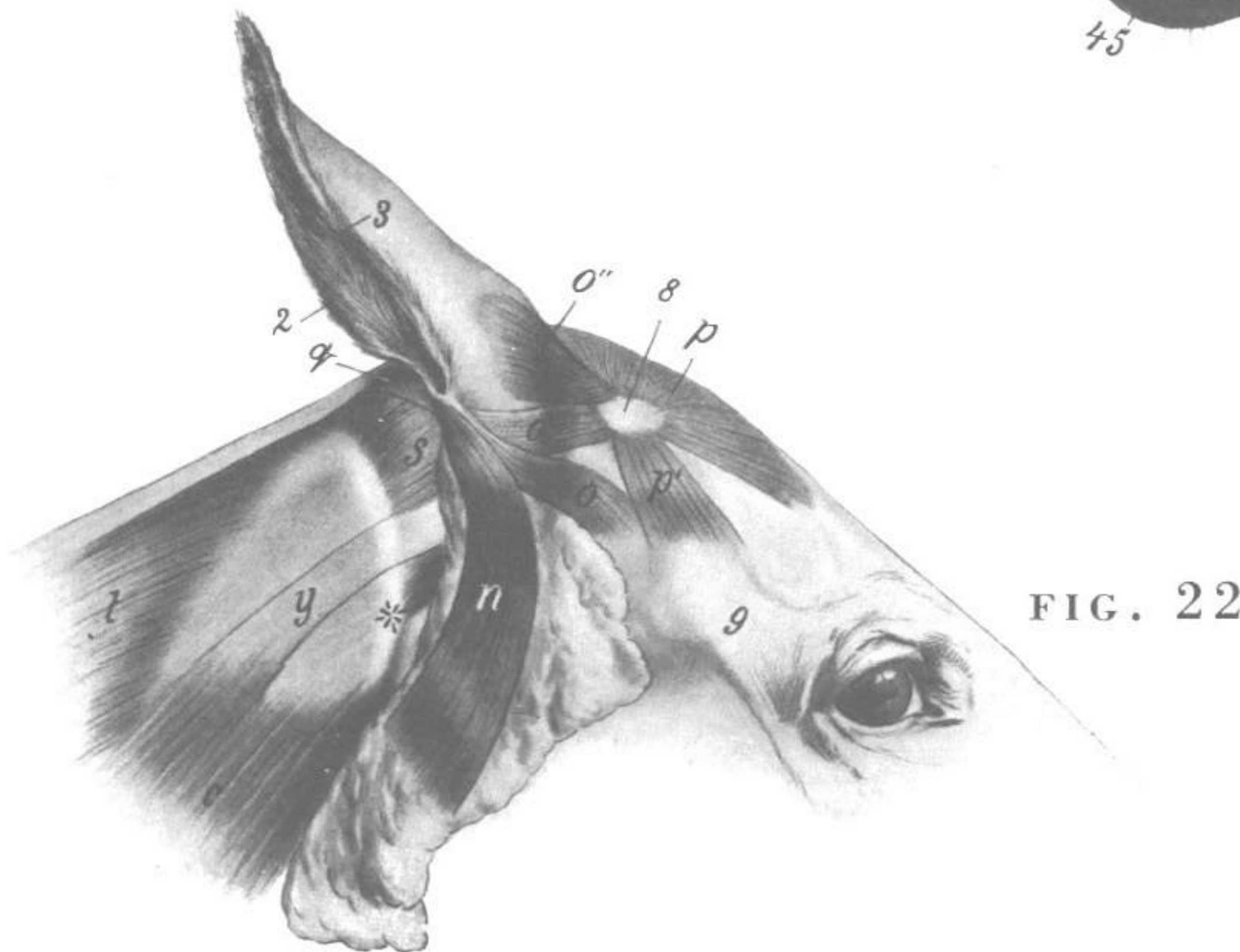


FIG. 22

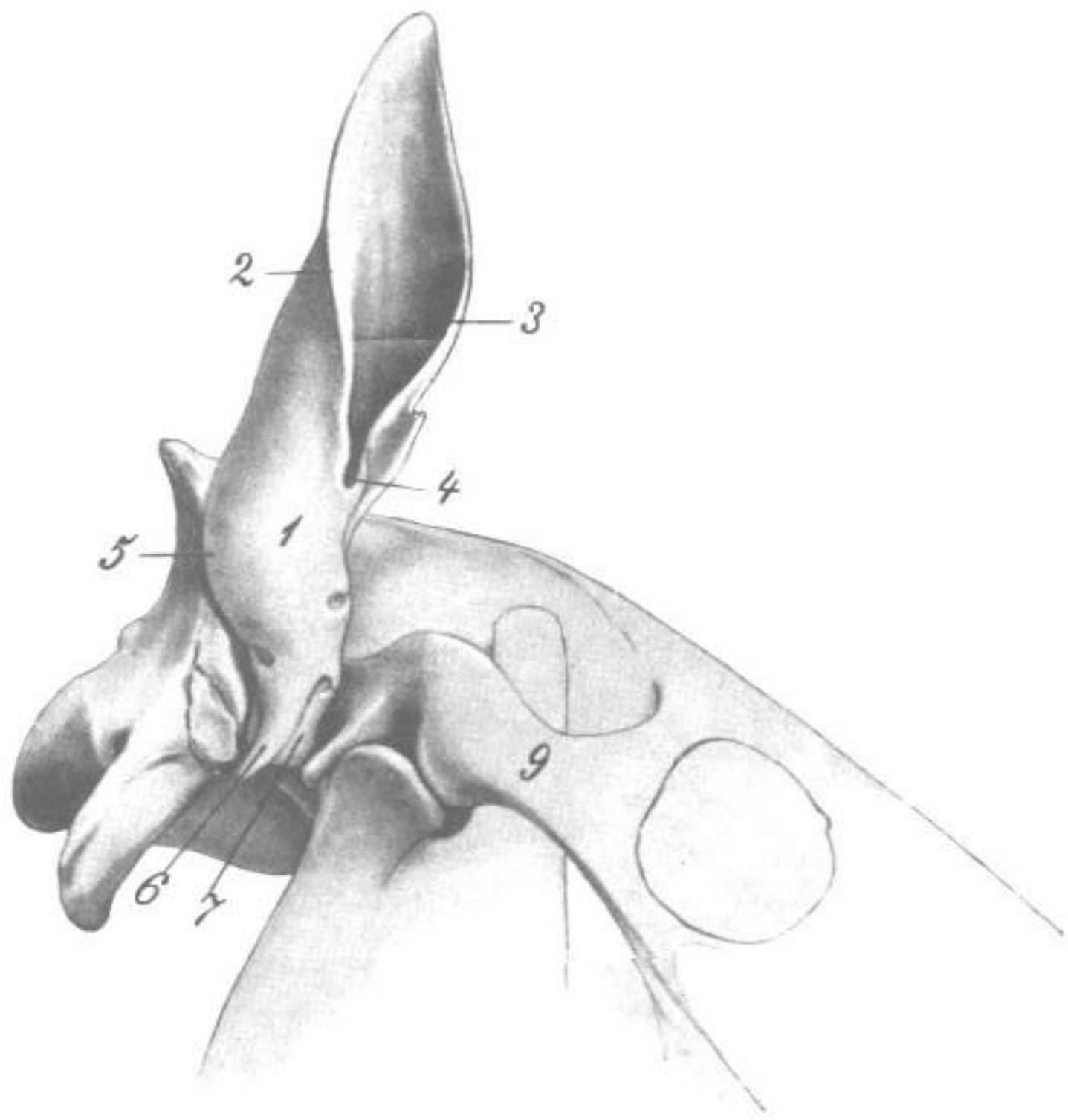


FIG. 23

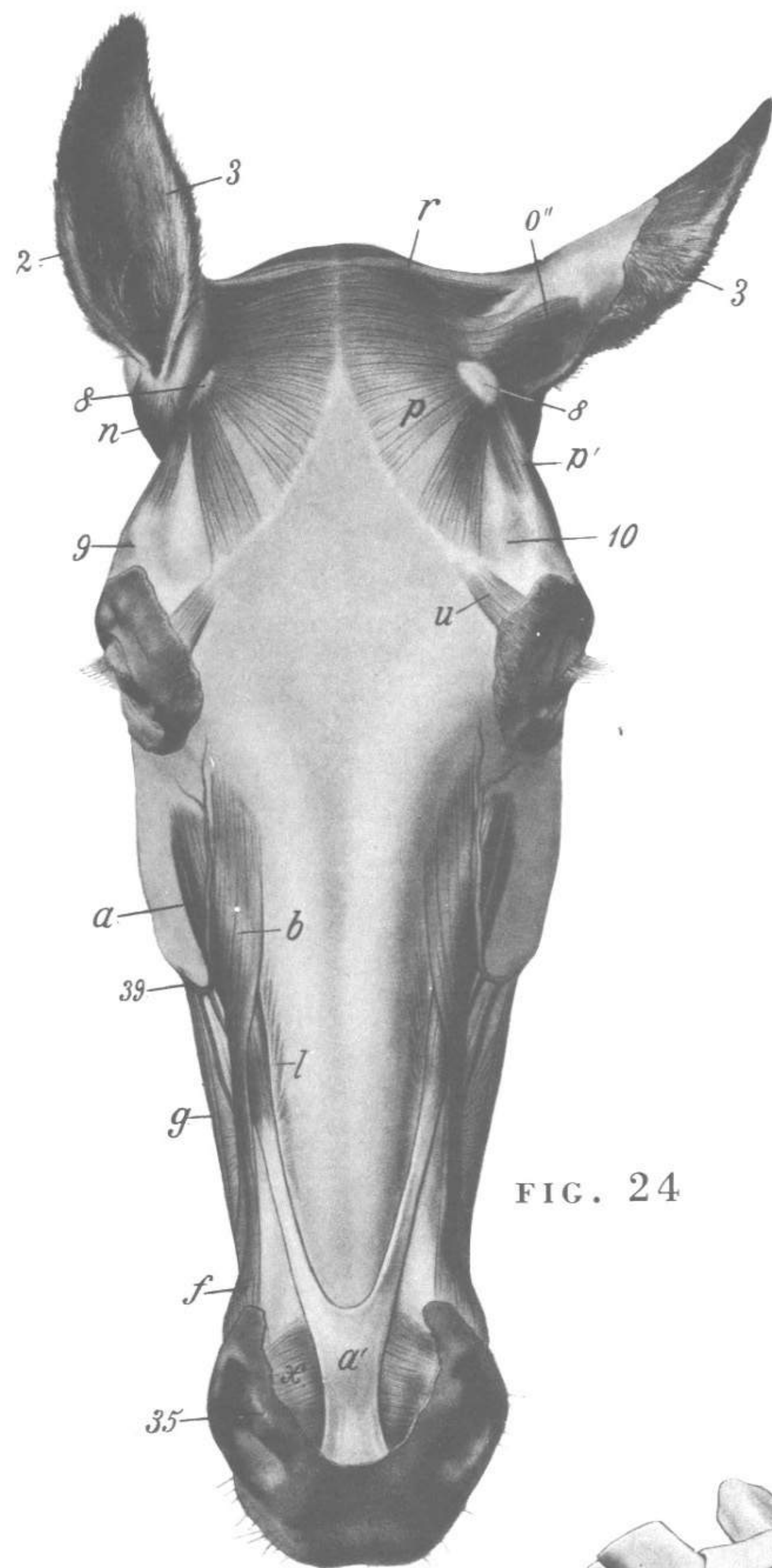


FIG. 24

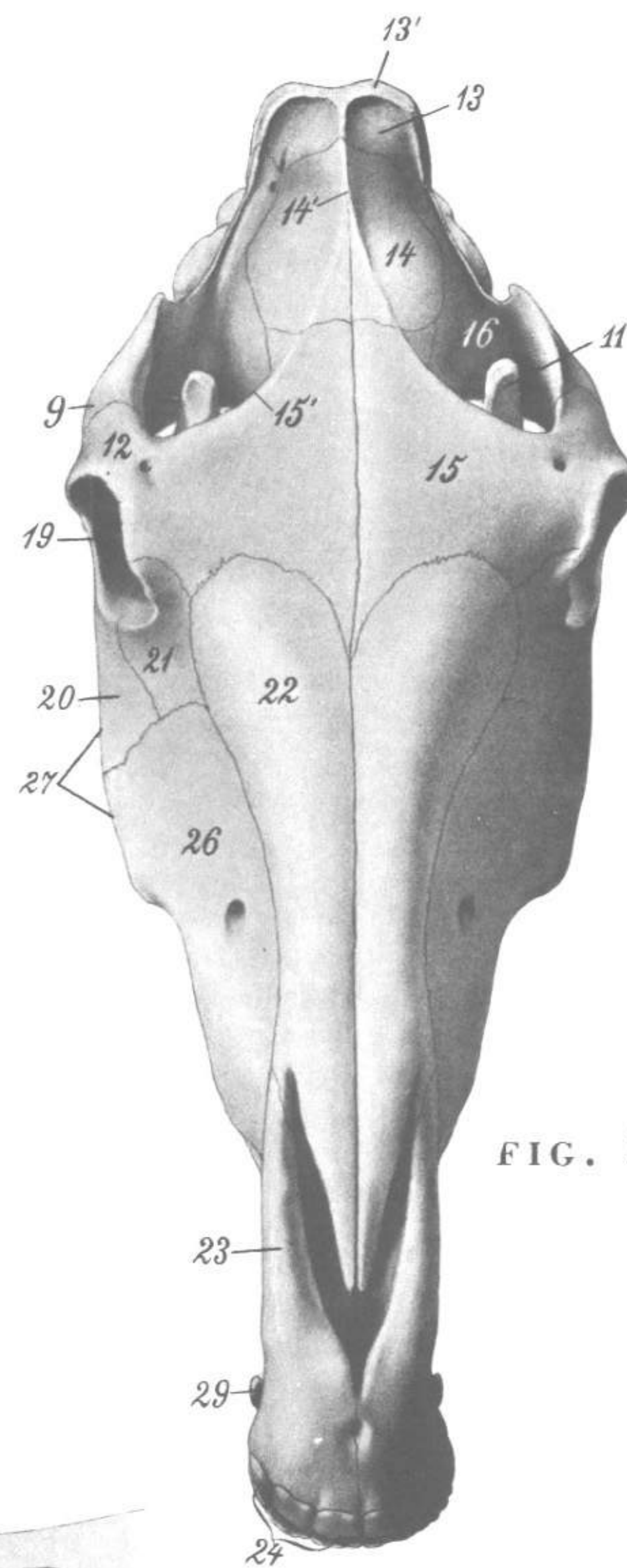


FIG. 25

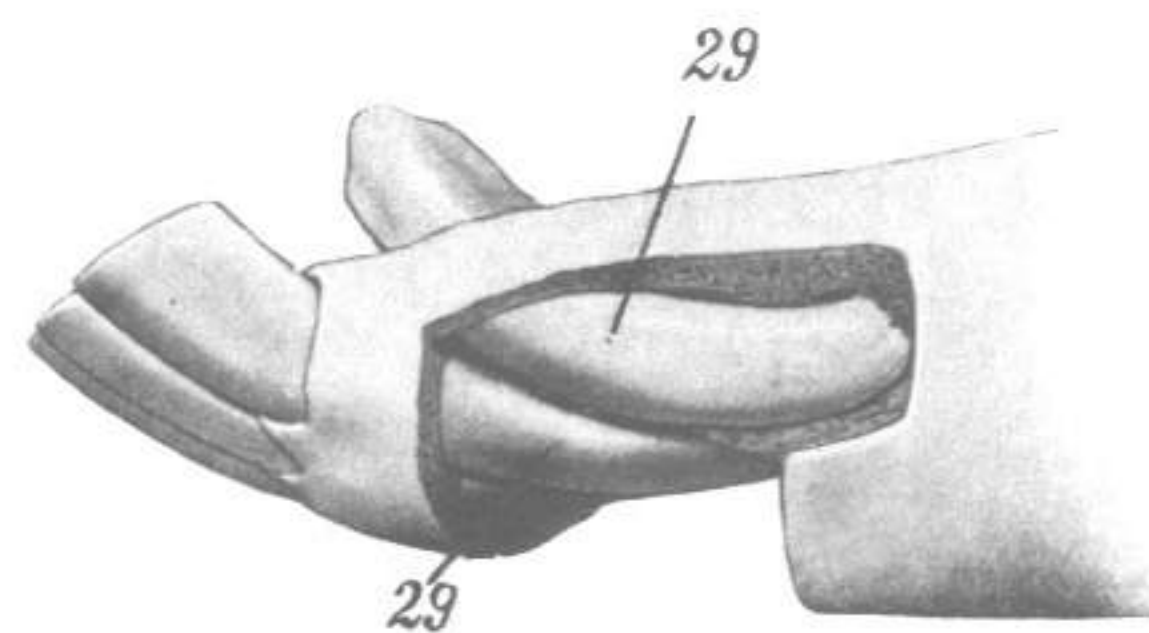


FIG. 28

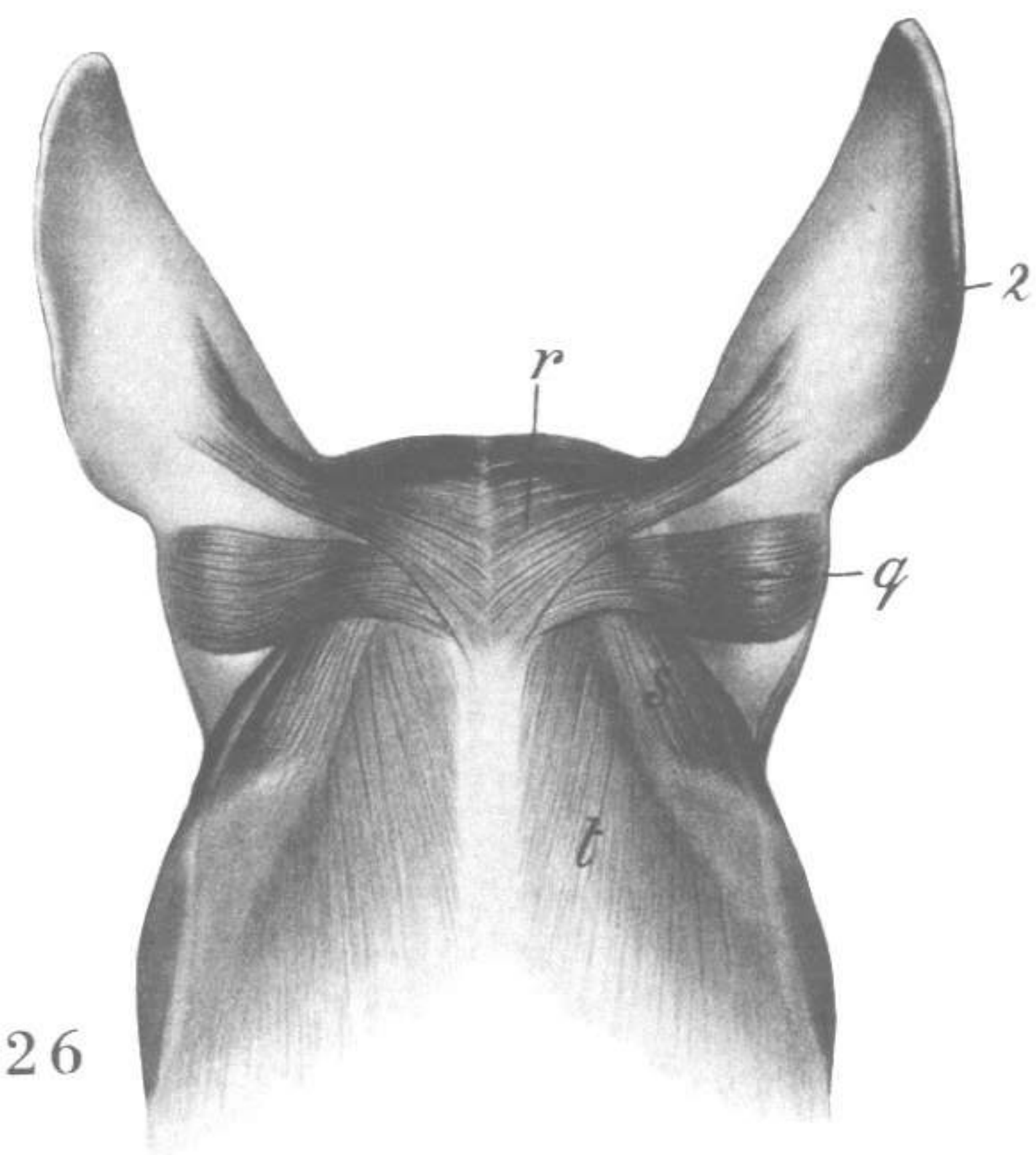


FIG. 26

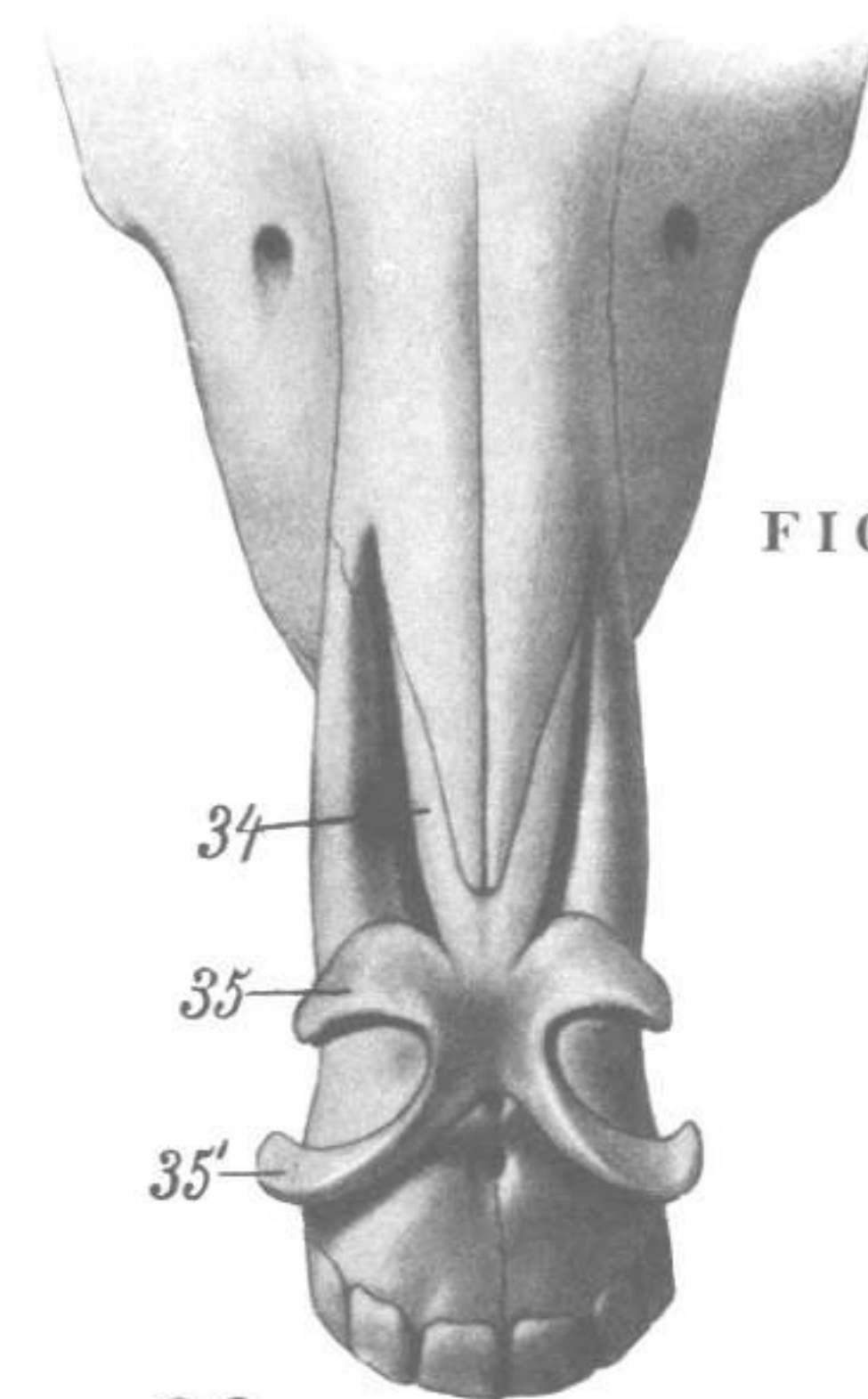


FIG. 27

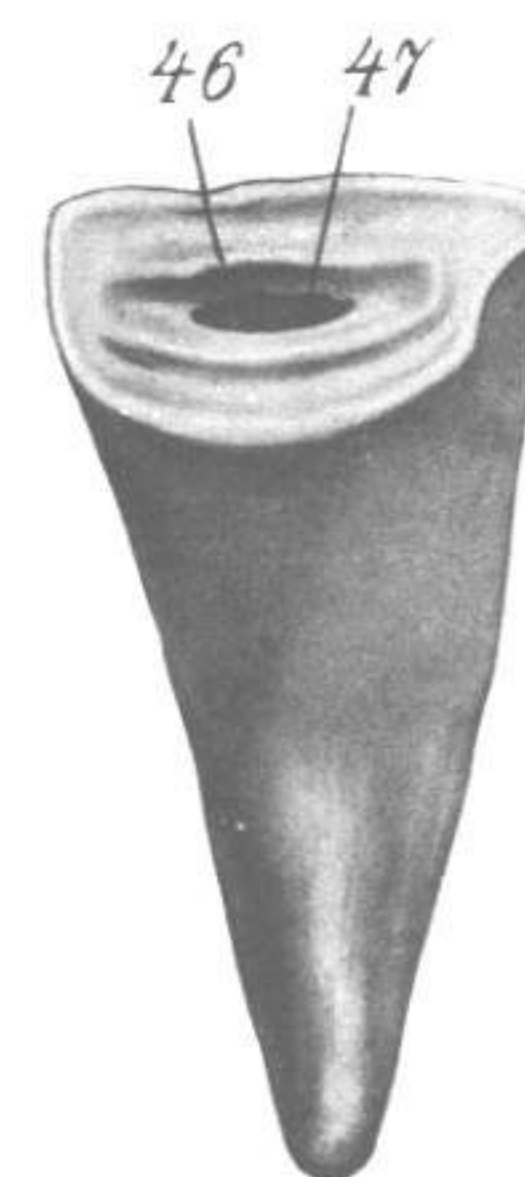

FIG. 29

THE HORSE - PLATES 11 12

FIGURES 30 31 32 33 34 35 36 37 38 39 40 41

a—*M. extensor carpi radialis*
 c—*M. extensor digitorum communis*
 d, d'—*M. extensor digiti minimi*
 e, e'—*M. extensor carpi ulnaris*
 f—*M. abductor pollicis longus*
 f'—*Ulnar head of the deep flexor of the digit*
 g—*End of the M. brachialis internus*
 g'—*End of the M. pectoralis major*
 g''—*Same muscle of the left side*
 h—*M. interosseus medius*
 h'—*Tendinous band to the tendon of the digito-
rum communis*
 i—*Flexor tendons*

i'—*Check ligament*
 k—*M. flexor carpi radialis*
 l—*M. extensor carpi ulnaris*
 n—*Lateral cartilage*
 o—*M. flexor digitorum profundus*
 p—*Great subcutaneous vein*
 q—*Annular ligament*
 4—*Humerus*
 4'—*External or extensor condyle of the humerus*
 7—*Ulna*
 8—*Olecranon*
 9—*Radius*
 9'—*External tuberosity of the radius*

10—*Bones of the carpus*
 11—*Os pisiforme*
 12—*Large metacarpal bone*
 12'—*Tuberosity of large metacarpal bone*
 14—*External small metacarpal bone*
 14'—*Internal small metacarpal bone*
 15—*Sesamoid bones of the 1st digital joint*
 16—*Phalanx prima*
 17—*Phalanx secunda*
 18—*Phalanx tertia*
 19—*Sesamoid bones of the 3rd digital joint*

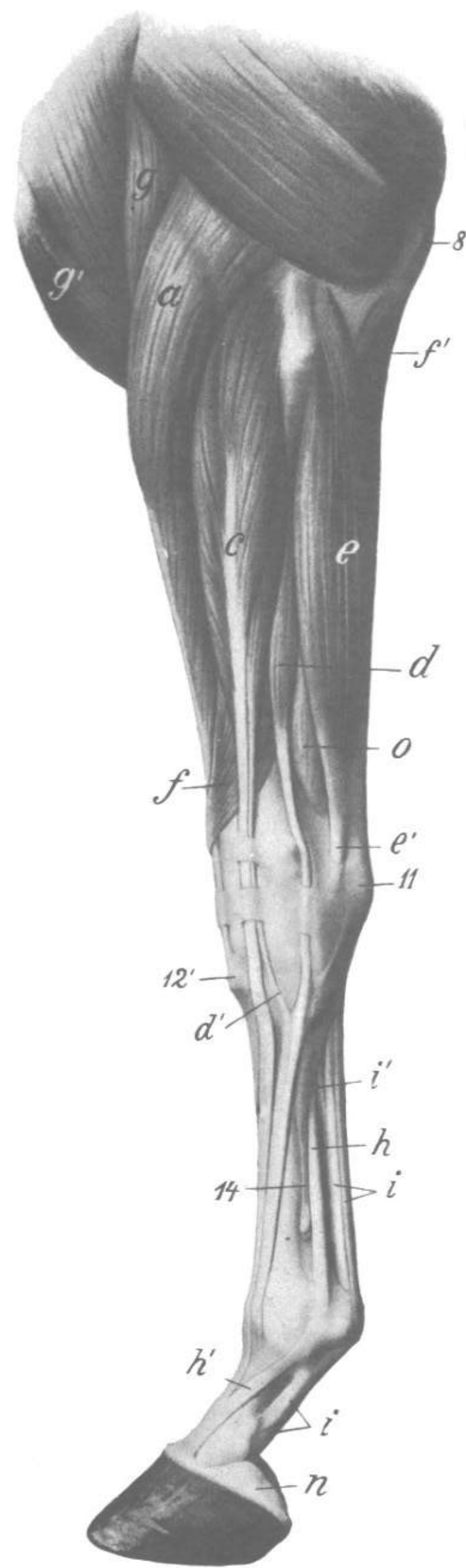


FIG. 30

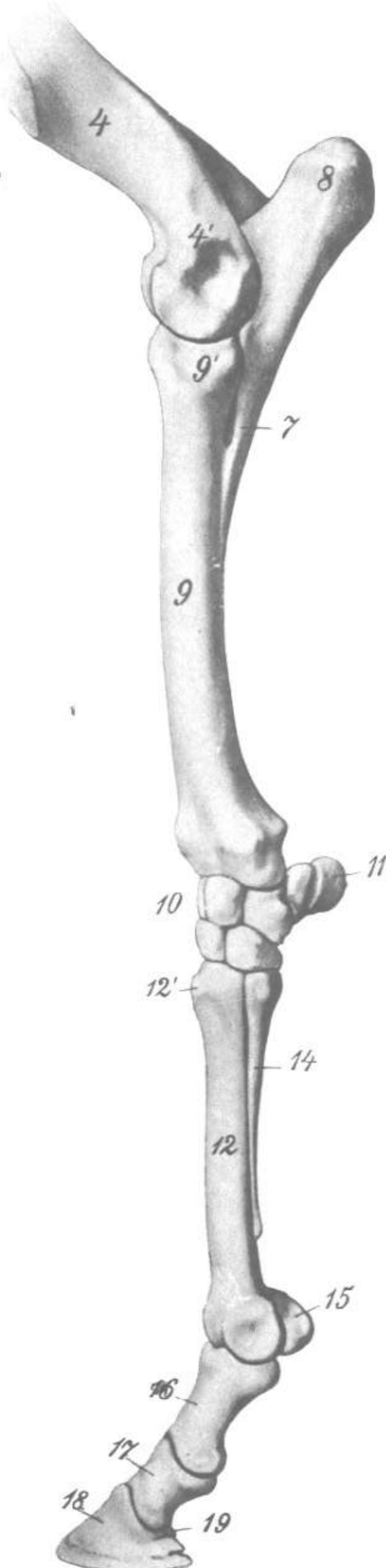


FIG. 31

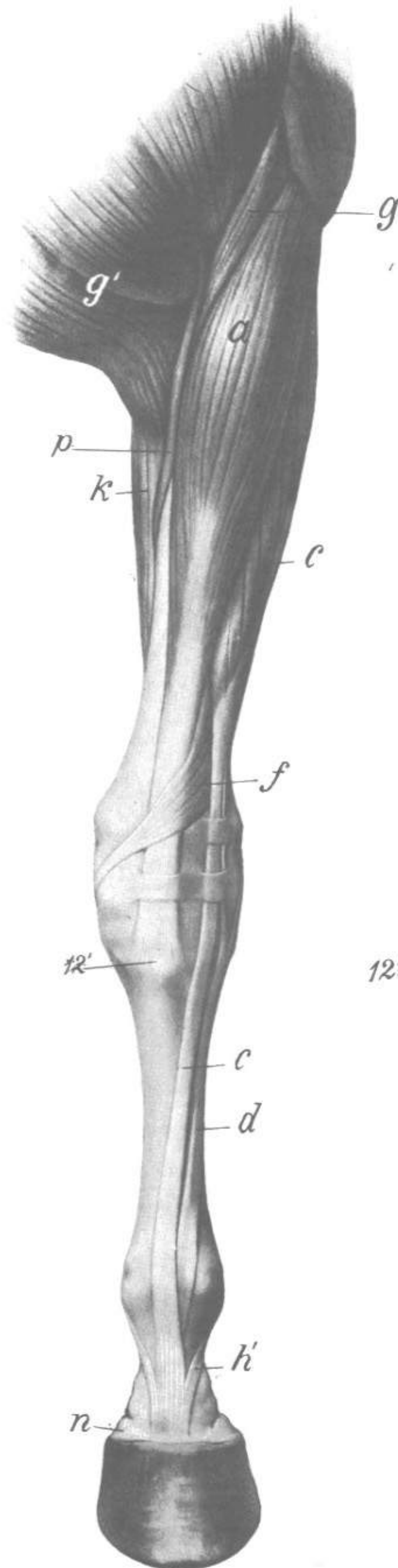


FIG. 32

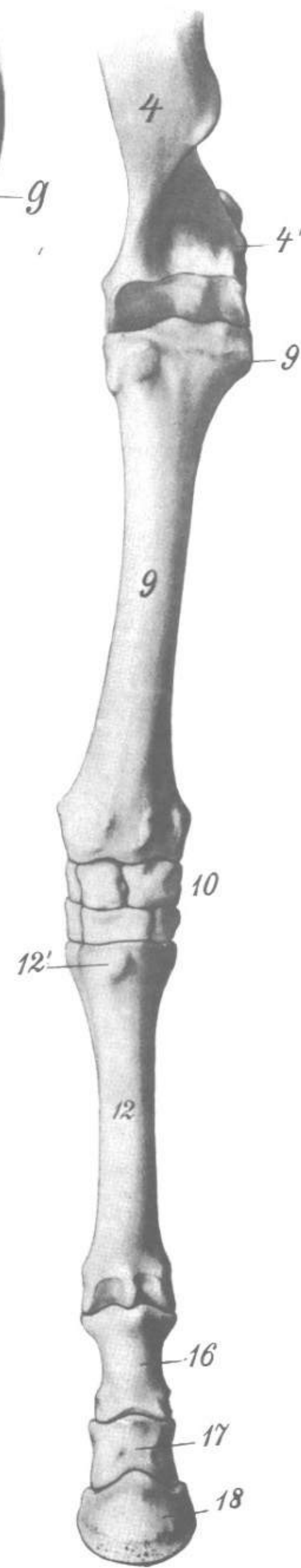


FIG. 33

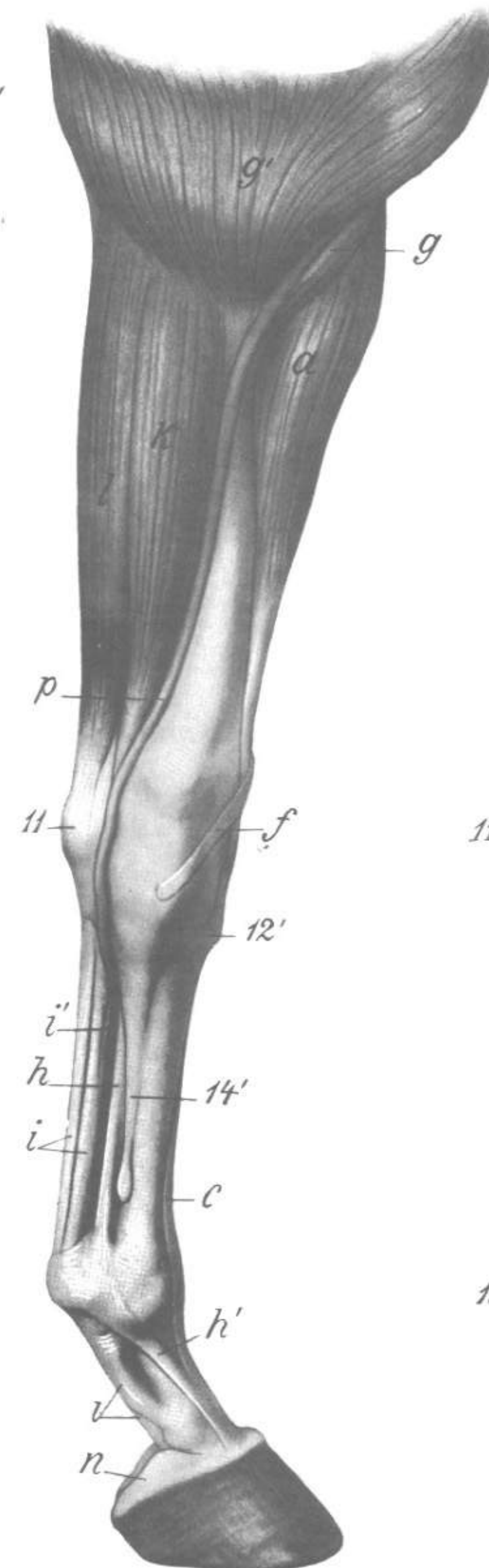


FIG. 34

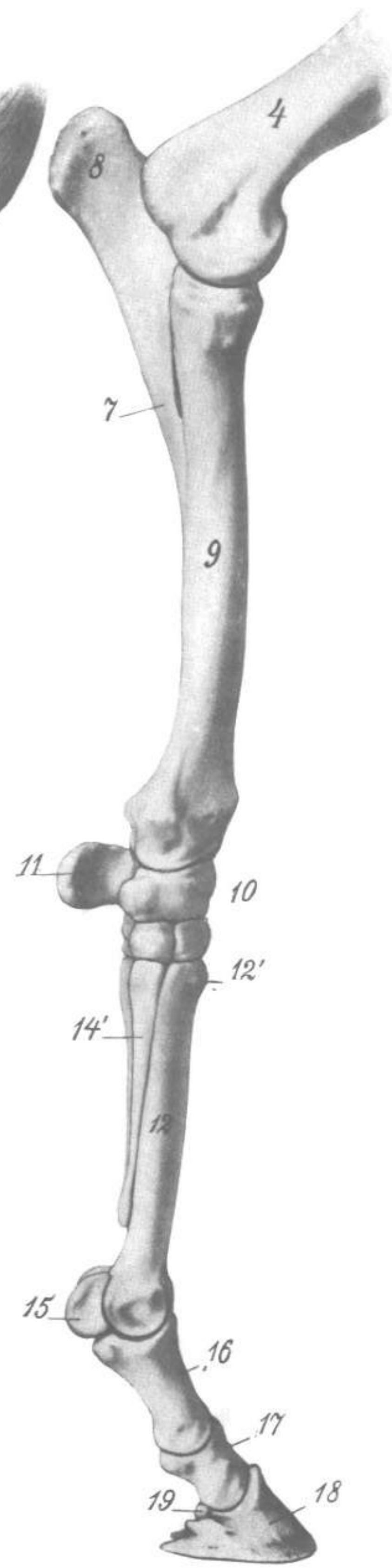


FIG. 35

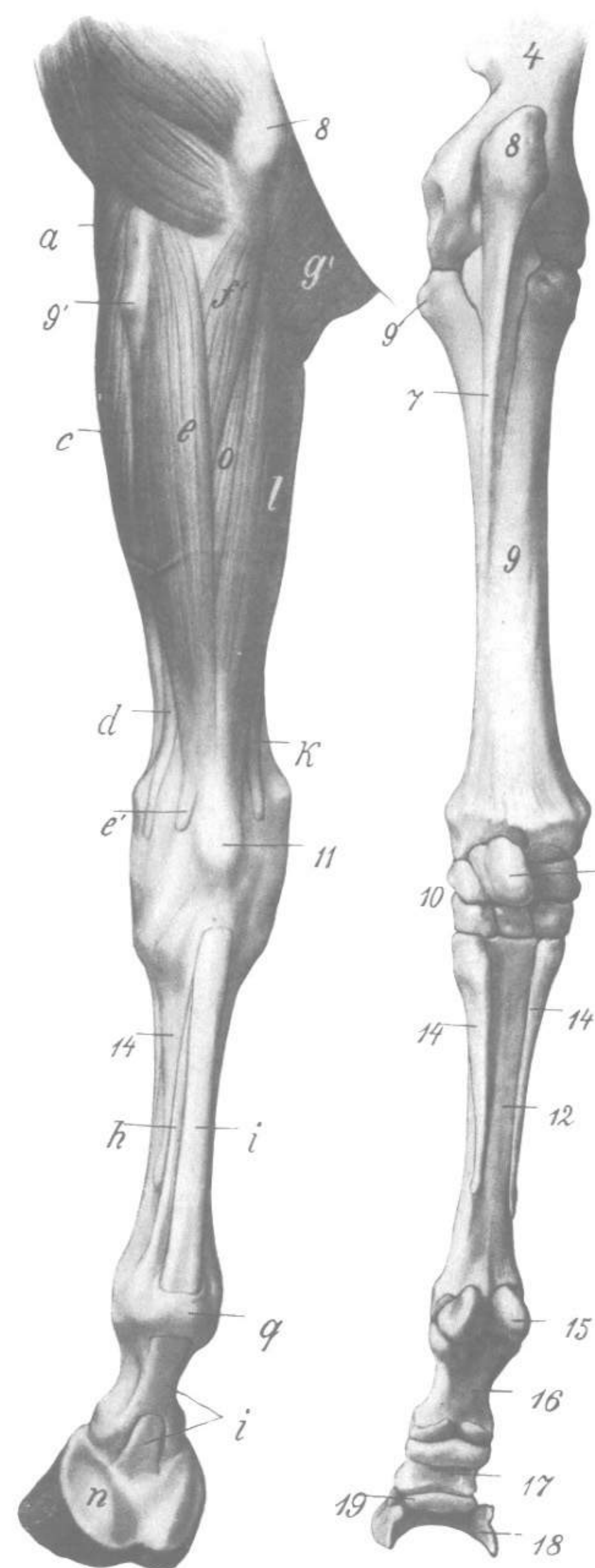


FIG. 36

FIG. 37

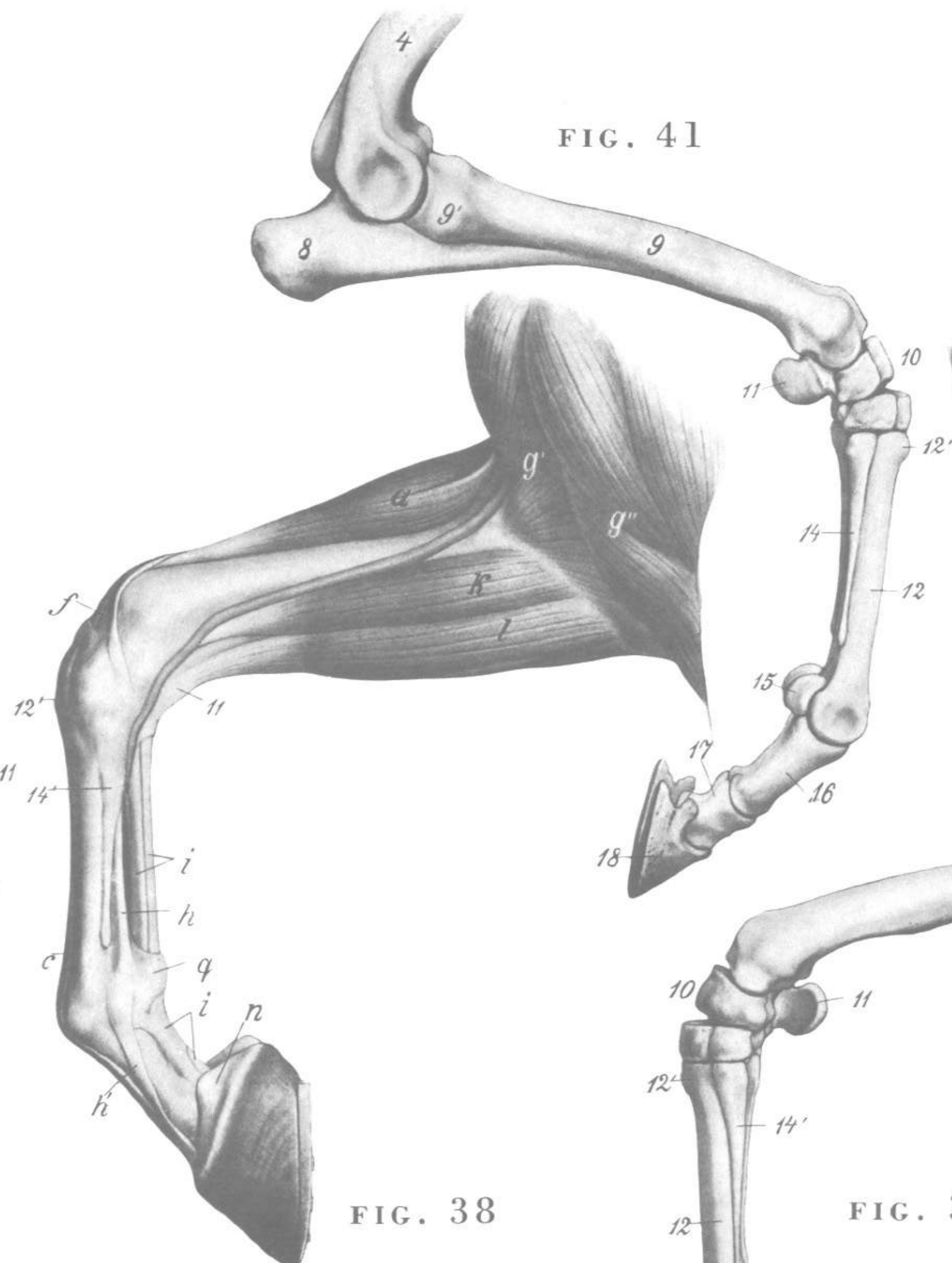


FIG. 38

FIG. 41

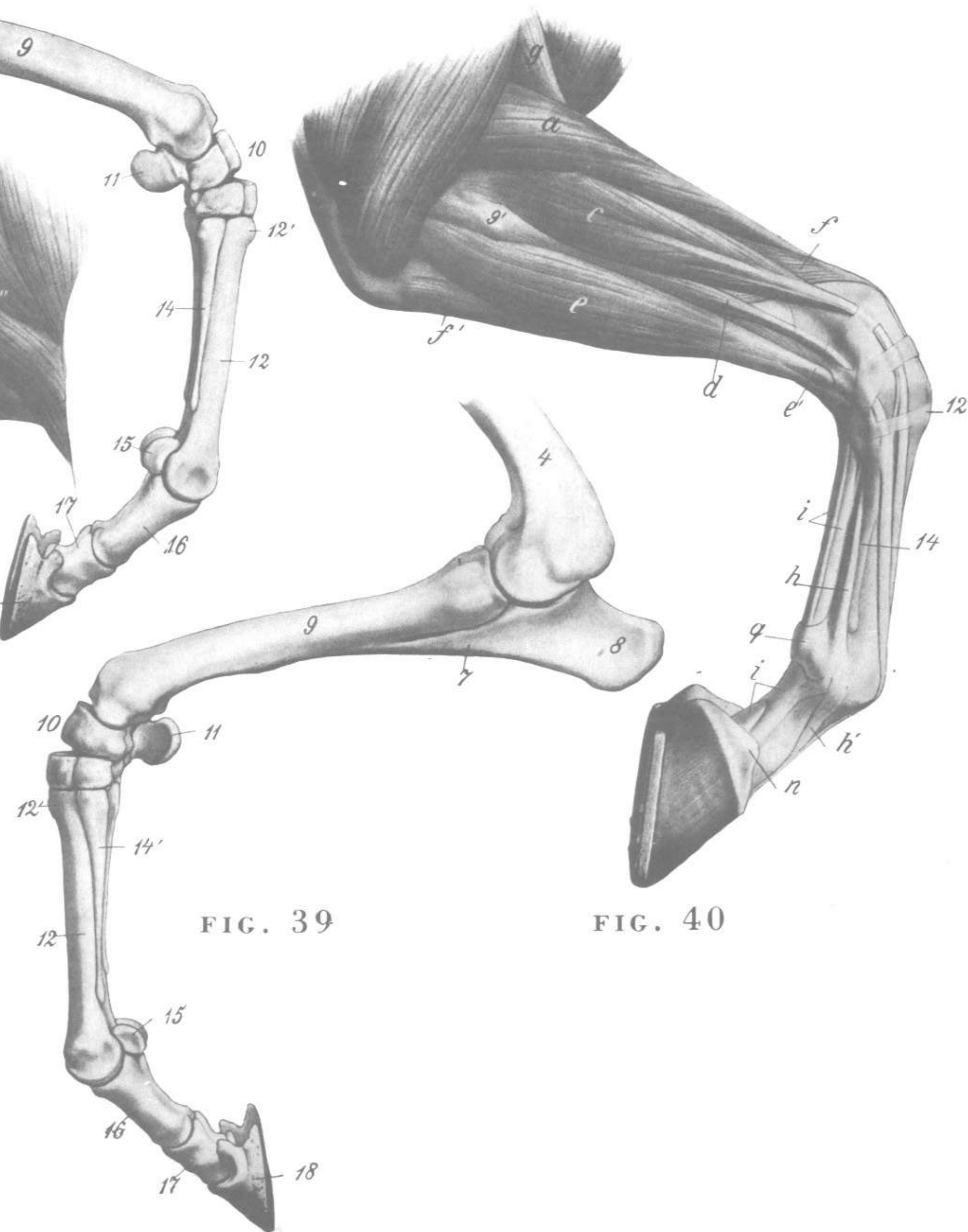


FIG. 39

FIG. 40

THE HORSE - PLATES 13 14 15

FIGURES 42 43 44 45 46 47 48 49 50 51 52 53 54 55 56 57
58 59

a—*M. tibialis anterior*
a'—Inner branch of *M. tibialis anterior*
a''—Outer branch of *M. tibialis anterior*
a'''—*M. peroneus tertius*
b, b'—*M. extensor digitorum longus*
d, d'—*M. extensor digitorum pedis lateralis*
e—*M. flexor hallucis longus*
e'—Fusion of tendon and *M. flexor hallucis longus*
e''—*M. tibialis posterior*
f—*Mm. gastrocnemii*
f'—*Tendo Achillis*
f''—*M. soleus*
g—Superficial flexor tendon
h—*M. interosseus medius*
i, i', i''—Annular ligaments
l—Tendinous band from the *interosseus medius* to the common extensor tendon
m—*M. flexor digitorum pedis longus*
m'—Tendon of *M. flexor digitorum pedis longus*
o—*M. popliteus*
o'—Fascia covering the *M. quadriceps femoris*
q, q', q''—End of the *M. biceps femoris*
q'''—Tendinous band from *M. biceps femoris* to fascia of leg

r—End of the *M. semitendinosus*
r'—Tendon of *M. semitendinosus*
w—End of the *M. gracilis*
x—End of the *M. sartorius*
y—End of the *M. quadriceps femoris*
18—Lower end of femur
20—Patella
21—Tibia
21'—External condyle of tibia
21''—External malleolus of tibia
21'''—Internal malleolus of tibia
22—Tarsus
22'—Os tarsi tibiale
23—Fibula
24—Tuber calcanei
25—Large metatarsal bone
25'—Inner small metatarsal bone
25''—Nodular enlarged end of inner small metatarsal bone
29—Sesamoid bone of 1st digital joint
30—Phalanx prima
31—Phalanx secunda
32—Phalanx tertia
36—Crista tibiae

37—External long lateral ligament of the hock joint
37'—Inner edge of the lower surface of the sole, right fore hoof
38—External short lateral ligament of the hock joint
38'—Outer edge of the lower surface of the sole, right fore hoof
39—Plantar ligament of the hock joint
39'—Bearing edge, right fore hoof, unshod
40—Oblique ligament of the hock joint
40'—So-called white line, right fore hoof
41—Internal long lateral ligament of the hock joint
41'—Sole, right fore hoof
42—Internal short lateral ligament of the hock joint
42'—Apex of frog, right fore hoof
43—Branch of frog, right fore hoof
44—Median furrow of frog, right fore hoof
45—Lateral furrow of frog, right fore hoof
46—Bar, right fore hoof
47—Left fore hoof, shod
48—Left hind hoof, shod

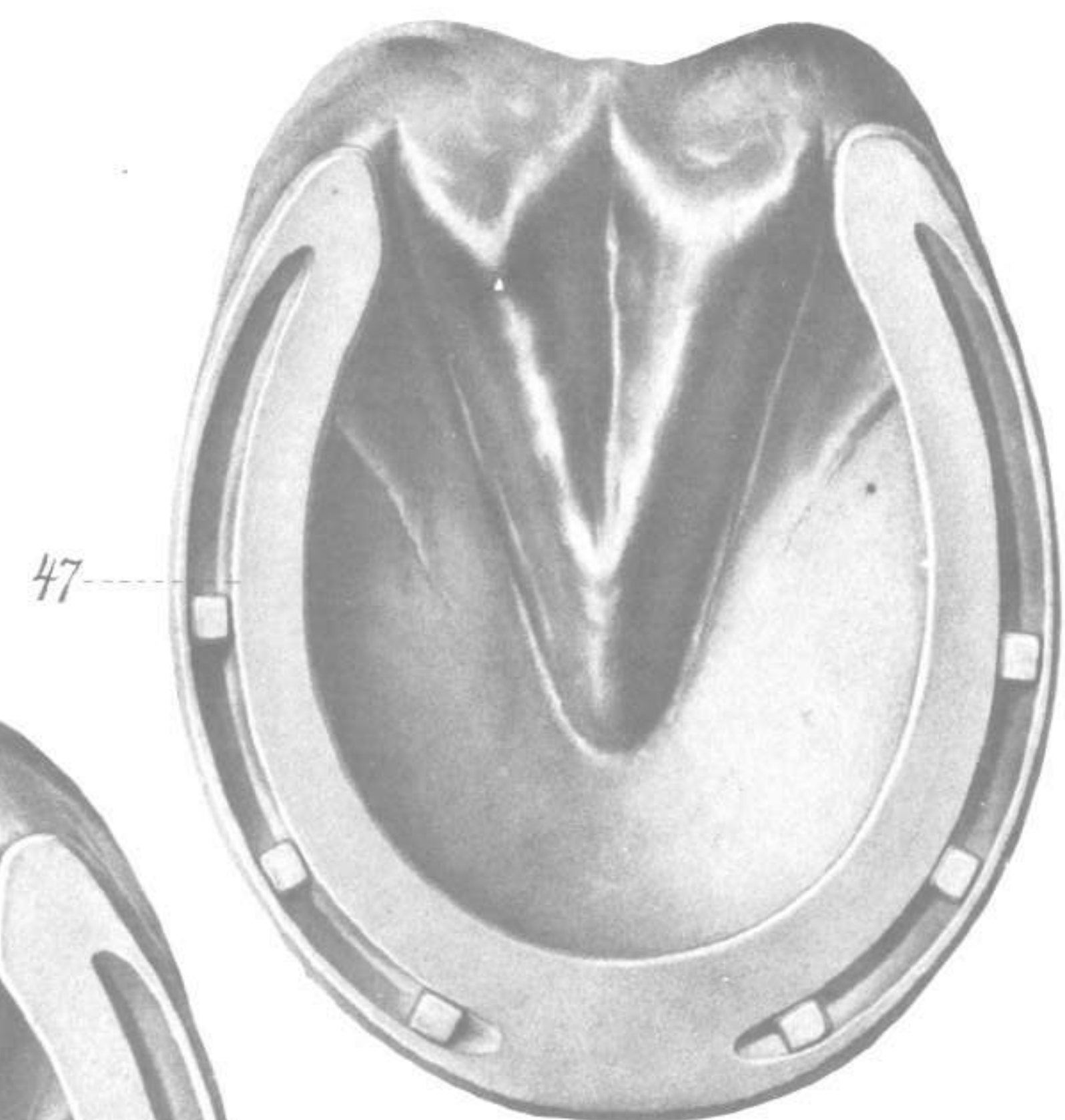
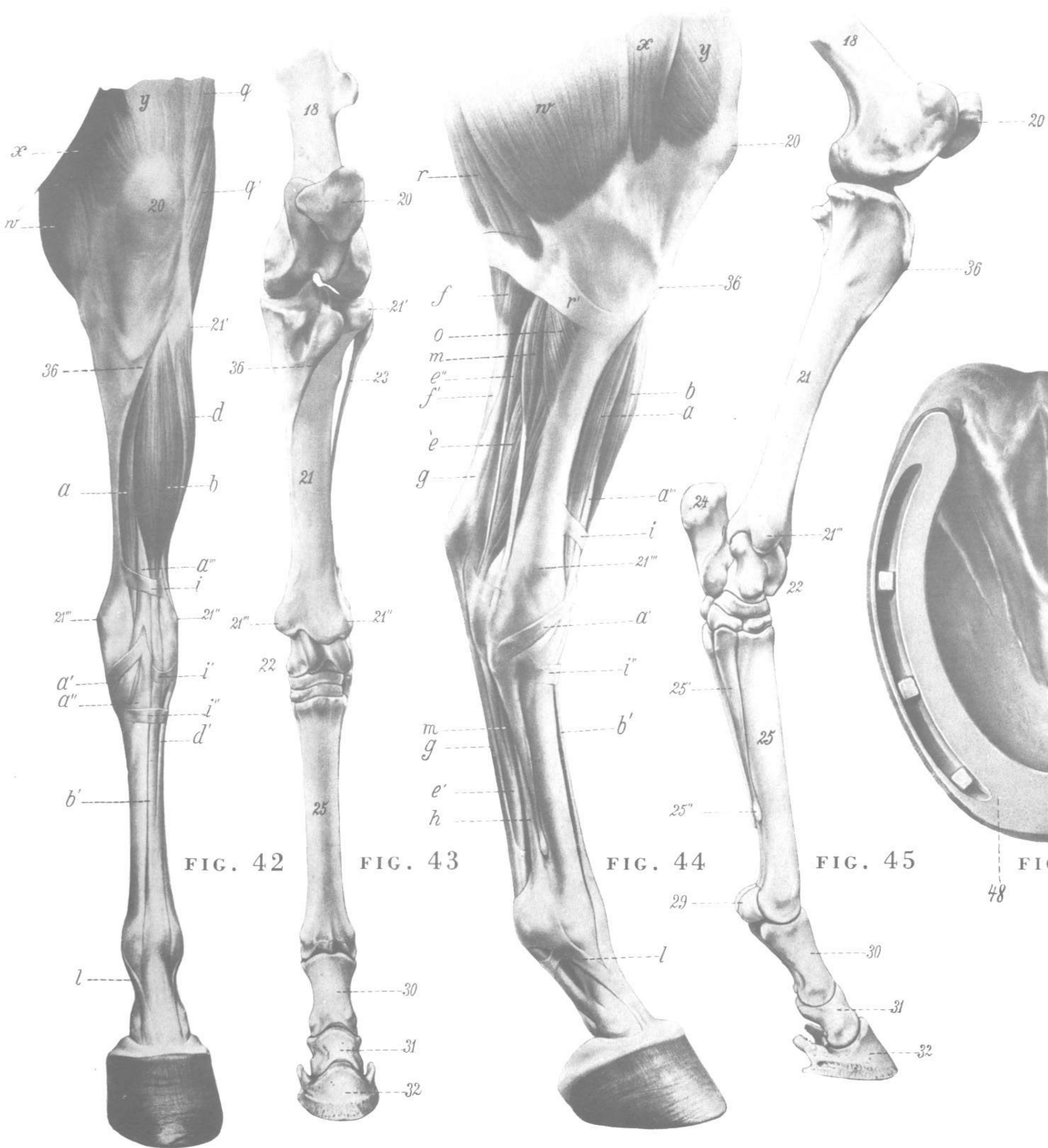


FIG. 47

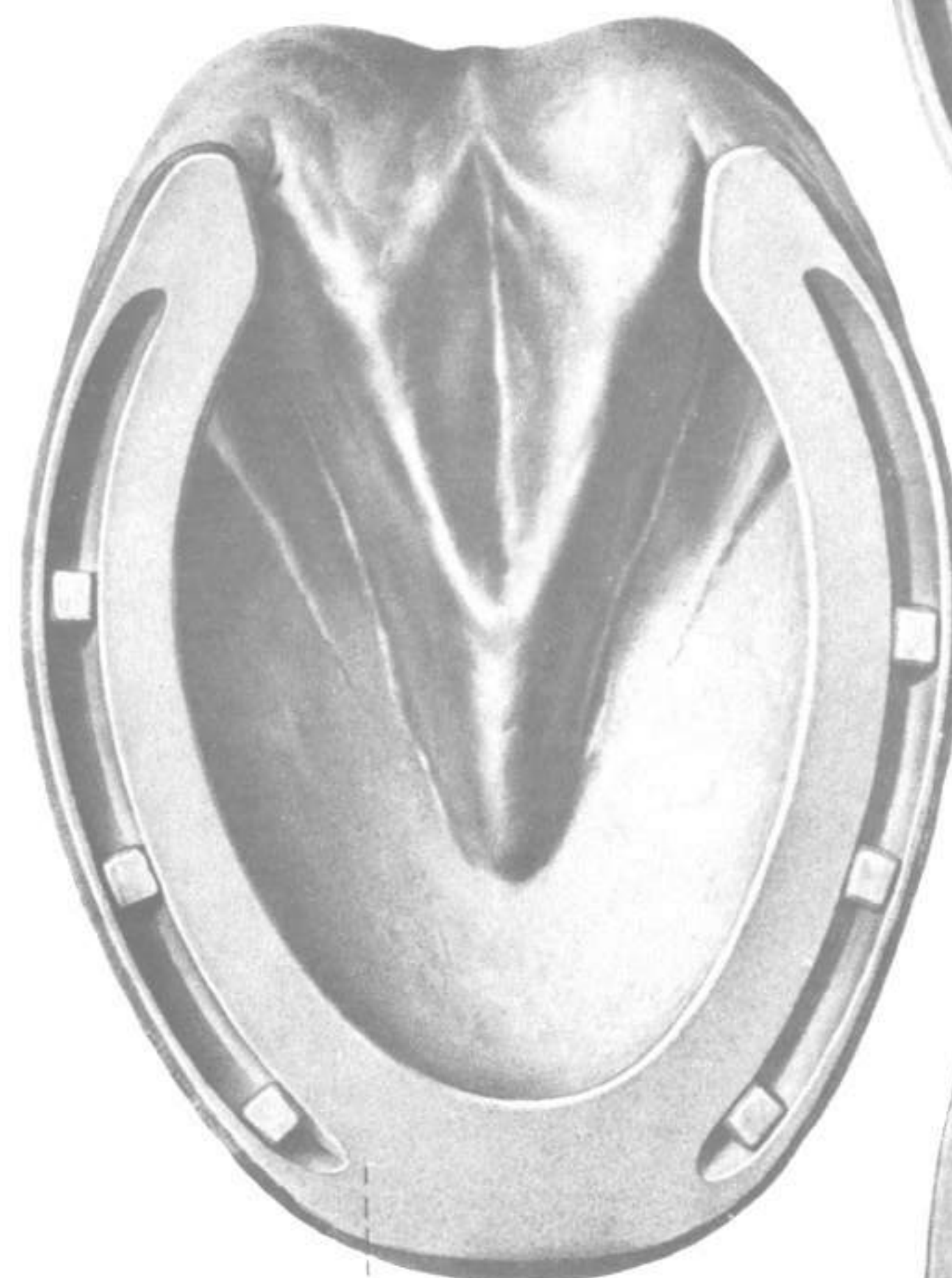


FIG. 48

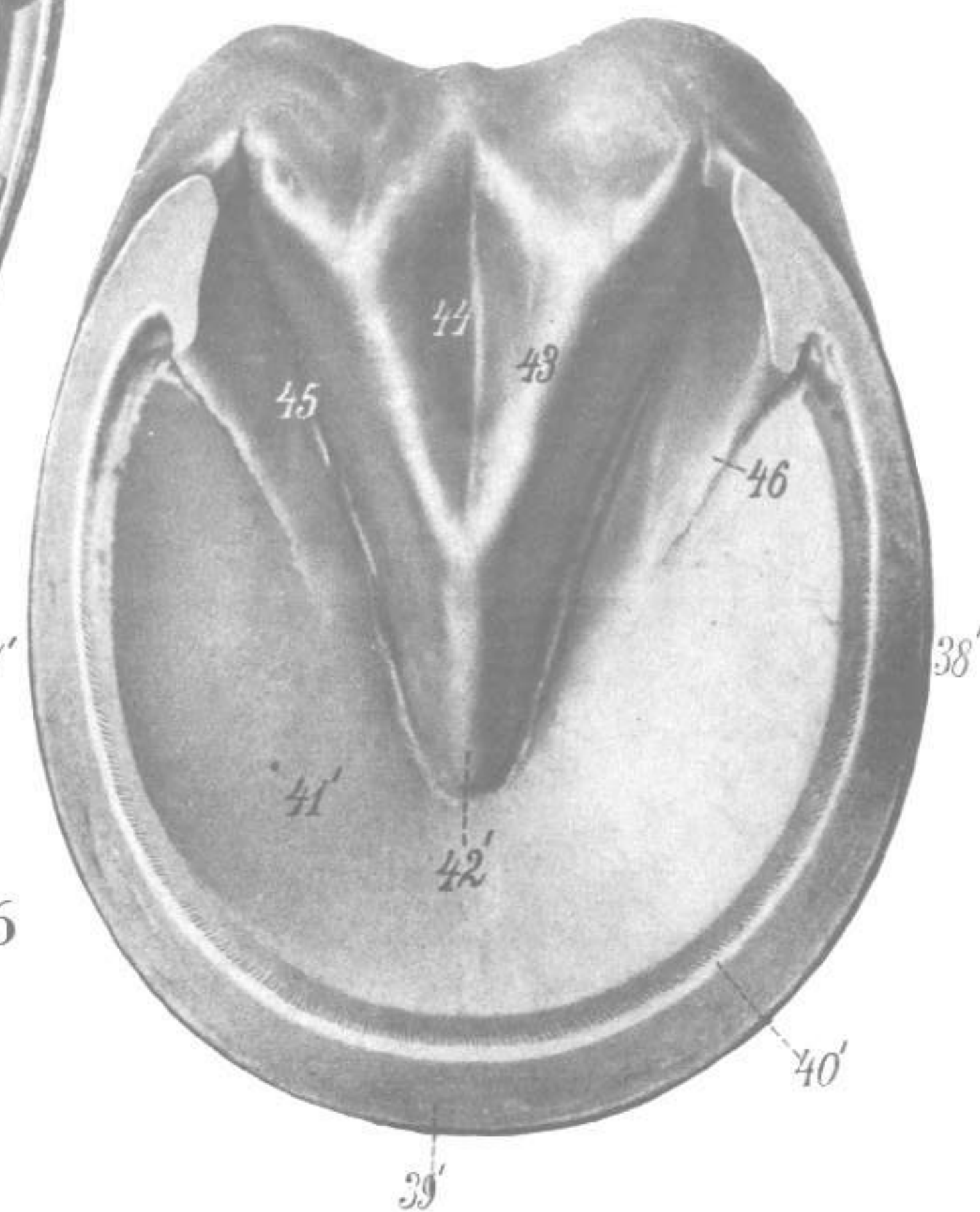


FIG. 46

THE HORSE PLATE 14

FIG. 49

FIG. 50

FIG. 51

FIG. 52

FIG. 53

FIG. 54

FIG. 55

THE HORSE PLATE 14

FIG. 49

FIG. 50

FIG. 51

FIG. 52

FIG. 53

FIG. 54

FIG. 55

THE HORSE PLATE 14

FIG. 49

FIG. 50

FIG. 51

FIG. 52

FIG. 53

FIG. 54

FIG. 55

THE HORSE PLATE 14

FIG. 49

FIG. 50

FIG. 51

FIG. 52

FIG. 53

FIG. 54

FIG. 55

THE HORSE PLATE 14

FIG. 49

FIG. 50

FIG. 51

FIG. 52

FIG. 53

FIG. 54

FIG. 55

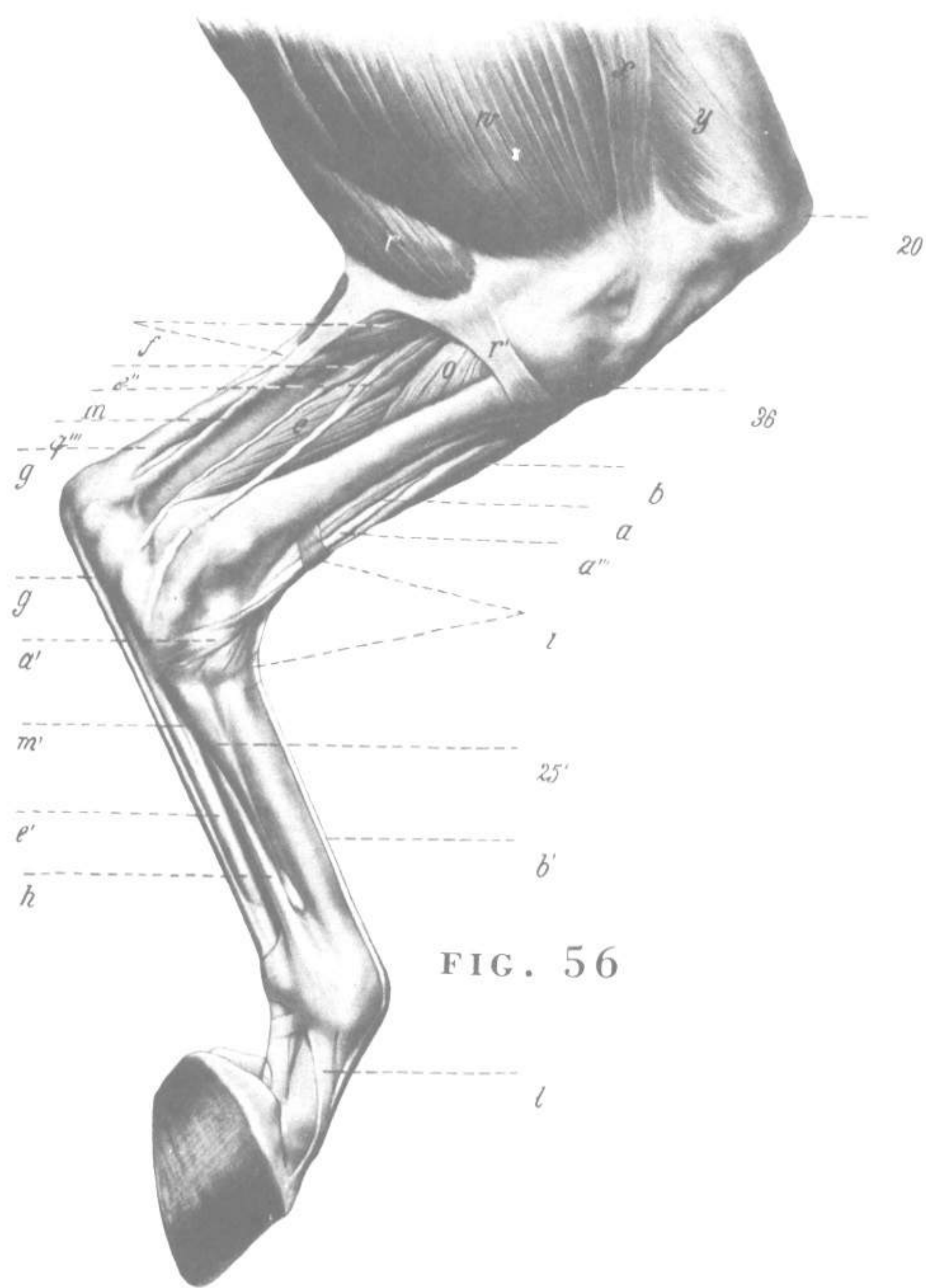


FIG. 56

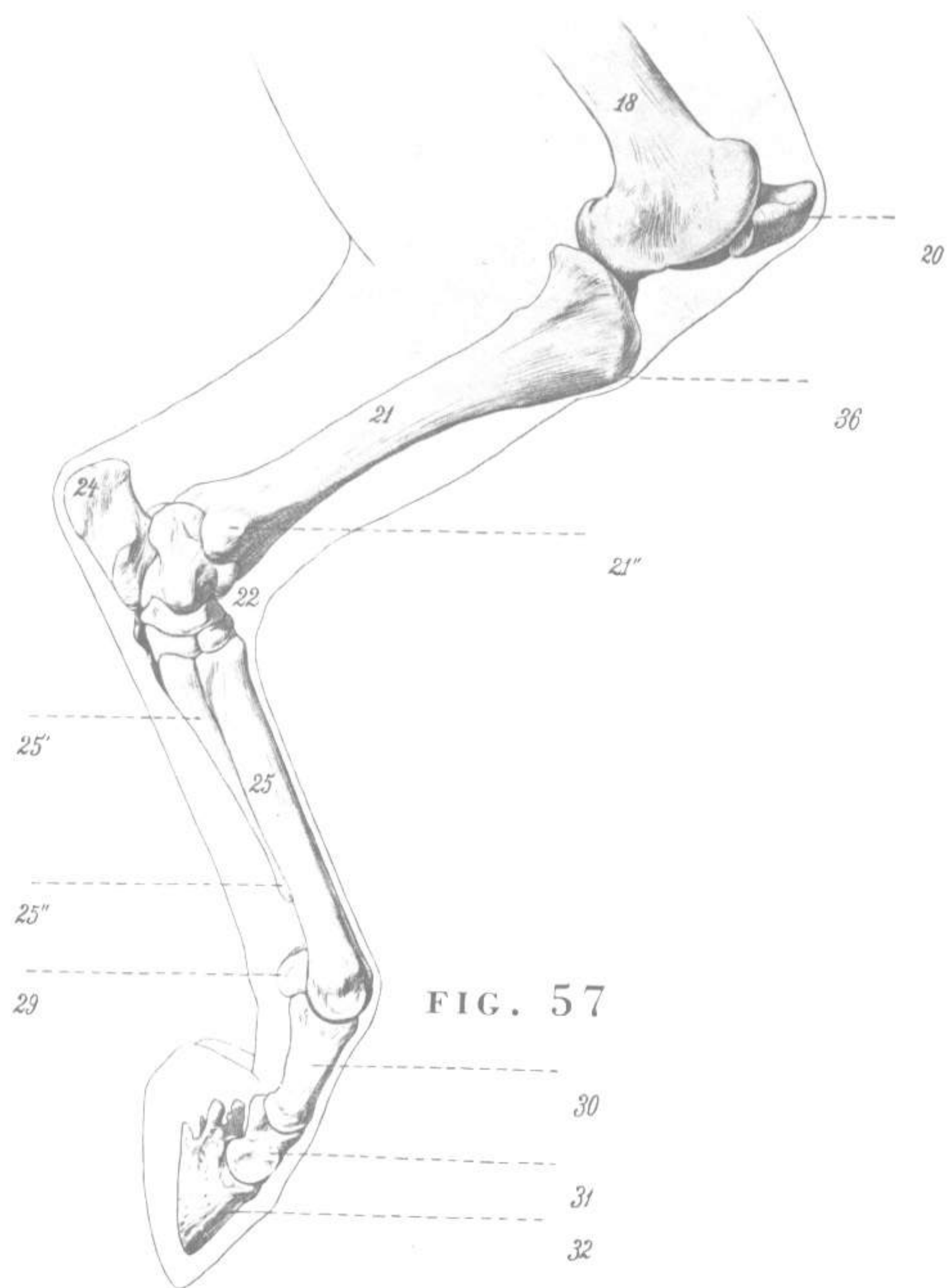


FIG. 57

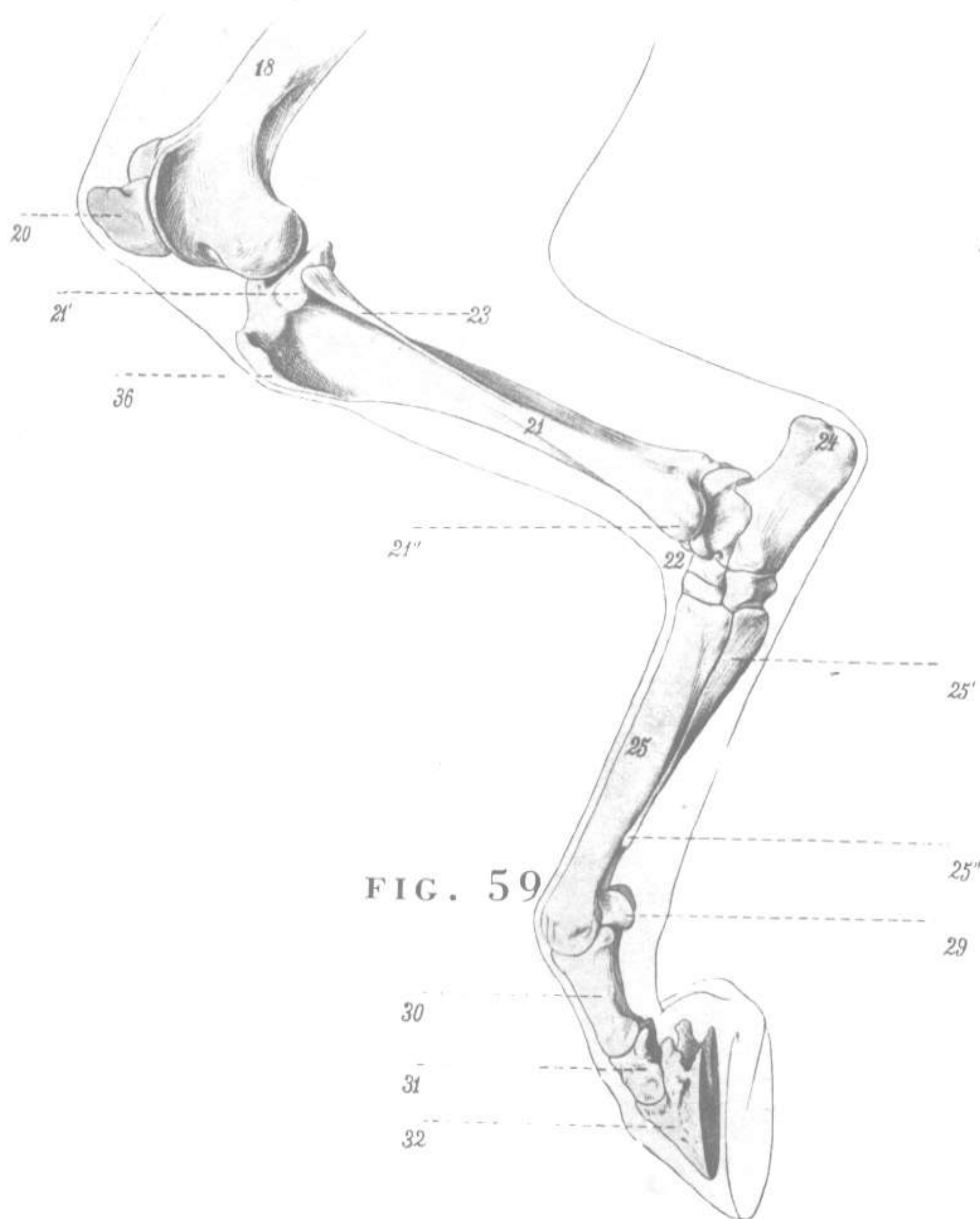


FIG. 59

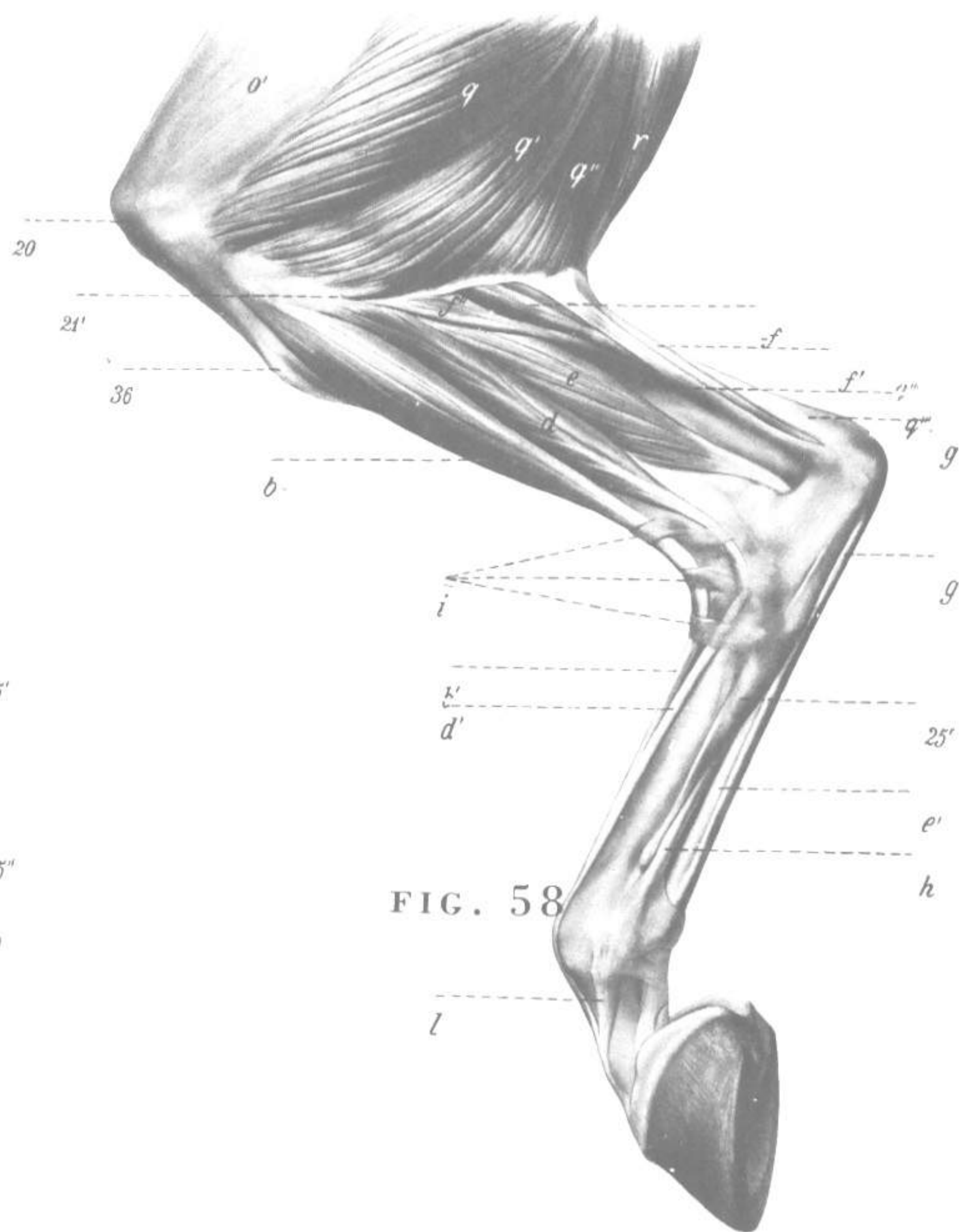


FIG. 58

THE HORSE · PLATE 16

FIGURES 60 61 62 63 64 65 66 67

a, a', a''—Straight patellar ligaments
 b, b'—Lateral patellar ligaments
 c—External lateral ligaments of the stifle (or femoro-tibial) joint
 c'—Internal lateral ligaments of the stifle (or femoro-tibial) joint
 d—Menisci
 e—External lateral ligament of the carpal joint
 e'—Internal lateral ligament of the carpal joint

f—Lig. pisometacarpeum
 9—Lower end of the radius
 9''—External tuberosity of the radius
 9'''—Internal tuberosity of the radius
 11—Os pisiforme
 12—Large metacarpal bone
 12'—Tuberosity of large metacarpal bone
 14—External small metacarpal bone
 14'—Internal small metacarpal bone

18—Lower end of the femur
 18'—Inner ridge of the trochlea of the femur
 20—Patella
 20'—Cartilage serving to complete the patella
 21—Tibia
 21'—External condyle of tibia
 23—Fibula
 36—Crista tibiae

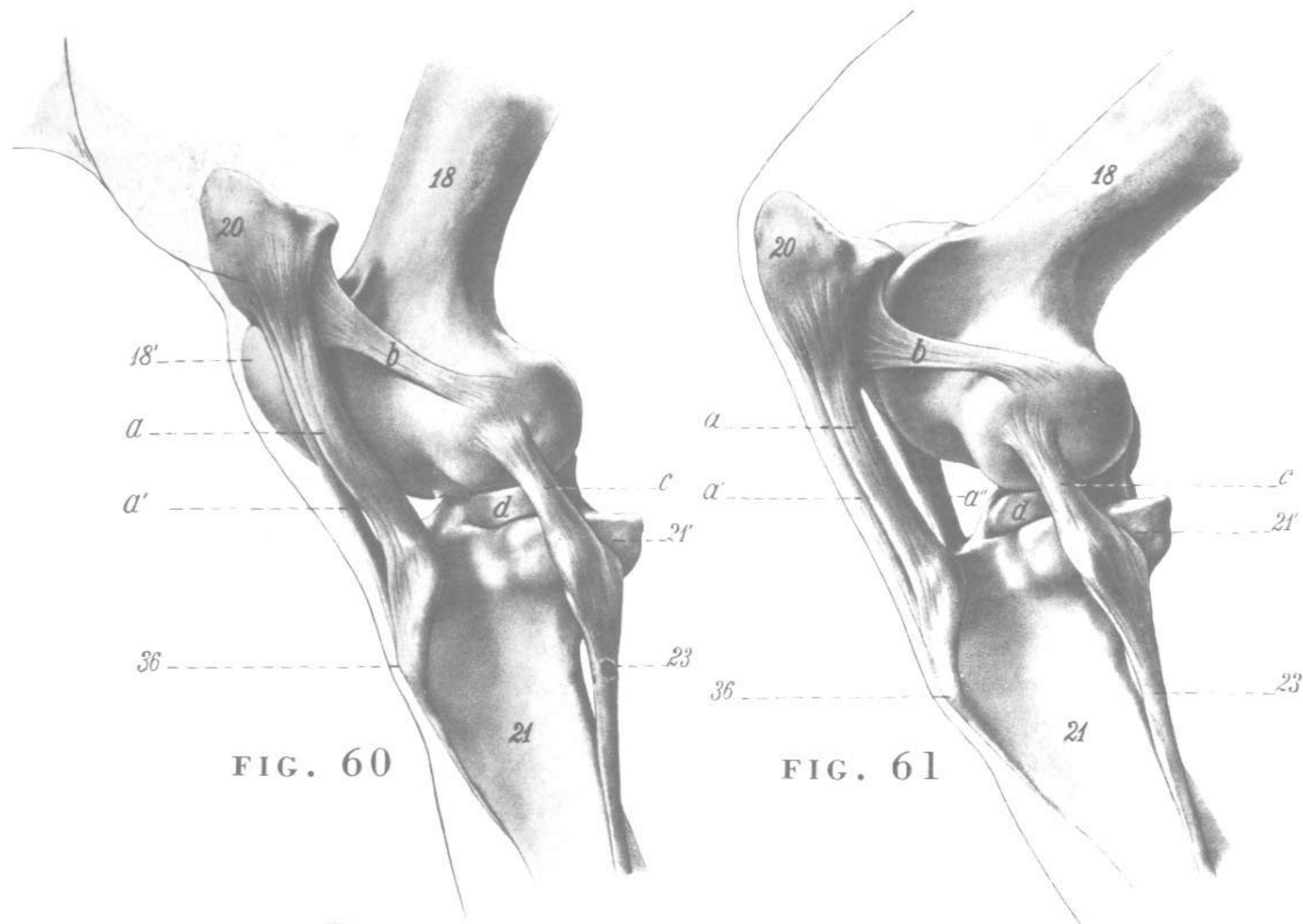


FIG. 60

FIG. 61

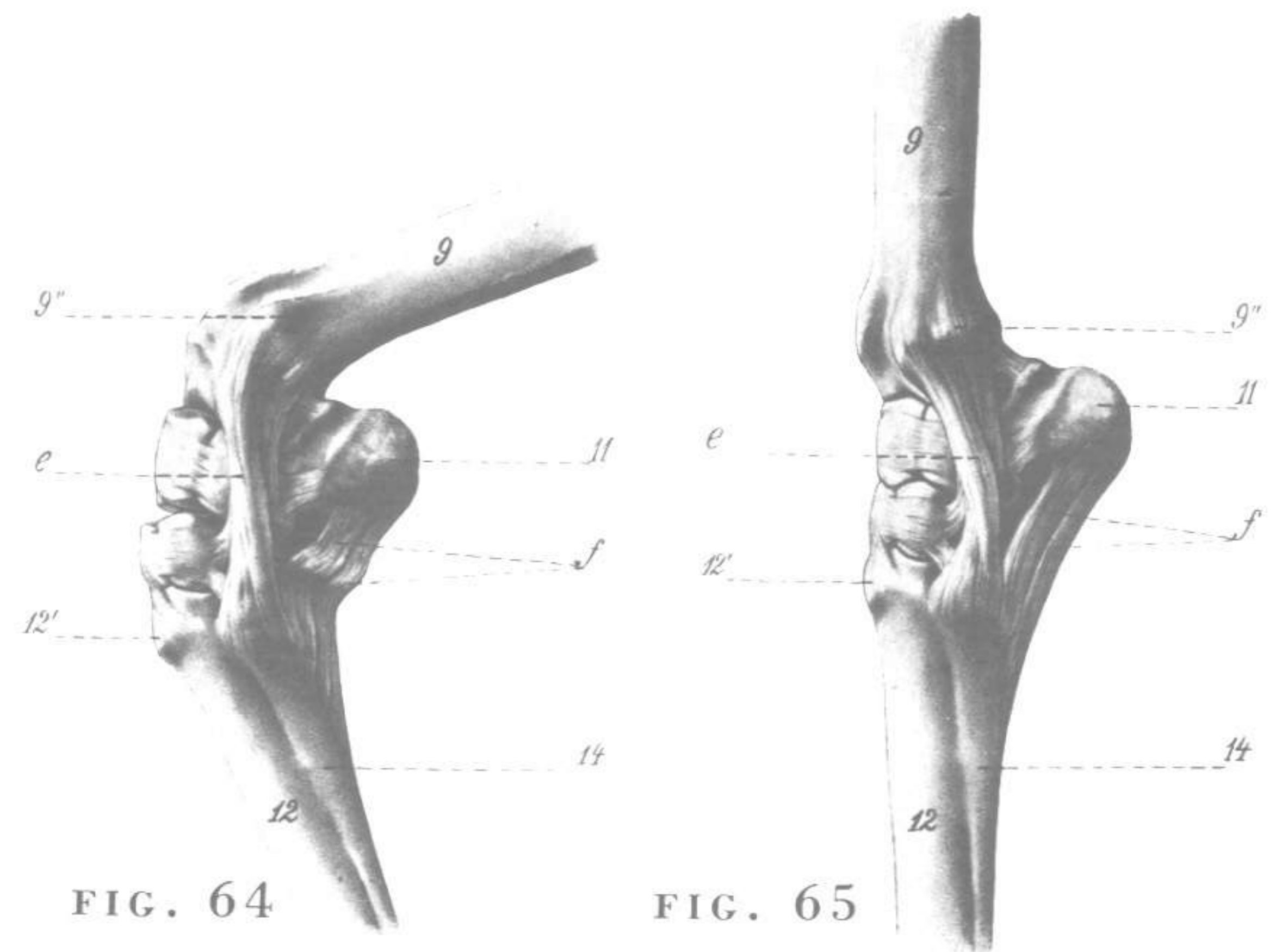


FIG. 64

FIG. 65

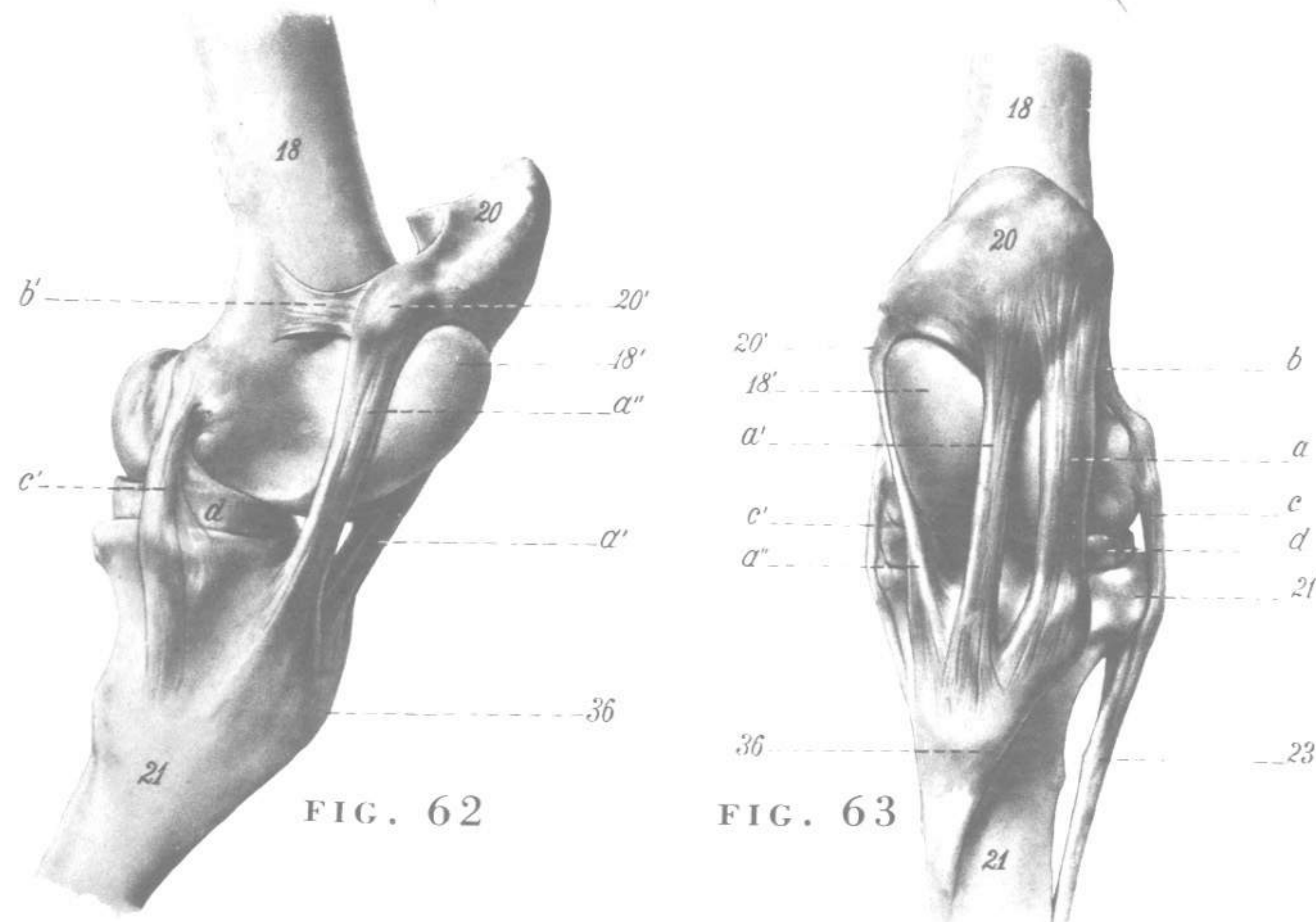


FIG. 62

FIG. 63

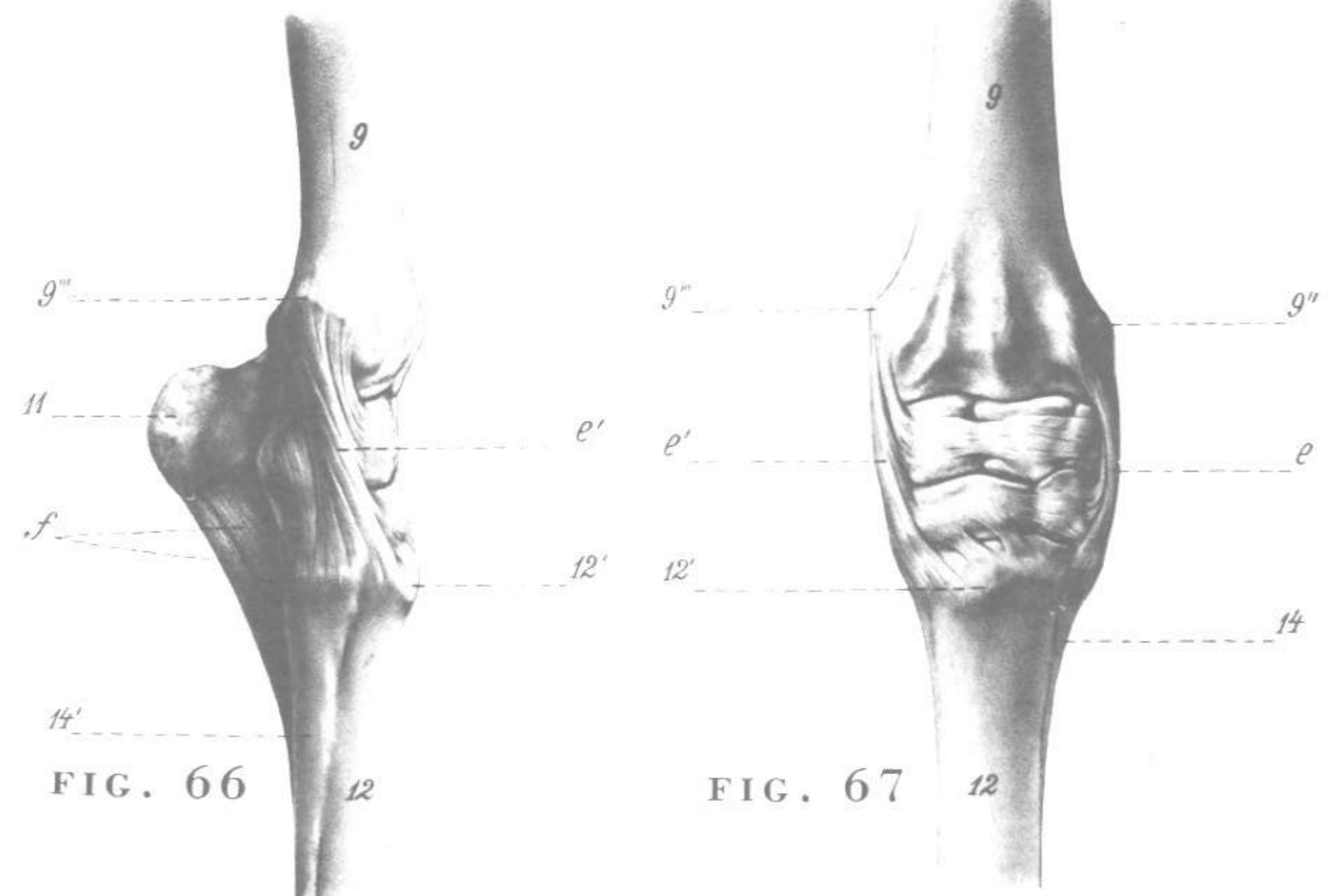


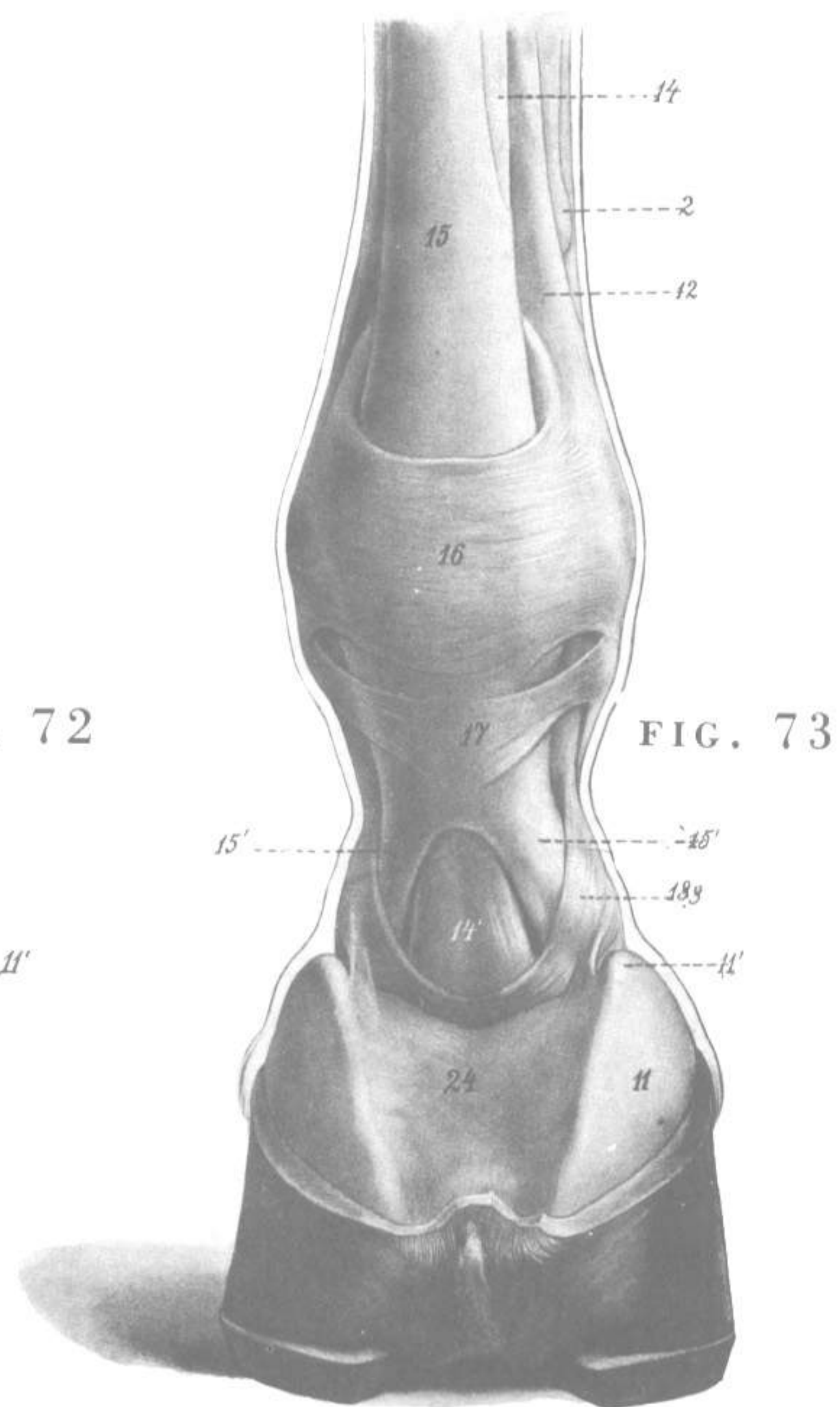
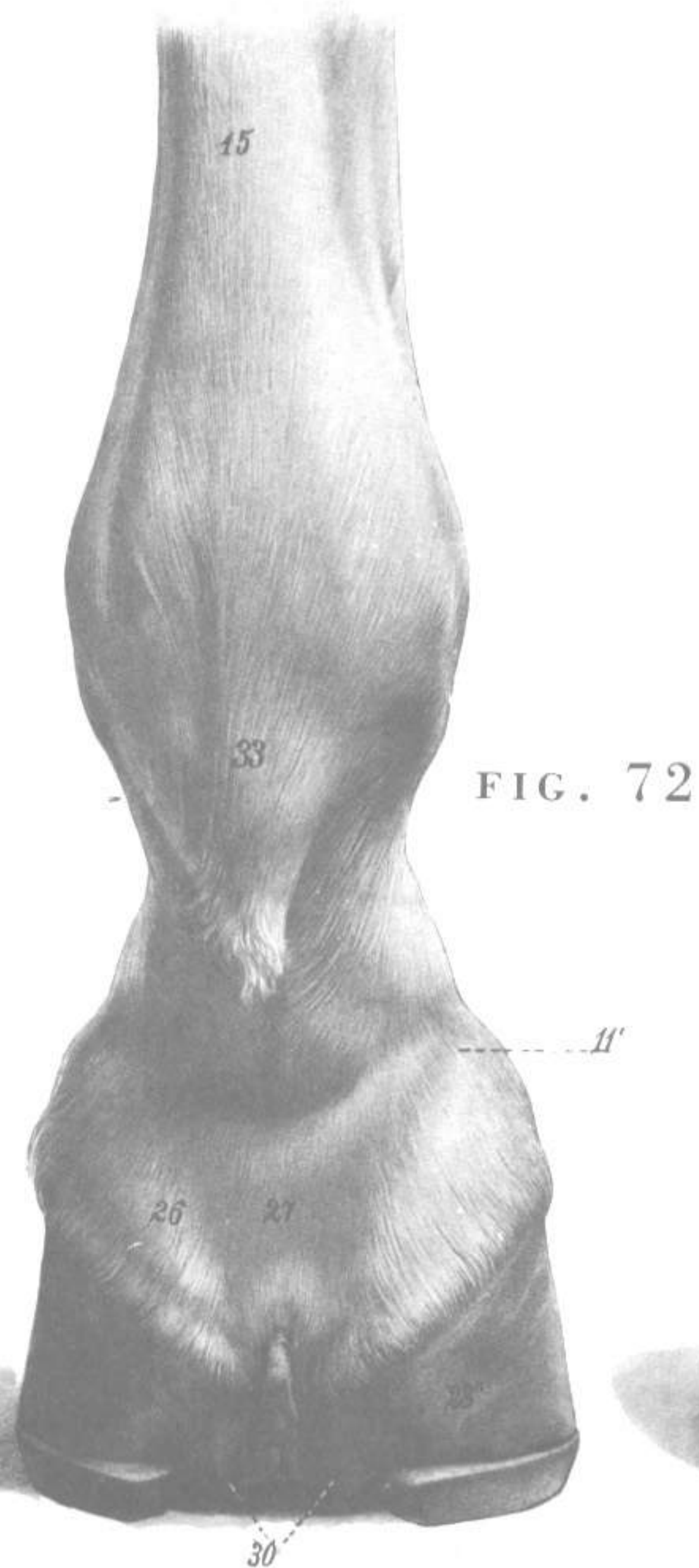
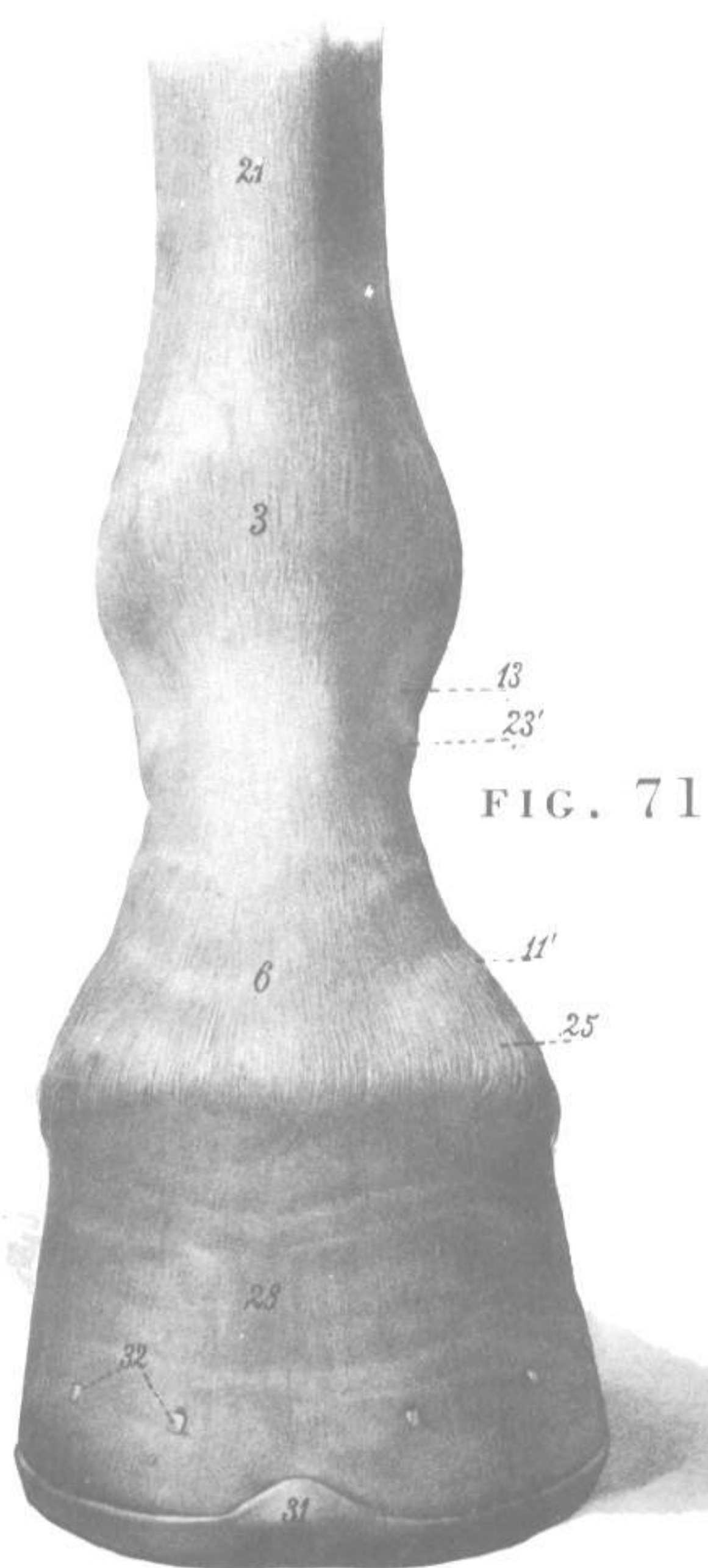
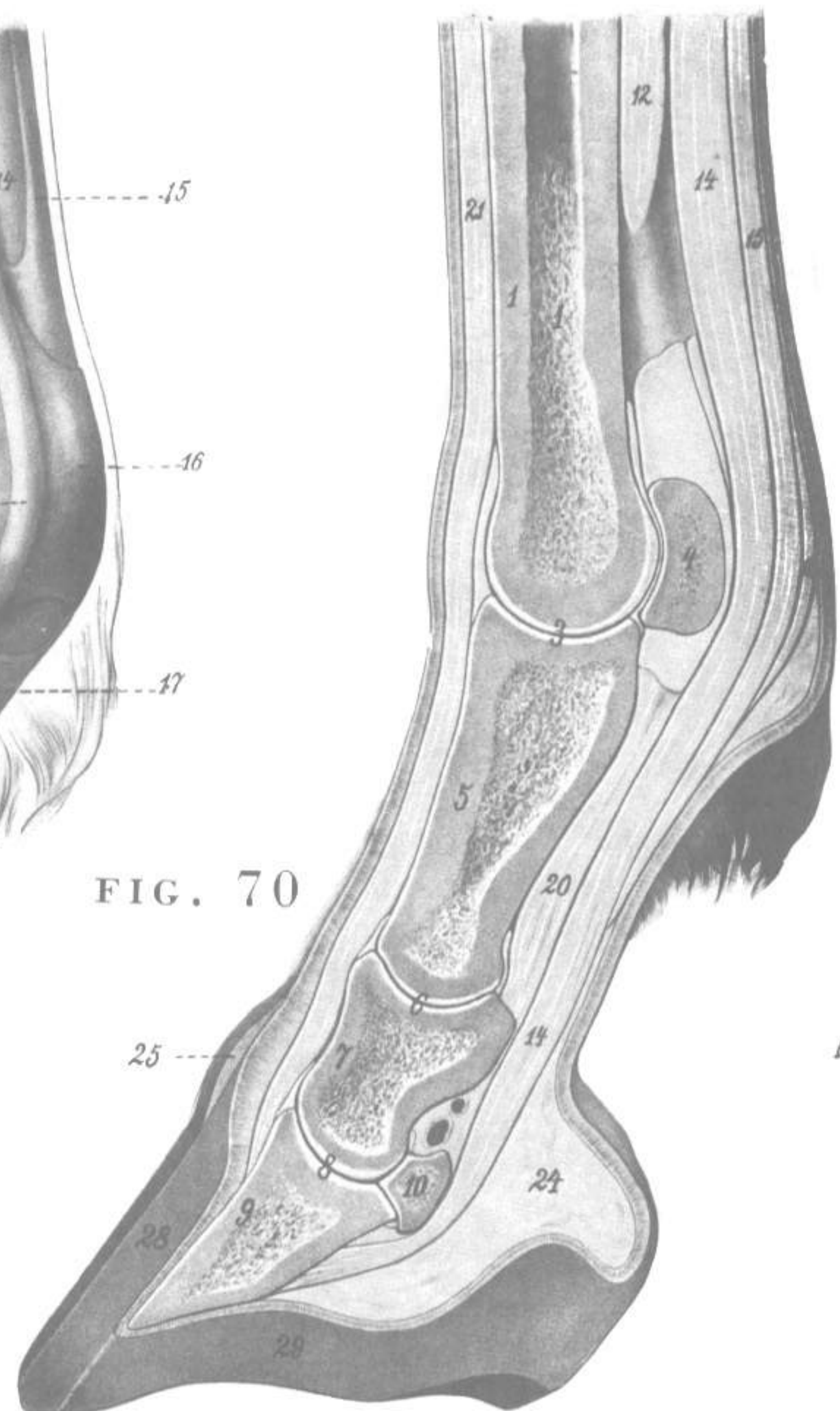
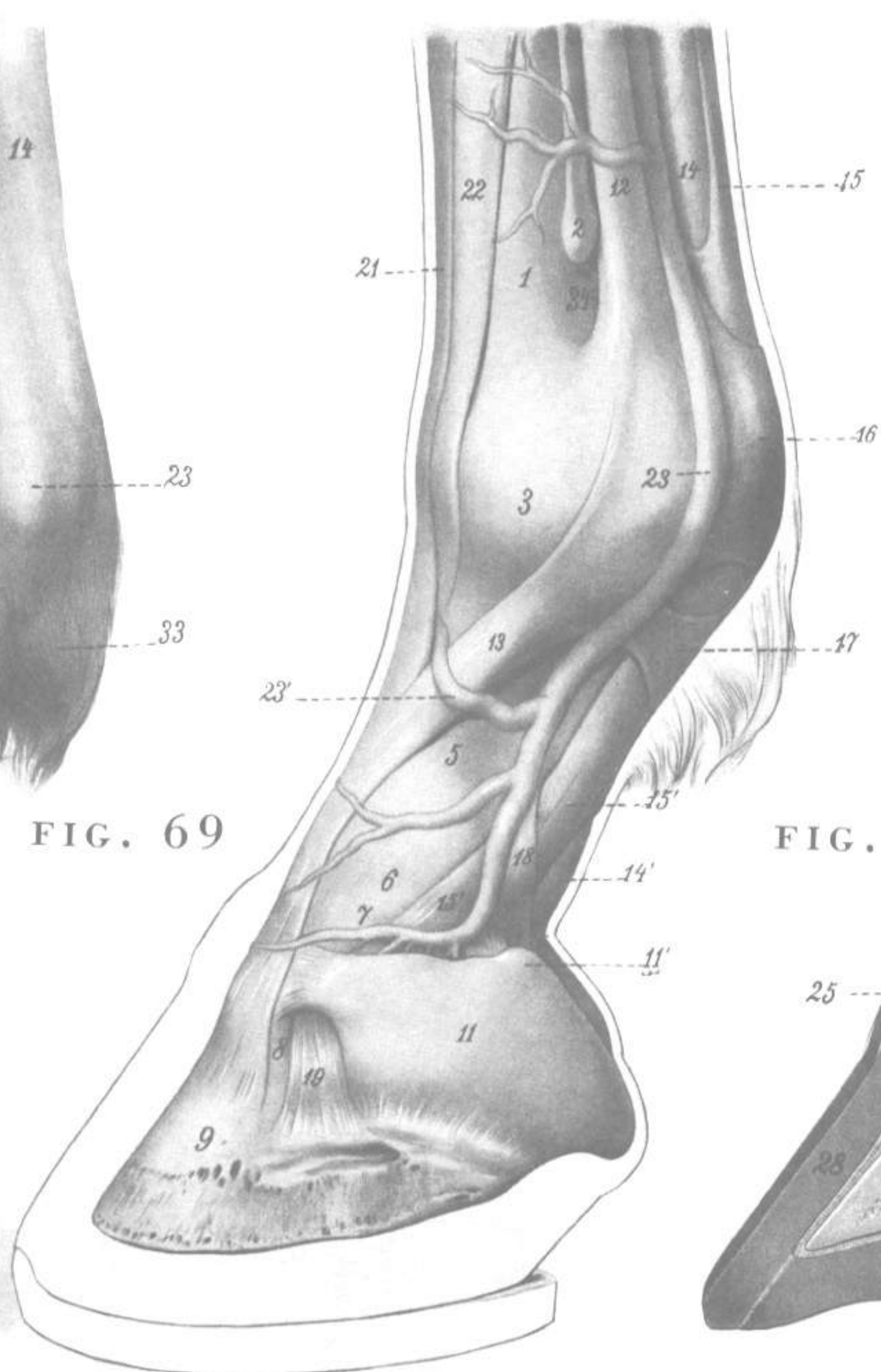
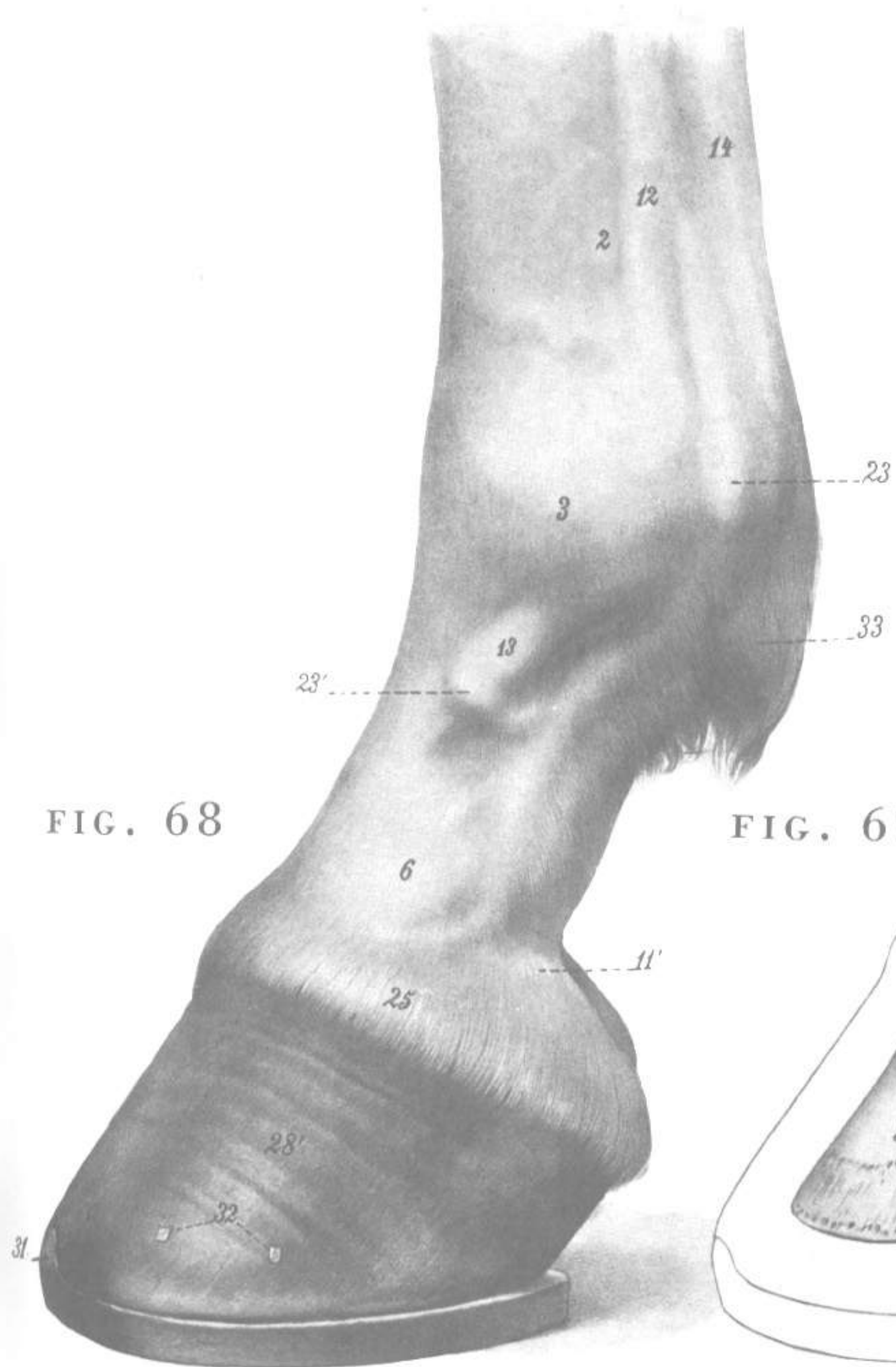
FIG. 66

FIG. 67

THE HORSE - PLATE 17

FIGURES 68 69 70 71 72 73

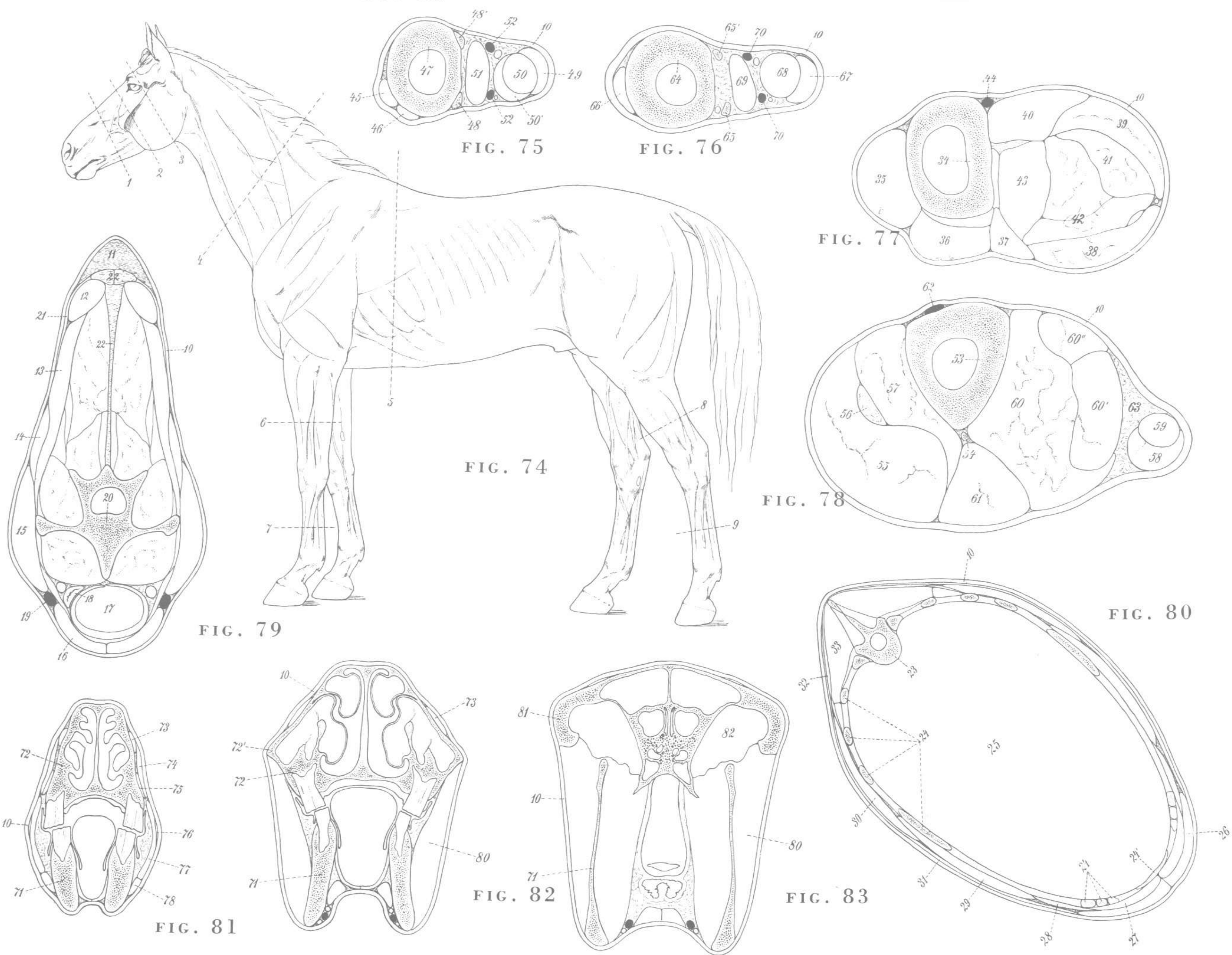
- | | | |
|---|--|---|
| 1—Large metacarpal bone | 14, 14'—Deep flexor tendon | 27—Interbulbar furrow |
| 2—Lower nodular end of the external small metacarpal bone | 15—Superficial flexor tendon | 28—Toe of the wall of the hoof |
| 3—1st digital or fetlock joint | 15'—Terminal branches of the flexor tendon | 28'—Quarter of the wall of the hoof |
| 4—Sesamoid bone | 16—Annular ligament of the fetlock | 28''—Heel of the wall of the hoof |
| 5—First phalanx or large pastern bone | 17—Vaginal ligament | 29—Sole of the hoof |
| 6—Second digital or pastern joint | 18—Reinforcing sheath of the deep flexor tendon | 30—Frog of the hoof |
| 7—Second phalanx or small pastern bone | 19—Lateral ligament of the coffin joint | 31—Clip of the shoe |
| 8—Third digital or coffin joint | 20—Straight sesamoidean ligament | 32—Clinches of the horseshoe nails |
| 9—Third phalanx of coffin bone | 21—Tendon of the common digital extensor muscle | 33—Fetlock (tuft) |
| 10—Sesamoid bone of the 3rd digital joint | 22—Tendon of the lateral digital extensor muscle | 34—A small depression occurring under the nodular enlarged end of the small cannon bone |
| 11, 11'—Lateral cartilage | 23, 23'—Lateral digital vein | |
| 12—M. interosseus medius | 24—Plantar cushion | |
| 13—Tendinous band extending from the suspensory ligament to the extensor tendon | 25—Coronet | |
| | 26—Bulb | |



THE HORSE - PLATE 18

FIGURES 74 75 76 77 78 79 80 81 82 83

- 1—Plane of the cross section of the head shown in Fig. 81 on Plate 18
- 2—Plane of the cross section of the head shown in Fig. 82 on Plate 19
- 3—Plane of the cross section of the head shown in Fig. 83 on Plate 18
- 4—Plane of the cross section of the neck shown in Fig. 79 on Plate 18
- 5—Plane of the cross section of the chest shown in Fig. 80 on Plate 18
- 6—Plane of the cross section of the fore-arm shown in Fig. 77 on Plate 18
- 7—Plane of the cross section of the fore-cannon shown in Fig. 75 on Plate 18
- 8—Plane of the cross section of the leg shown in Fig. 78 on Plate 18
- 9—Plane of the cross section of the hind-cannon shown in Fig. 76 on Plate 18
- 10—Outer skin
- 11—Nuchal fat
- 12—*M. rhomboideus*
- 13—*M. splenius*
- 14—Cervical part of *M. serratus magnus*
- 15—*M. mastoido-humeralis*
- 16—*M. sterno-cephalicus*
- 17—Trachea
- 18—Oesophagus
- 19—*V. jugularis*
- 20—5th cervical vertebra
- 21—*M. trapezius*
- 22—Ligamentum nuchae
- 23—Thoracic vertebra
- 24—Rib sections
- 24'—Xiphoid cartilage
- 25—Thoracic cavity
- 26—*M. pectoralis minor*
- 27—*M. rectus abdominis*
- 28—*M. obliquus abdominis externus*
- 29—Thoracic part of the *M. serratus magnus*
- 30—*M. latissimus dorsi*
- 31—Panniculus carnosus of the abdomen
- 32—Dorsal part of the *M. trapezius*
- 33—*M. longissimus dorsi*
- 34—Radius
- 35—*M. extensor carpi radialis*
- 36—*M. extensor digitorum communis*
- 37—*M. extensor digiti lateralis*
- 38—*M. extensor carpi ulnaris*
- 39—*M. flexor carpi ulnaris*
- 40—*M. flexor carpi radialis*
- 41—*M. flexor digiti sulimidis*
- 42, 43—*M. flexor digiti profundus*
- 44—Greater subcutaneous vein
- 45—Tendon of the common extensor of the digit
- 46—Tendon of the lateral extensor of the digit
- 47—Large metacarpal bone
- 48, 48'—Outer and inner small metacarpal bones
- 49—Superficial flexor tendon
- 50—Deep flexor tendon
- 50'—Reinforcing ligament of the flexor tendon
- 51—*M. interosseus medius*
- 52—Large veins
- 53—Tibia
- 54—Fibula
- 55—Long or common extensor of the digit
- 56—*M. peroneus tertius*
- 57—*M. tibialis anterior*
- 58—Tendo Achillis
- 59—Superficial flexor tendon
- 60—Deep flexor of the digit
- 60'—*M. tibialis posterior*
- 60''—*M. flexor dig. longus*
- 61—*M. extensor dig. lateralis*
- 62—Internal subcutaneous vein
- 63—Tendinous tissue
- 64—Larte metatarsal bone
- 65, 65'—Outer and inner small metatarsal bones
- 66—Tendon of the long or common digital extensor
- 67—Superficial flexor tendon
- 68—Deep flexor tendon
- 69—*M. interosseus medius*
- 70—Large veins
- 71—Mandible
- 72—Maxilla
- 72'—Zygomatic or facial crest
- 73—*M. levator labii sup. propius*
- 74—*M. levator labii sup. alaeque nasi*
- 75—*M. caninus s. pyramidalis nasi*
- 76—*M. zygomaticus major*
- 77—*M. buccinator*
- 78—*M. quadratus labii inferioris*
- 80—*M. masseter*
- 81—Frontal bone
- 82—Maxillary sinus



THE HORSE - PLATES 19 20

FIGURES 84 85 86 87 88

1—Height of withers
 2—Height of buttocks
 3—Length of the trunk
 4—Length (breadth) of the shoulder-arm vicinity
 5—Length of buttocks
 6—Length of the trunk
 7—Height of the trunk
 8—Height of the trunk
 9—Height of the trunk
 10—Transverse diameter of the trunk
 11—Transverse diameter of the trunk
 12—Transverse diameter of the trunk
 13—Transverse diameter of the trunk
 14—Distance between the two tuberosities of hips
 15—Length of the neck
 16—Height (breadth) of the insertion of the neck
 17—Height (breadth) of the neck
 18—Transverse diameter of the neck
 19—Transverse diameter of the neck
 20—Length of the head
 21—Distance between the outer canthus and foremost ridge of the upper lip
 22—Distance between the foremost end of the zygomatic bone and the foremost ridge of the upper lip
 23—Height of the head
 24—Breadth or transversal diameter of the head
 25—Breadth of the head
 26—Vertical distance of the nether chest-margin from the ground

27—Distance of the olecranon from the ground
 28—Measurement of length from the elbow-joint to the nether end (condyle) of the styloid-bone
 29—Measurement of the length from the olecranon to the most prominent point of the pisiform bone
 30—Distance of the most prominent point of the pisiform bone from the middle of the pastern joint
 31—Length of the fetlock
 32—Length of the toe-joints
 33—Diameter of the depth of the forearm
 34—Diameter of the depth of the carpus
 35—Diameter of the depth of the meta-tarsus
 36—Diameter of the depth of the pastern joint.
 37—Diameter of the depth in the middle of the fetlock
 38—Transverse diameter or breadth of the forearm
 39—Diameter of breadth or transverse diameter of the forearm just above the carpus
 40—Greatest breadth of the carpus
 41—Breadth, transverse diameter of the middle of the metacarpus
 42—Breadth of the fetlock joint
 43—Breadth of the middle of the fetlock
 44—Greatest breadth of the coronet ridge of the hoof

45—Greatest breadth of the hoof at the bearing ridge of the wall of the hoof
 46—Vertical distance of the patella from the ground
 47—Distance of the patella from the inner condyle of the tibia
 48—Vertical distance of the tuber calcanei from the ground
 49—Length of the fetlock
 50—Length of the toe part of the wall of the hoof
 51—Diameter of the depth of the leg
 52—Diameter of the depth of the lower leg
 53—Greatest depth diameter of the tarsus
 54—Diameter of the depth of the middle of the cannon
 55—Diameter of the depth of the fetlock joint
 56—Diameter of the depth of the middle of the fetlock
 57—Transverse diameter of the most prominent parts of both upper thighs
 58—Breadth, transverse diameter of the lower leg
 59—Breadth, transverse diameter of the lower leg
 60—Breadth of the tarsus
 61—Middle breadth of the hind meta-tarsus
 62—Breadth of the hind fetlock joint
 63—Middle breadth of the hind fetlock
 64—Breadth of the upper coronet ridge of the hind hoof
 65—Breadth of the bearing edge of the hind foot

Directions of the hair tracts

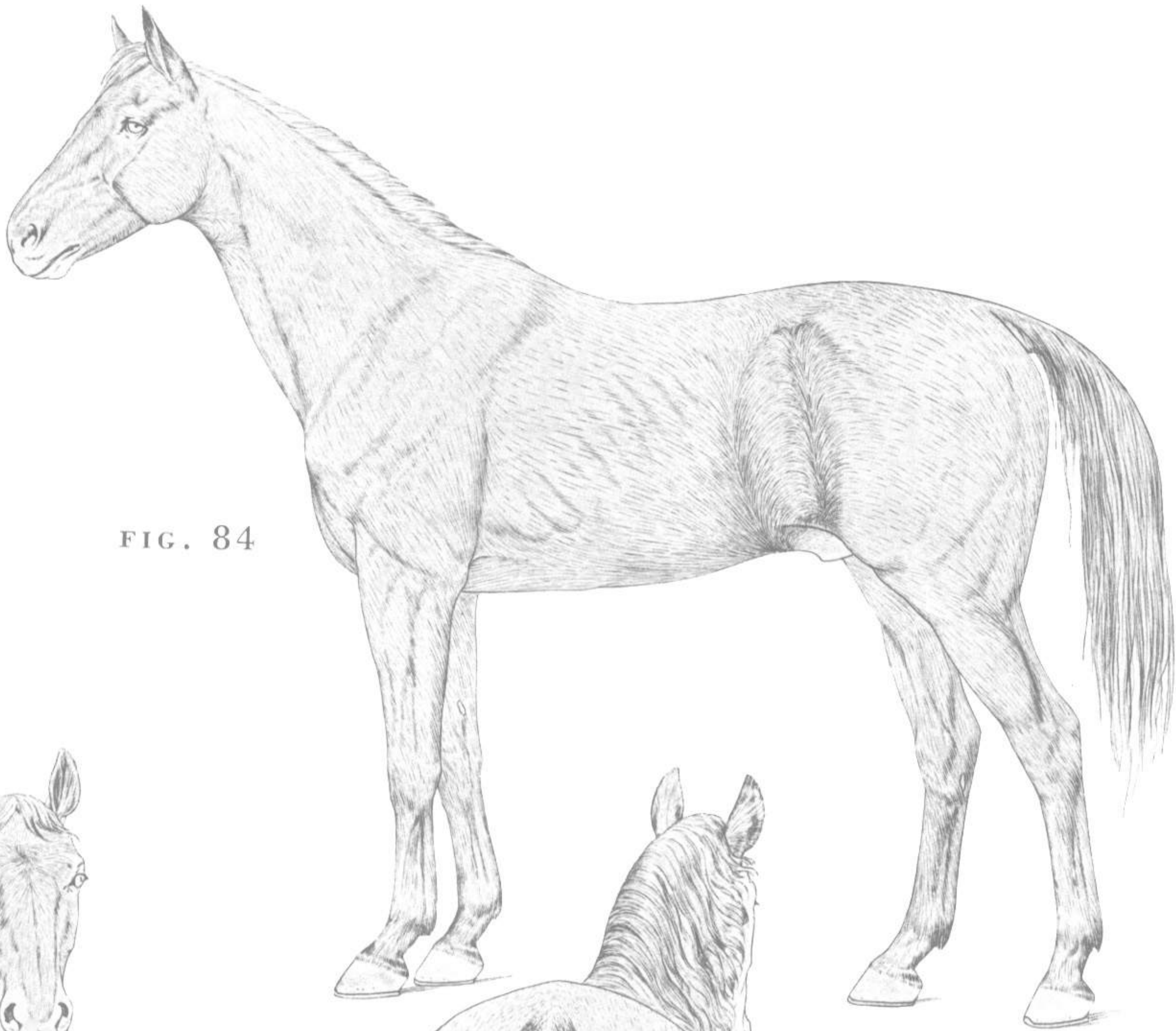


FIG. 84

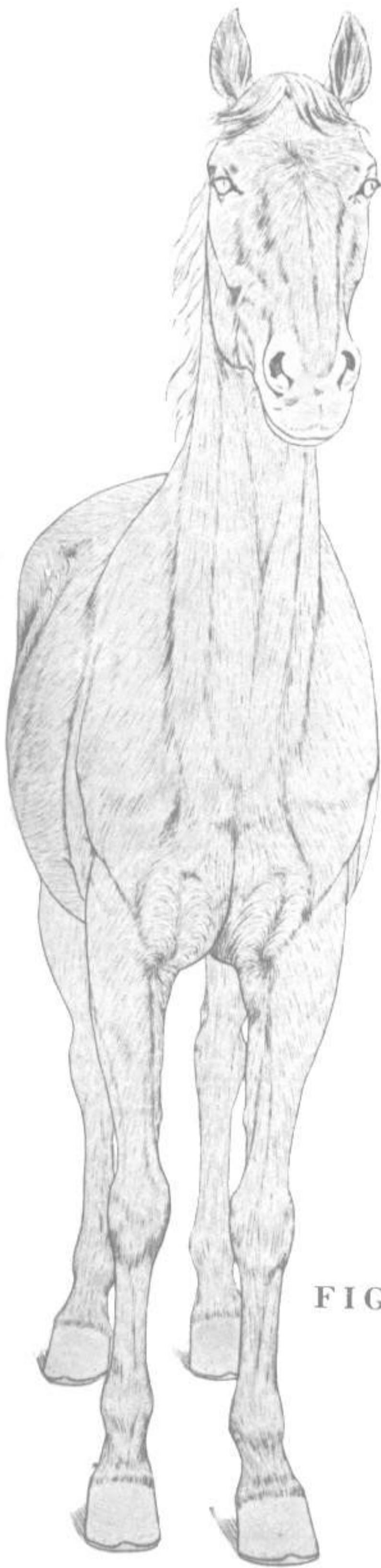


FIG. 85

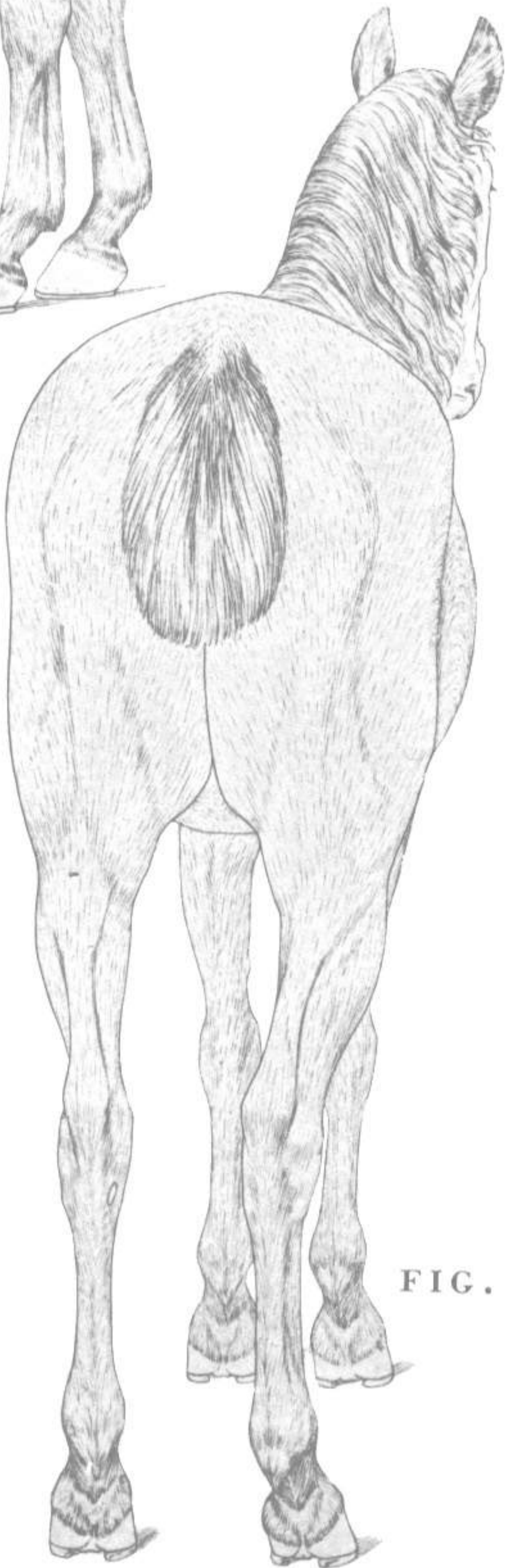


FIG. 86

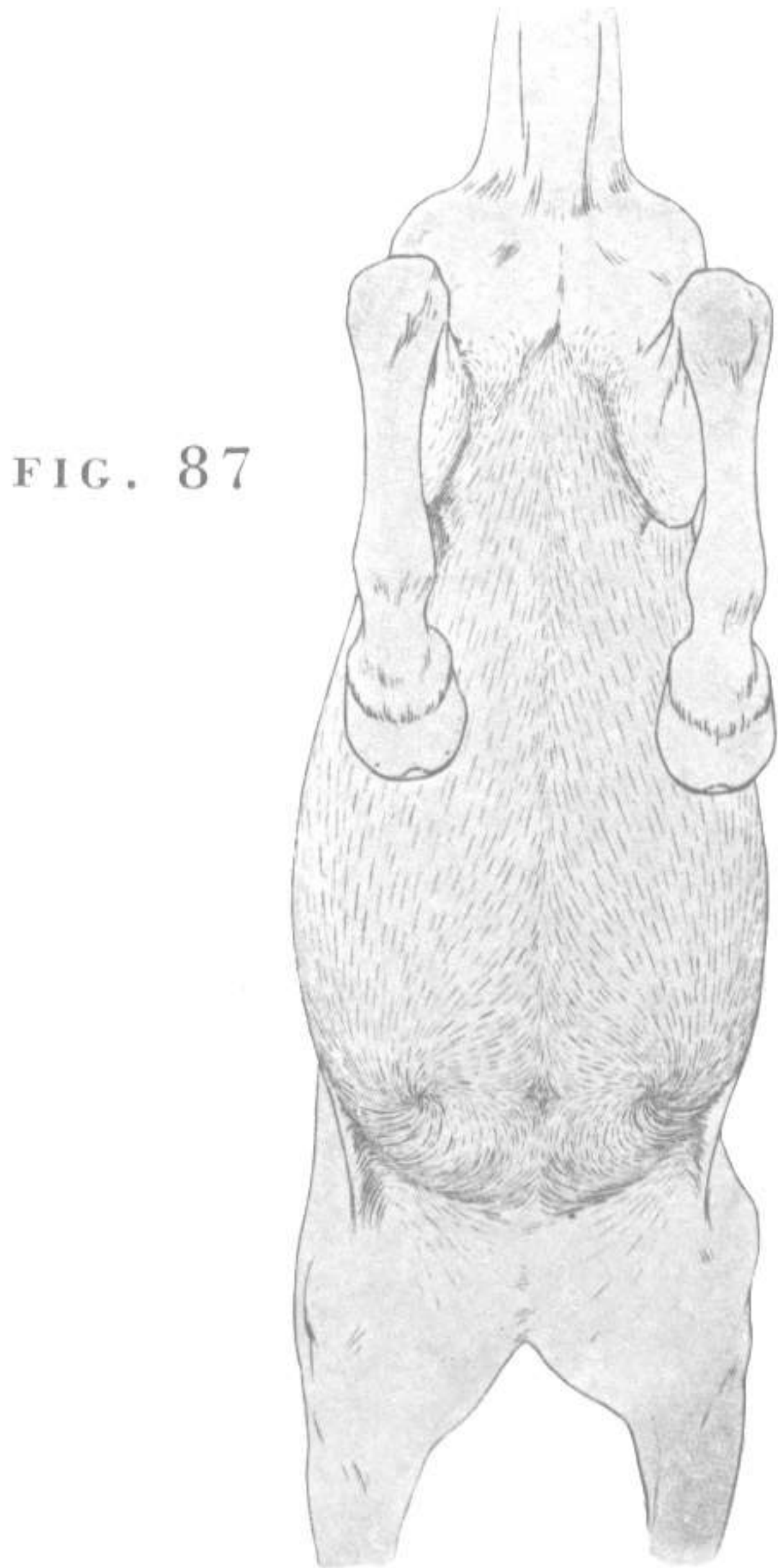
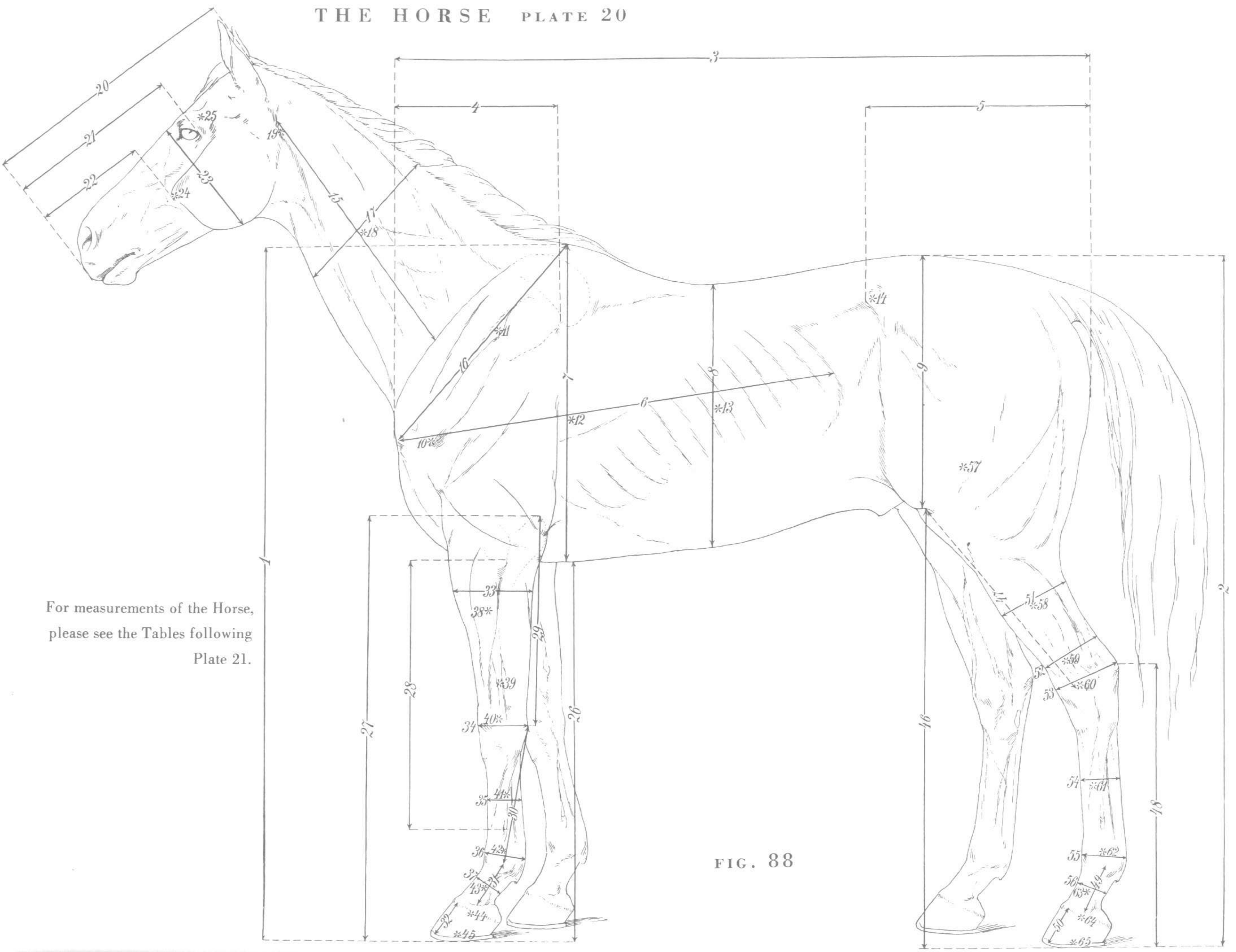
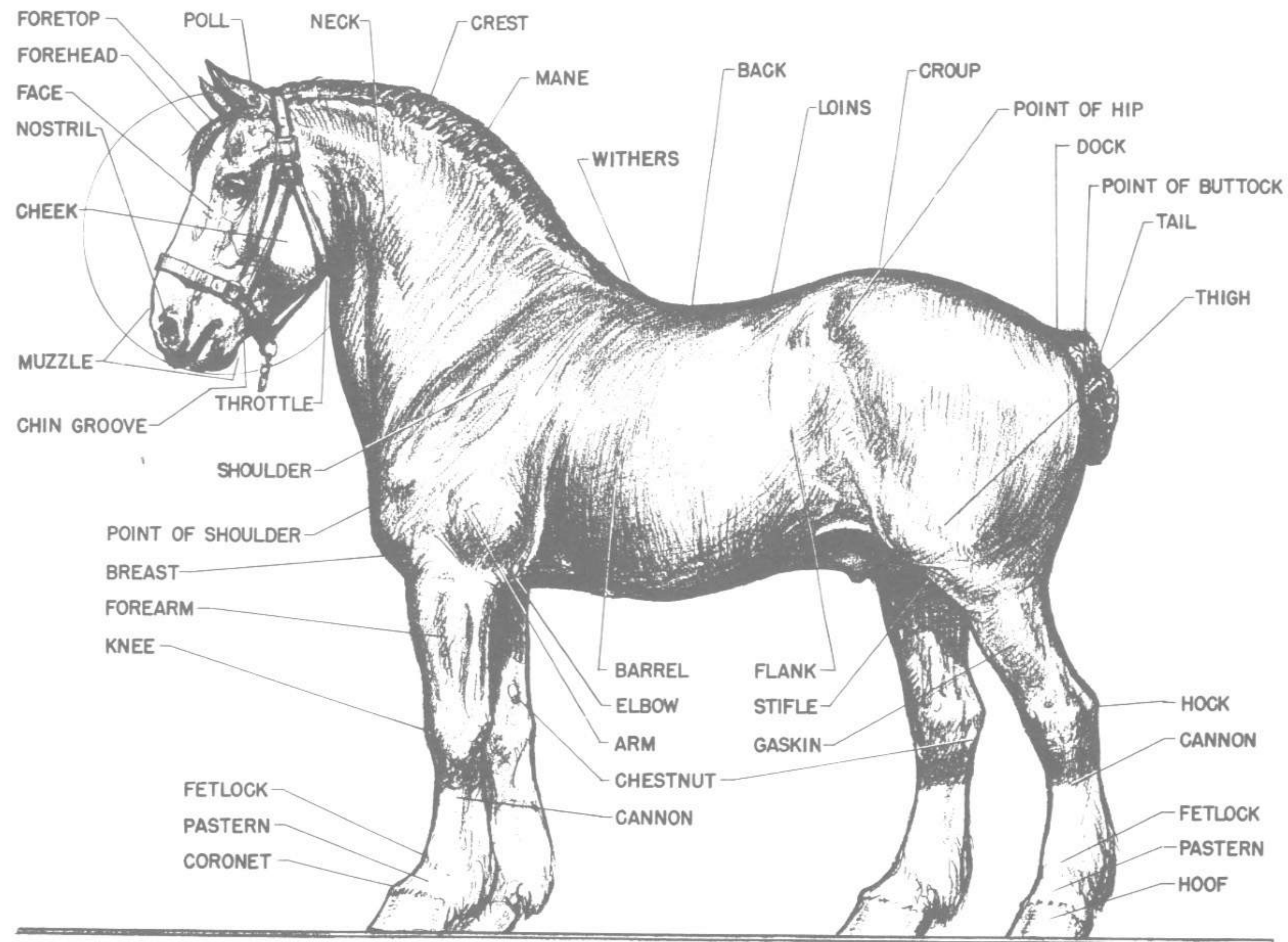


FIG. 87



For measurements of the Horse,
please see the Tables following
Plate 21.

FIG. 88



The Points of the Horse. This is a 17 hand (68 inch) Clydesdale stallion. His head is 28 inches long.

These Tables refer to Plate 20.	Measures of height		Measures of lengths of trunk				Measures of height of trunk			Transverse diameter of the trunk					Length of neck	Height of neck		
	1	2	3	4	5	6	7	8	9	10	11	12	13	14		15	16	17
English riding horse 12 year old gelding	63 ¹¹ / ₁₆	61½	67 ¹³ / ₁₆	15	21 ⁷ / ₁₆	42 ⁷ / ₈	29 ¹ / ₈	25¾	24	17 ⁷ / ₈	12 ⁹ / ₁₆	18 ¹ / ₈	24 ⁹ / ₁₆	19 ⁴ / ₁₆	26	26	15 ¹⁵ / ₁₆	
English half-bred inclination to thoroughbred	62½	61¾	63 ⁵ / ₁₆	13 ³ / ₈	19½	37 ¹⁵ / ₁₆	29½	25¾	22 ¹ / ₁₆	15	10¼	14 ³ / ₈	21 ¹ / ₁₆	18½	24¾	24¾	12¾	
English thoroughbred stallion 10 year old race horse	62½	62¾	62 ¹⁵ / ₁₆	15 ³ / ₈	19¼	38 ¹ / ₈	27 ³ / ₁₆	23 ¹³ / ₁₆	21 ⁷ / ₈	17 ⁵ / ₁₆	11 ⁷ / ₁₆	15 ¹⁵ / ₁₆	21 ¹ / ₁₆	17 ¹¹ / ₁₆	24 ³ / ₈	22 ¹³ / ₁₆	14	
English thoroughbred mare 9 year old race horse	63 ¹ / ₈	63 ¹ / ₈	64 ¹ / ₈	13 ⁹ / ₁₆	20 ¹ / ₁₆	40 ¹ / ₈	30 ¹ / ₈	26	22 ¹ / ₁₆	15 ³ / ₁₆	10¼	14 ⁹ / ₁₆	20 ⁷ / ₈	17 ¹¹ / ₁₆	26	25 ³ / ₁₆	12¾	
English Shire stallion	63 ⁵ / ₁₆	62 ⁵ / ₁₆	68 ¹³ / ₁₆	17 ¹ / ₈	21 ⁷ / ₁₆	43 ¹ / ₁₆	31 ⁷ / ₈	28 ¹⁵ / ₁₆	23 ¹³ / ₁₆	20 ⁷ / ₈	16 ¹ / ₈	22 ⁷ / ₁₆	27¾	20 ⁷ / ₈	23 ⁵ / ₈	28 ⁵ / ₁₆	18 ¹¹ / ₁₆	
Belgian mare—5 years	63 ¹⁴ / ₁₆	63 ¹¹ / ₁₆	66 ⁷ / ₁₆	16½	18 ¹¹ / ₁₆	41 ⁵ / ₁₆	32 ⁷ / ₈	28 ⁵ / ₁₆	24	21 ⁷ / ₁₆	14 ³ / ₁₆	20 ⁷ / ₈	26¾	21¼	23 ³ / ₁₆	26	18½	
Belgian gelding—5 years	62½	63 ⁵ / ₁₆	66 ⁷ / ₁₆	16½	20½	37¾	31 ¹ / ₁₆	26 ³ / ₈	23 ⁵ / ₈	19¼	14	18 ⁵ / ₁₆	25 ⁹ / ₁₆	20 ⁷ / ₈	23 ³ / ₁₆	24 ⁹ / ₁₆	16¾	

	Transverse diameter of neck		Head lengths			Head height	Breadth diameters		Measures of length of fore limb						
	18	19	20	21	22	23	24	25	26	27	28	29	30	31	32
<i>English riding horse 12 year old gelding</i>	7 ⁵ / ₁₆	7 ¹ / ₈	26	16 ¹ / ₈	9 ⁷ / ₈	11 ¹³ / ₁₆	7 ¹ / ₈	9 ¹ / ₄	34 ⁵ / ₈	39 ¹⁵ / ₁₆	23 ¹³ / ₁₆	19 ⁷ / ₈	12 ⁹ / ₁₆	4 ⁹ / ₁₆	3 ¹⁵ / ₁₆
<i>English half-bred inclination to thoroughbred</i>	5 ¹⁵ / ₁₆	6 ⁵ / ₁₆	25 ³ / ₈	16 ¹ / ₂	10 ¹ / ₄	11	6 ⁷ / ₈	8 ¹¹ / ₁₆	33 ¹ / ₁₆	38 ⁹ / ₁₆	24 ³ / ₈	20 ⁷ / ₁₆	12 ³ / ₈	4 ⁹ / ₁₆	4 ⁹ / ₁₆
<i>English thoroughbred stallion 10 year old race horse</i>	7 ¹ / ₈	6 ¹¹ / ₁₆	24 ⁹ / ₁₆	15 ³ / ₄	9 ⁷ / ₈	11	6 ¹¹ / ₁₆	8 ⁷ / ₈	35 ³ / ₈	38 ¹⁵ / ₁₆	24 ³ / ₄	19 ¹ / ₄	13 ³ / ₈	5 ¹ / ₈	4 ¹ / ₈
<i>English thoroughbred mare 9 year old race horse</i>	5 ¹⁵ / ₁₆	6 ¹¹ / ₁₆	25 ⁹ / ₁₆	16 ¹⁵ / ₁₆	10 ¹ / ₄	11 ⁵ / ₈	6 ⁷ / ₈	8 ⁷ / ₈	33 ¹ / ₁₆	38 ¹⁵ / ₁₆	24	20 ¹ / ₁₆	12 ⁹ / ₁₆	5 ¹ / ₈	4 ³ / ₄
<i>English Shire stallion</i>	8 ⁷ / ₈	8 ¹ / ₁₆	27 ⁹ / ₁₆	17 ¹¹ / ₁₆	11	13	7 ¹ / ₂	9 ⁷ / ₈	31 ¹ / ₂	37 ³ / ₄	23 ³ / ₁₆	18 ¹ / ₂	11 ⁷ / ₁₆	3 ¹⁵ / ₁₆	5 ¹ / ₂
<i>Belgian mare—5 years</i>	7 ⁷ / ₈	6 ¹¹ / ₁₆	28 ³ / ₄	18 ¹ / ₈	11 ⁷ / ₁₆	13 ³ / ₈	8	10 ³ / ₈	31 ¹ / ₁₆	39 ³ / ₈	23 ⁹ / ₁₆	18 ¹ / ₈	12 ⁹ / ₁₆	3 ³ / ₄	4 ¹⁵ / ₁₆
<i>Belgian gelding—5 years</i>	7 ⁷ / ₈	7 ³ / ₈	28 ⁵ / ₁₆	17 ¹¹ / ₁₆	11	13 ³ / ₁₆	7 ⁷ / ₈	9 ⁵ / ₈	31 ¹ / ₂	39 ³ / ₄	23 ⁹ / ₁₆	19 ¹¹ / ₁₆	12 ⁹ / ₁₆	3 ³ / ₄	5 ¹ / ₂

	Diameters of fore limb					Transverse diameters or thickness through leg at starred point								Measures of length of the hind limb				
	33	34	35	36	37	38	39	40	41	42	43	44	45	46	47	48	49	50
English riding horse 12 year old gelding	7½	4¾	3¼	3⅞	2¾	4⅝	2¾	4⅝ ₁₆	2	3⅛	2⅜	4⅝ ₁₆	5½	39⅞ ₁₆	20½	25	4⅝ ₁₆	4⅛
English half-bred inclination to thoroughbred	5 ¹⁵ / ₁₆	4⅛	2¾	2¾	2 ³ / ₁₆	3 ¹⁵ / ₁₆	2⅜	3 ¹⁵ / ₁₆	1 ⁹ / ₁₆	2¾	2	4⅛	4 ¹⁵ / ₁₆	38 ⁹ / ₁₆	20½	24 ³ / ₁₆	5⅛	4¾
English thoroughbred stallion 10 year old race horse	6 ¹¹ / ₁₆	4¼	2 ¹³ / ₁₆	3 ⁹ / ₁₆	2⅜	3 ¹⁵ / ₁₆	2⅜	4⅛	1 ⁹ / ₁₆	2¾	2	3¾	4⅛	40½	20½	25 ⁹ / ₁₆	4¾	4¾
English thoroughbred mare 9 year old race horse	6 ⁵ / ₁₆	4⅛	2 ¹⁵ / ₁₆	3⅜	2 ⁵ / ₁₆	3¾	2⅜	3¾	1 ⁹ / ₁₆	2¾	1⅞	3 ¹⁵ / ₁₆	4 ⁵ / ₁₆	40½	20¼	25 ³ / ₁₆	5⅛	4¾
English Shire stallion	8⅞	5½	3 ⁹ / ₁₆	4⅛	3 ³ / ₁₆	4 ⁵ / ₁₆	3¾	5⅛	2⅜	3 ⁹ / ₁₆	2¾	5⅛	6 ⁵ / ₁₆	37⅜	18⅞	25 ⁹ / ₁₆	4	4¾
Belgian mare—5 years	7⅞	4¾	3⅜	3 ¹⁵ / ₁₆	2 ¹⁵ / ₁₆	4 ⁵ / ₁₆	3⅜	4¾	2⅜	3⅜	2¾	5⅛	6 ⁵ / ₁₆	38 ⁹ / ₁₆	18⅞	24 ¹³ / ₁₆	3 ¹⁵ / ₁₆	4¾
Belgian gelding—5 years	7⅞	4 ¹⁵ / ₁₆	3 ⁹ / ₁₆	3¾	2¾	4⅛	3 ⁹ / ₁₆	4¾	2 ³ / ₁₆	3½	2⅜	4¾	6 ⁵ / ₁₆	38 ¹⁵ / ₁₆	19¼	25 ⁹ / ₁₆	3 ¹⁵ / ₁₆	4¾

	Width diameters of hind leg						Transverse diameters or thickness through hind leg at starred points								
	51	52	53	54	55	56	57	58	59	60	61	62	63	64	65
English riding horse 12 year old gelding	6½	5⅓ ₁₆	6⅝ ₁₆	3¾	3⅕ ₁₆	2¾	23	4⅓ ₁₆	3⅜ ₁₆	4½	1¾	3¼	2½	4¾	5⅜
English half-bred inclination to thoroughbred	5Ⅺ ₁₆	5⅛	5½	3⅜ ₁₆	3⅙ ₁₆	3⅜	20Ⅺ ₁₆	3⅕ ₁₆	2¾	3¼	1⅙ ₁₆	2¾	2	4⅛	4⅝ ₁₆
English thoroughbred stallion 10 year old race horse	6½	5Ⅺ ₁₆	5⅞	3⅙ ₁₆	3¾	2⅙ ₁₆	21⅞ ₁₆	4⅝ ₁₆	2¾	3⅕ ₁₆	1⅙ ₁₆	2⅕ ₁₆	2	3¾	4⅛
English thoroughbred mare 9 year old race horse	6⅞	5½	5Ⅺ ₁₆	3¾	3⅕ ₁₆	2⅕ ₁₆	20⅙ ₁₆	4⅛	2¾	3⅕ ₁₆	1⅙ ₁₆	2⅕ ₁₆	2⅜ ₁₆	4	4
English Shire stallion	7½	6Ⅺ ₁₆	7⅝ ₁₆	4⅝ ₁₆	5⅛	3½	24¾	5½	3⅕ ₁₆	5½	2⅜	4⅛	3⅜	5⅛	6½
Belgian mare—5 years	6⅞	6⅝ ₁₆	6Ⅺ ₁₆	3⅕ ₁₆	3⅕ ₁₆	3⅜ ₁₆	24⅙ ₁₆	5½	3⅙ ₁₆	4¾	2⅜	3⅜	2⅜	5⅝ ₁₆	6⅝ ₁₆
Belgian gelding—5 years	6Ⅺ ₁₆	6⅝ ₁₆	6Ⅺ ₁₆	3⅕ ₁₆	3⅕ ₁₆	2¾	22Ⅺ ₁₆	4⅕ ₁₆	3⅙ ₁₆	4⅓ ₁₆	2⅜ ₁₆	3¾	2⅜	5	6½

The Dog

THE DOG - PLATES 1 2 3 4 5 6 7 8

FIGURES 1 2 3 4 5 6 7 8 9 10 11 12 13

a, a'—*M. trapezius*
 b—*Inferior M. levator anguli scapulae*
 c, c''—*M. brachiocephalicus s. cleidomastoideus*
 c'—*Mastoid portion of the sterno-cleid-mastoid muscle*
 c'''—*Tendinous band*
 d—*M. sternomastoideus*
 e, e'—*M. deltoideus*
 f, f'—*M. triceps brachii, f caput longum, f' caput laterale*
 g, g'—*M. pectoralis major s. superficialis*
 h—*M. pectoralis minor s. profundus*
 i—*Thoracic portion of M. serratus anterior*
 i'—*Cervical portion of M. serratus anterior*
 k—*M. latissimus dorsi*
 l—*M. obliquus abdominis externus*
 l'—*Aponeurosis*
 m—*Posterior part of M. serratus posterior*
 m'—*Lumbo-dorsal fascia*
 m''—*Anterior part of M. serratus posterior*
 n—*A small part of origin of M. obliquus abdominis internus*
 o—*M. tensor fasciae latae*
 o'—*Surface of thigh*
 o''—*M. gluteus maximus s. superficialis*
 p—*M. gluteus medius*
 q—*M. biceps femoris*
 r—*M. semitendinosus*
 s, t—*Levators of the tail*

u—*Abductor of the tail*
 v—*M. semimembranosus*
 w—*M. gracilis*
 x—*Levator of the auricle*
 x'—*M. occipitalis*
 y—*M. obturator internus*
 z—*M. supraspinatus*
 z'—*A small part of the M. infraspinatus*
 1H—*1st cervical vertebra (Atlas)*
 7H—*Last (7th) cervical vertebra*
 1R—*1st rib*
 1R'—*1st thoracic (dorsal) vertebra*
 6R—*6th rib*
 12R—*12th thoracic (dorsal) vertebra*
 13R—*13th rib*
 1L—*1st lumbar vertebra*
 7L—*7th lumbar vertebra*
 K—*Sacrum*
 1S—*1st caudal vertebra*
 *—*Ala of the atlas*
 1—*Scapula*
 2—*Spina scapulae*
 3—*Acromion*
 4—*Humerus*
 4'—*Epicondyle*
 5—*Tuberculum majus*
 6—*Rotator*
 7—*Ulna*
 8—*Olecranon*

9—*Radius*
 10—*Carpus*
 11—*Os pisiforme*
 12—*Metacarpus*
 13—*Phalanges manus*
 14—*Sternum*
 14'—*Manubrium sterni*
 15—*Ossa pelvis*
 16—*Tuber coxae*
 17—*Tuber sacrale*
 18—*Os femoris*
 19—*Trochanter major*
 20—*Patella*
 21—*Tibia*
 21'—*External condyle of the tibia*
 22—*Tarsus*
 23—*Fibula*
 24—*Tuber calcanei*
 25—*Metatarsus*
 26—*Phalanges pedis*
 27—*Os parietale*
 27'—*Cervical crest of os occipitale*
 28, 28'—*M. quadriceps femoris*
 29—*M. semimembranosus*
 30—*Mm. gastrocnemii*
 31—*M. sterno-hyoideus*
 32—*V. jugularis*
 33—*Head part of M. rhomboideus*
 34—*M. rhomboideus*

35—*M. spinalis et semispinalis dorsi*
36—*M. longissimus dorsi*
37—*M. iliocostalis*
38—*Part of origin of M. teres major*
39—*M. splenius*

40—*M. intercostalis*
41—*Lig. tuberoso- et spinosacrum*
42—*Popliteal lymphatic gland*
43—*M. transversus abdominis*

44—*M. rectus abdominis*
45—*Depressor of the tail*
46—*Anterior part of M. sartorius*
48—*A part of M. scalenus*

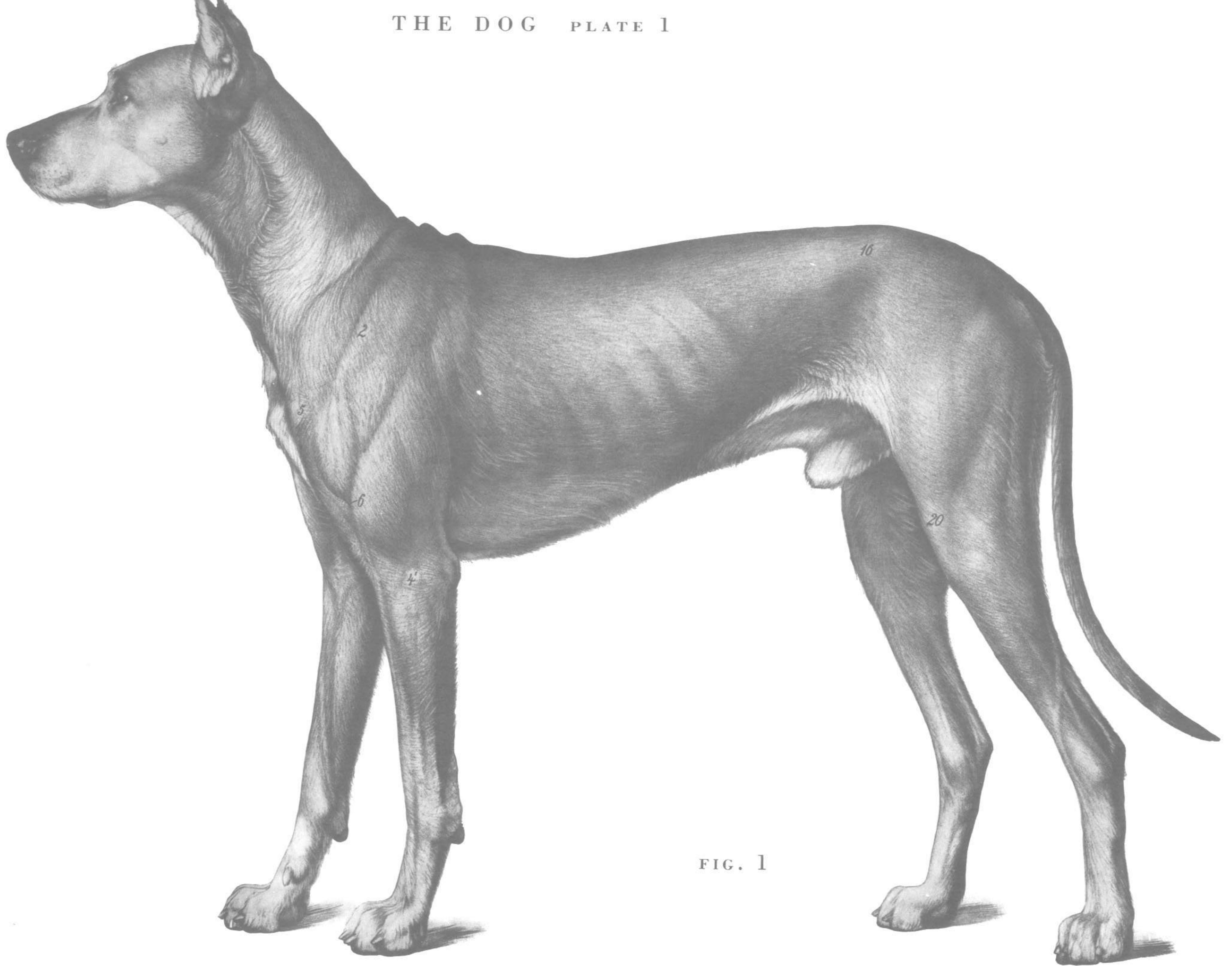


FIG. 1

THE DOG PLATE 2

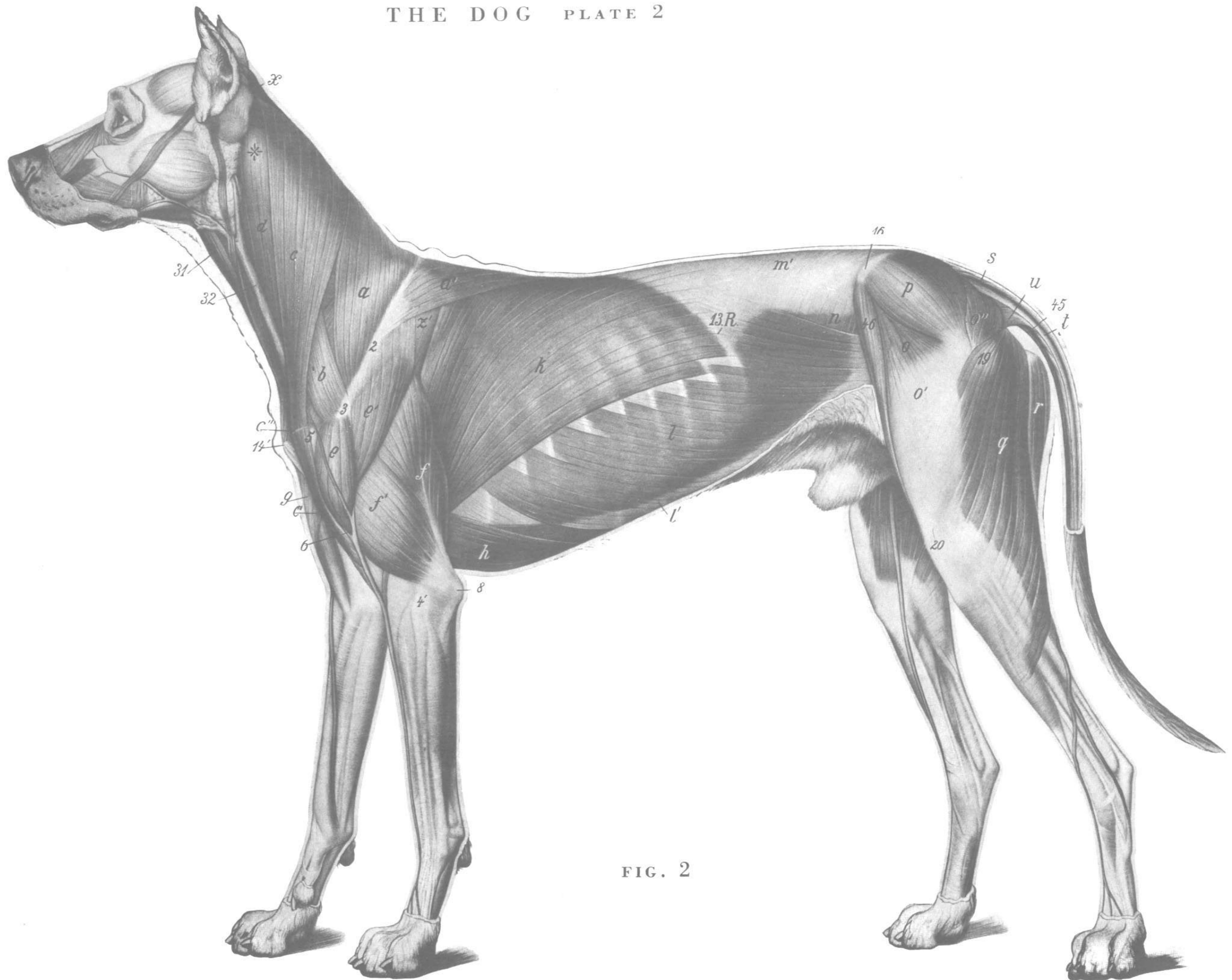


FIG. 2

THE DOG PLATE 3

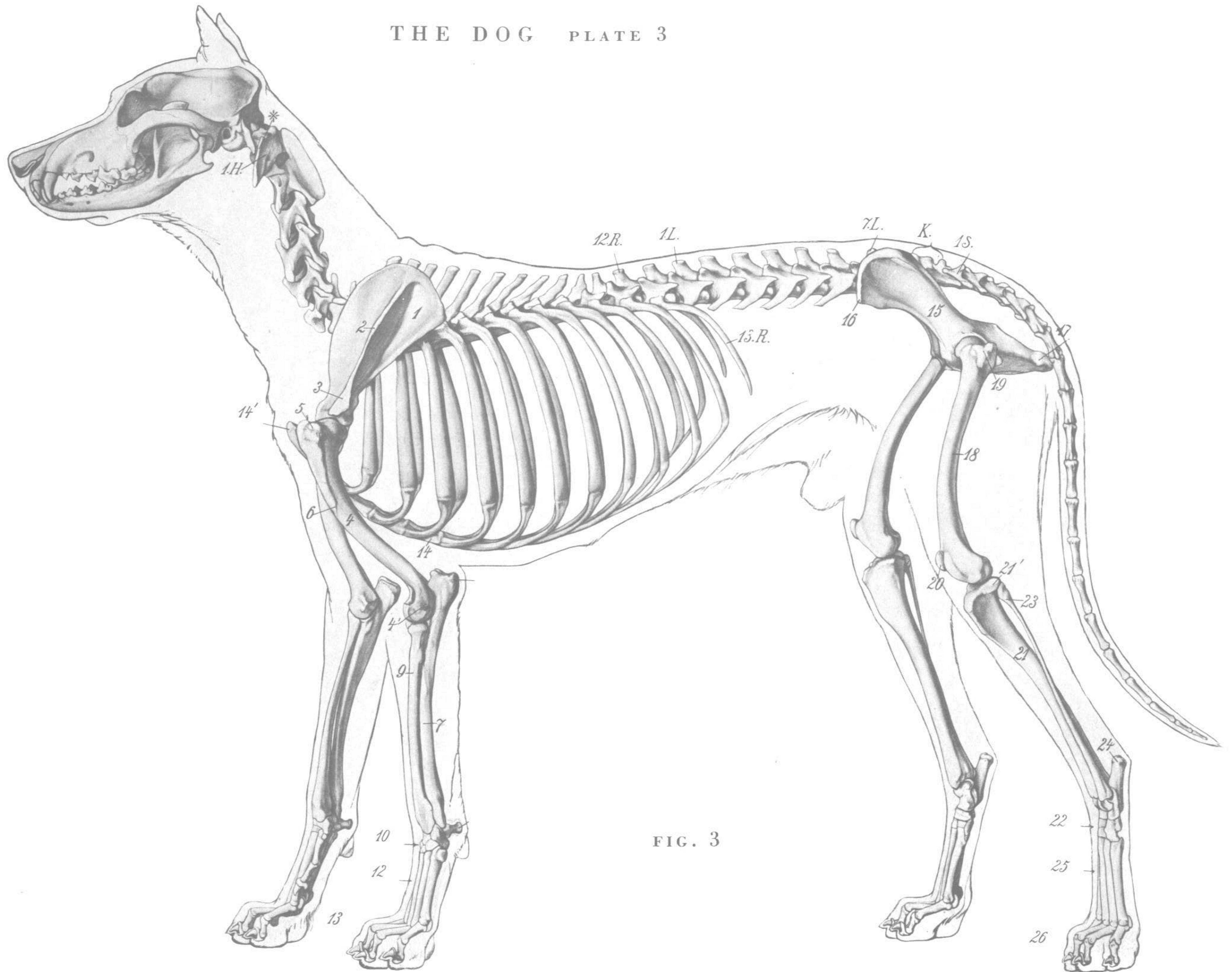


FIG. 3

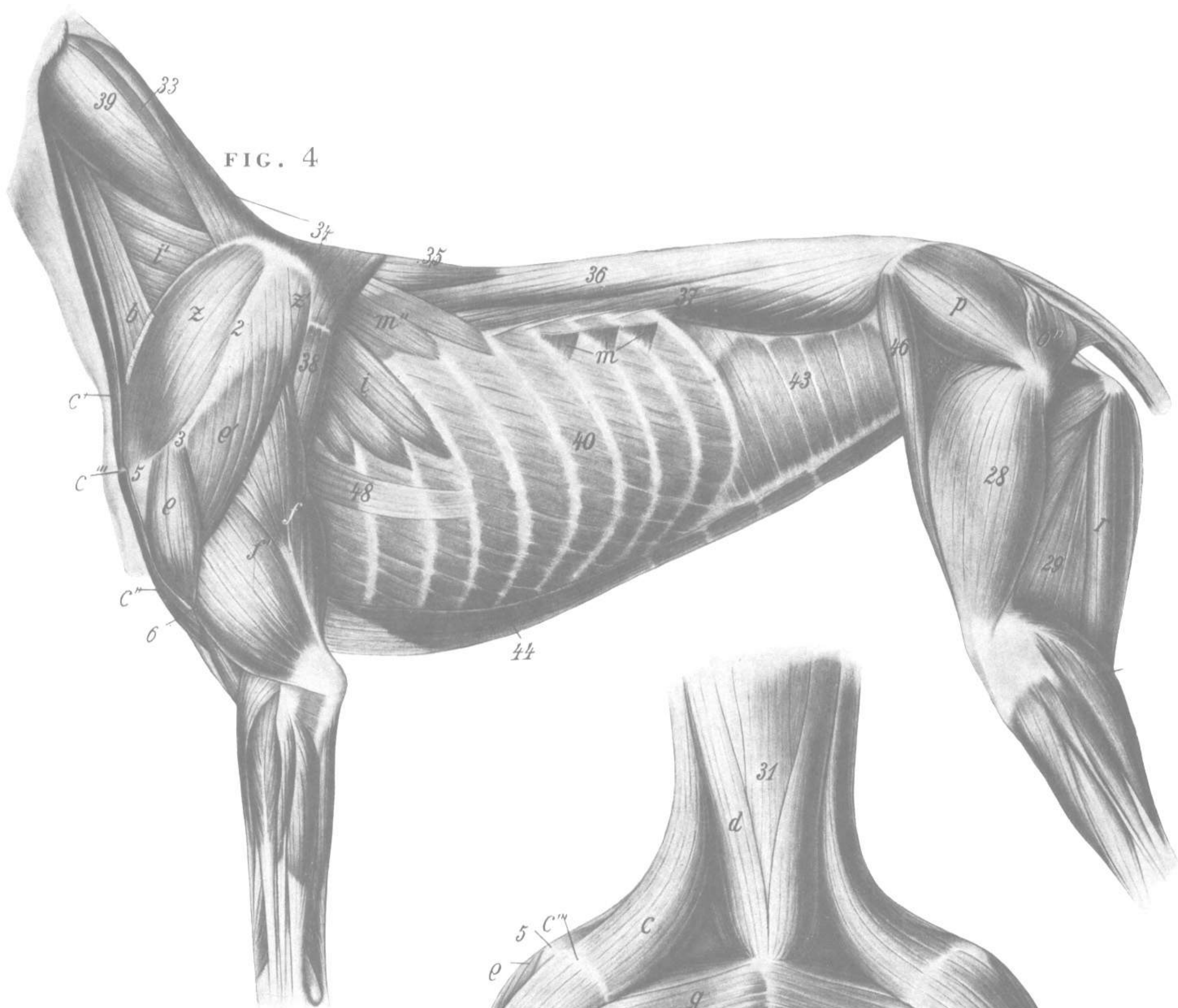


FIG. 5

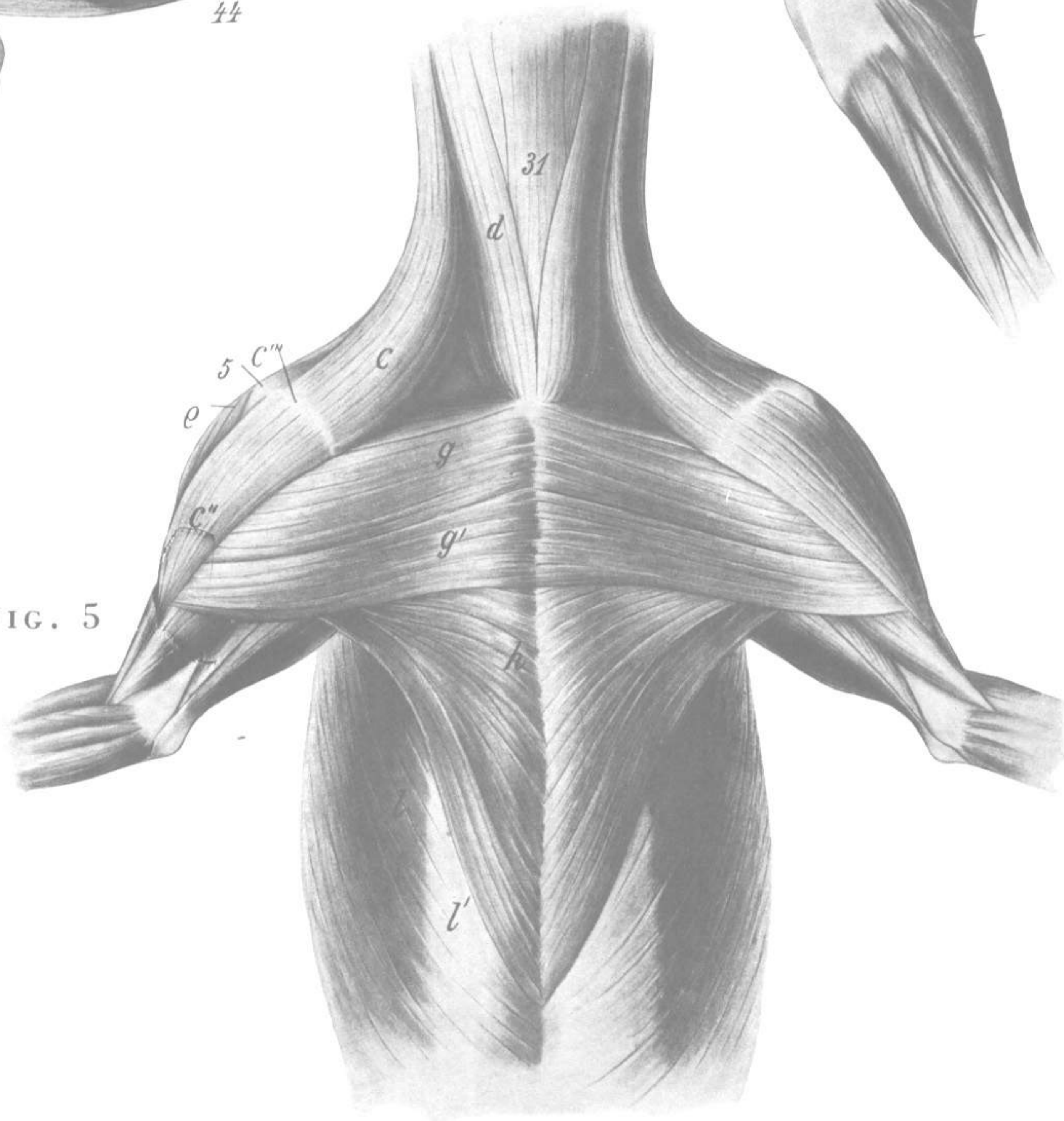


FIG. 6

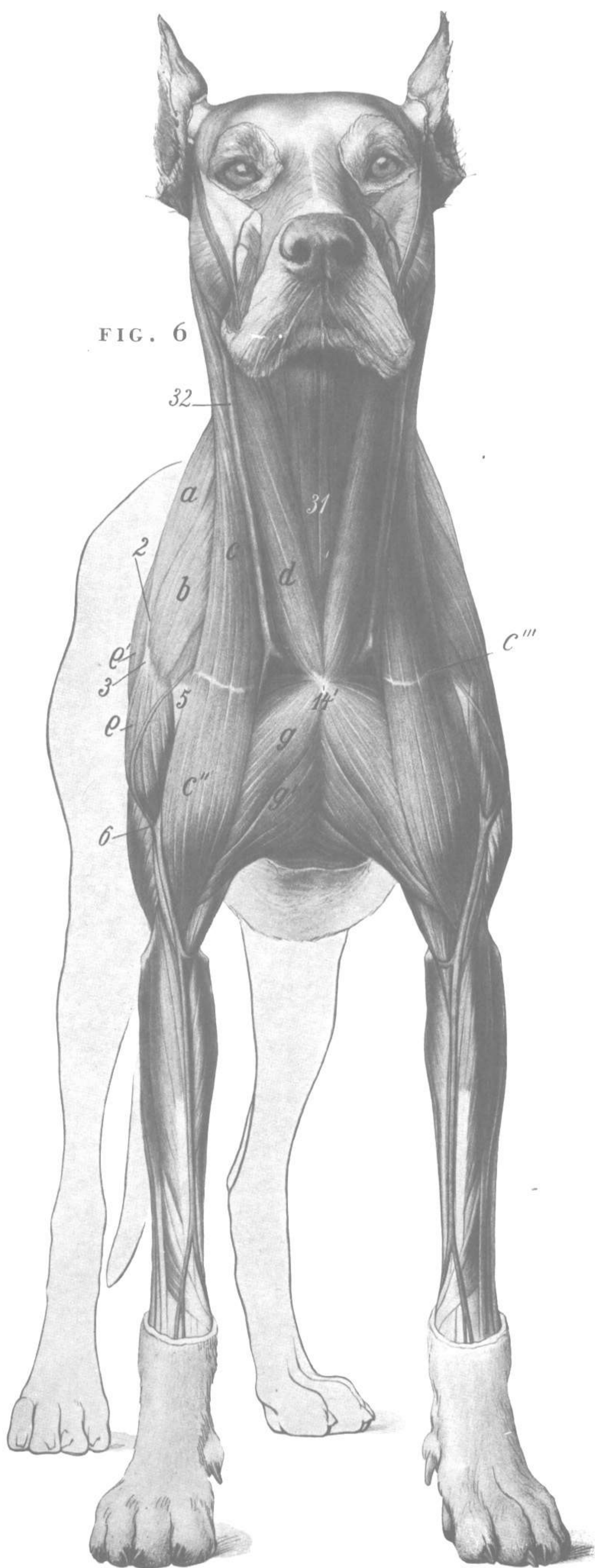


FIG. 7

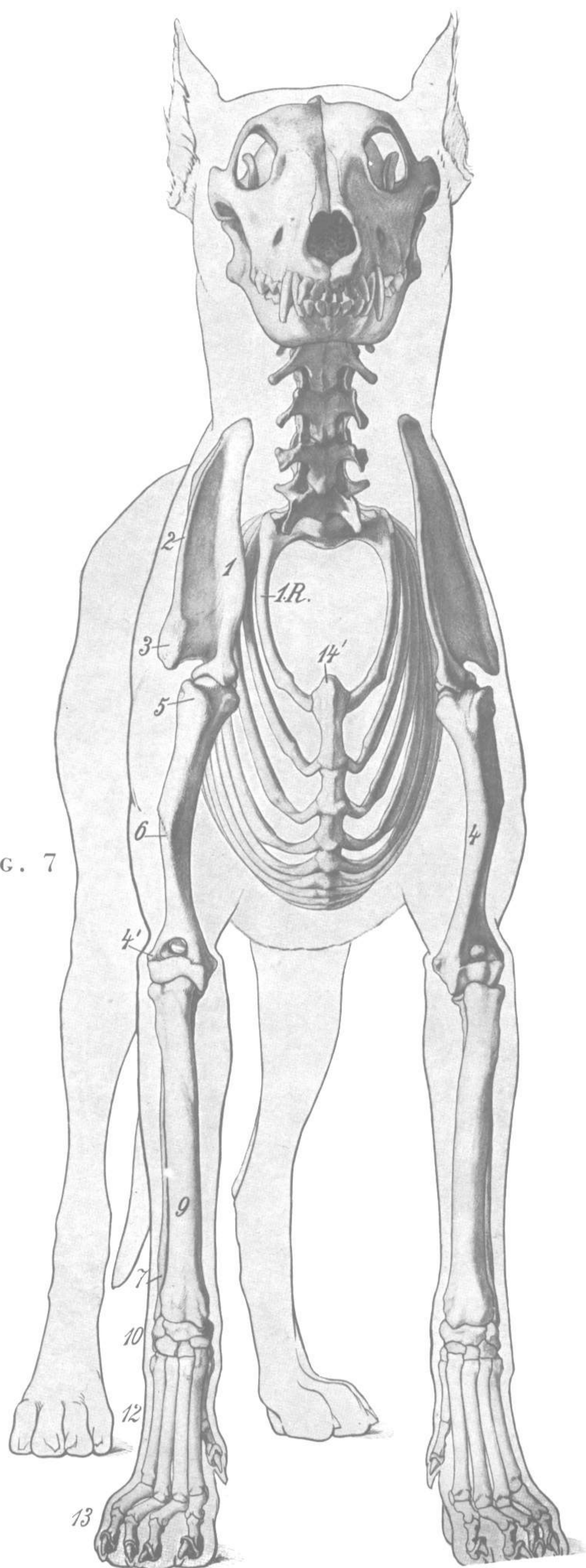


FIG. 8

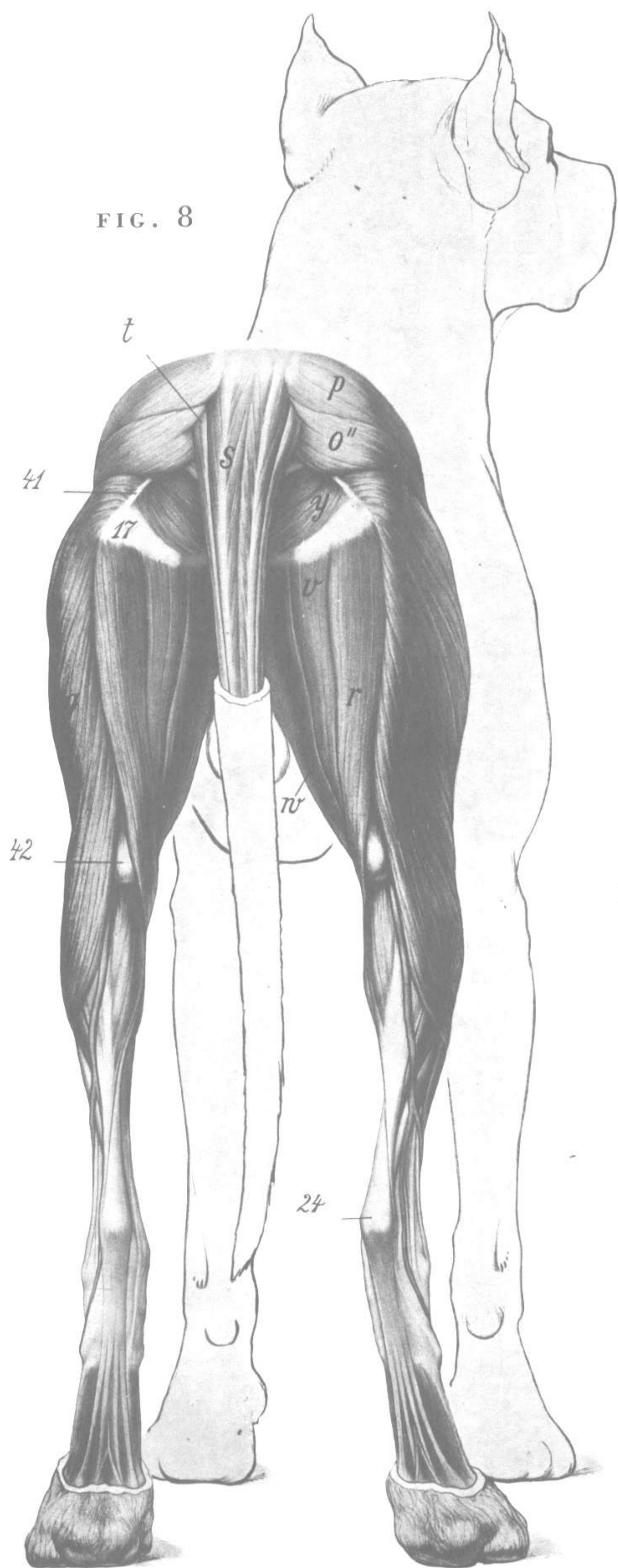
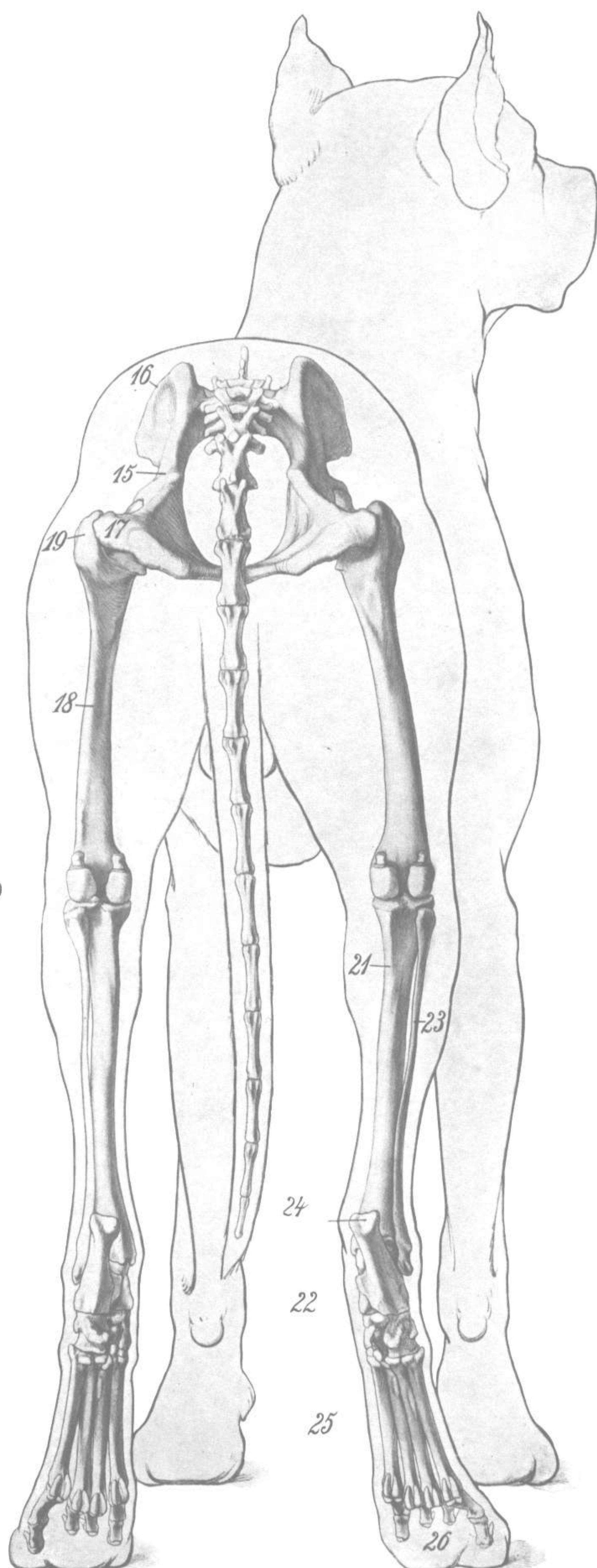


FIG. 9



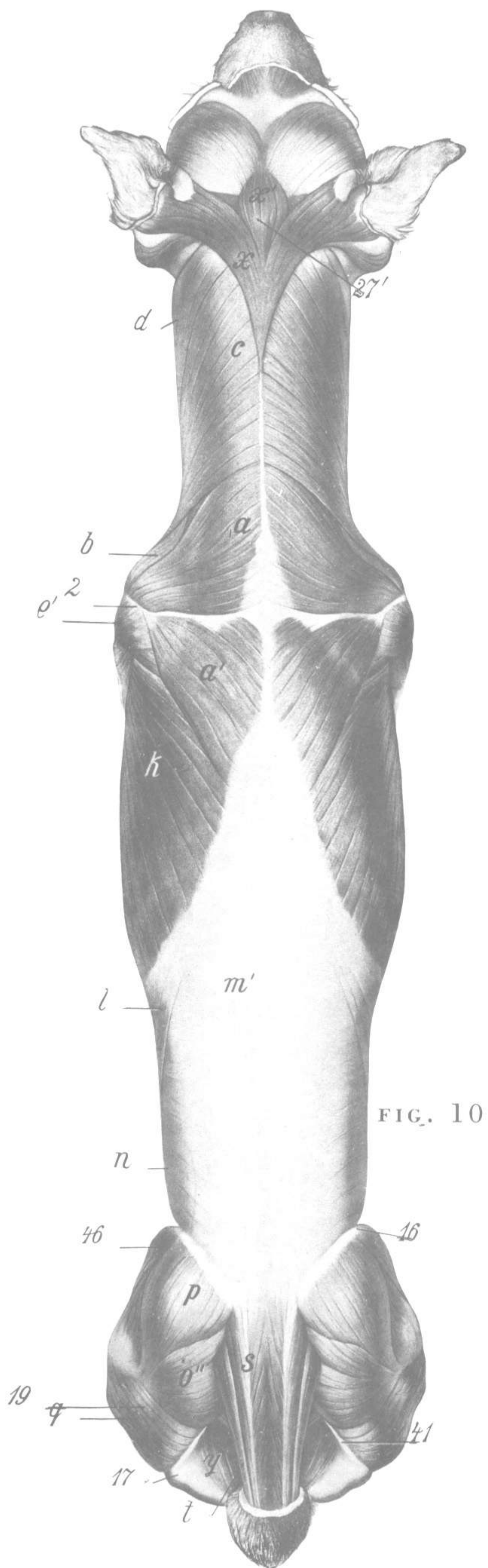


FIG. 10

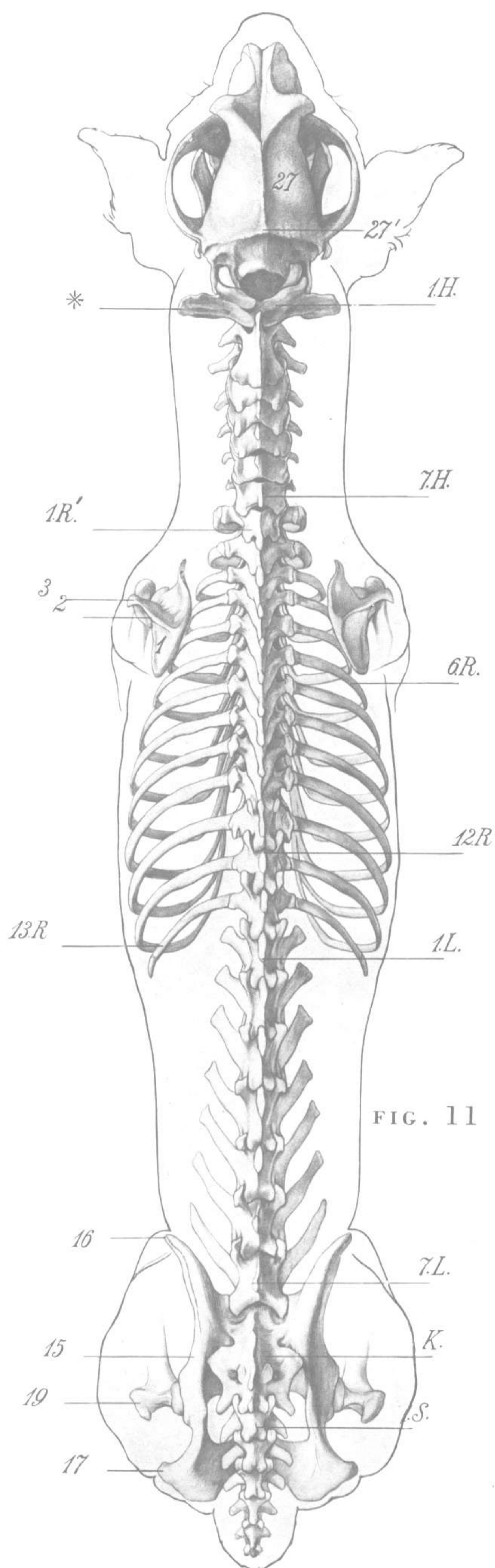


FIG. 11

FIG. 12

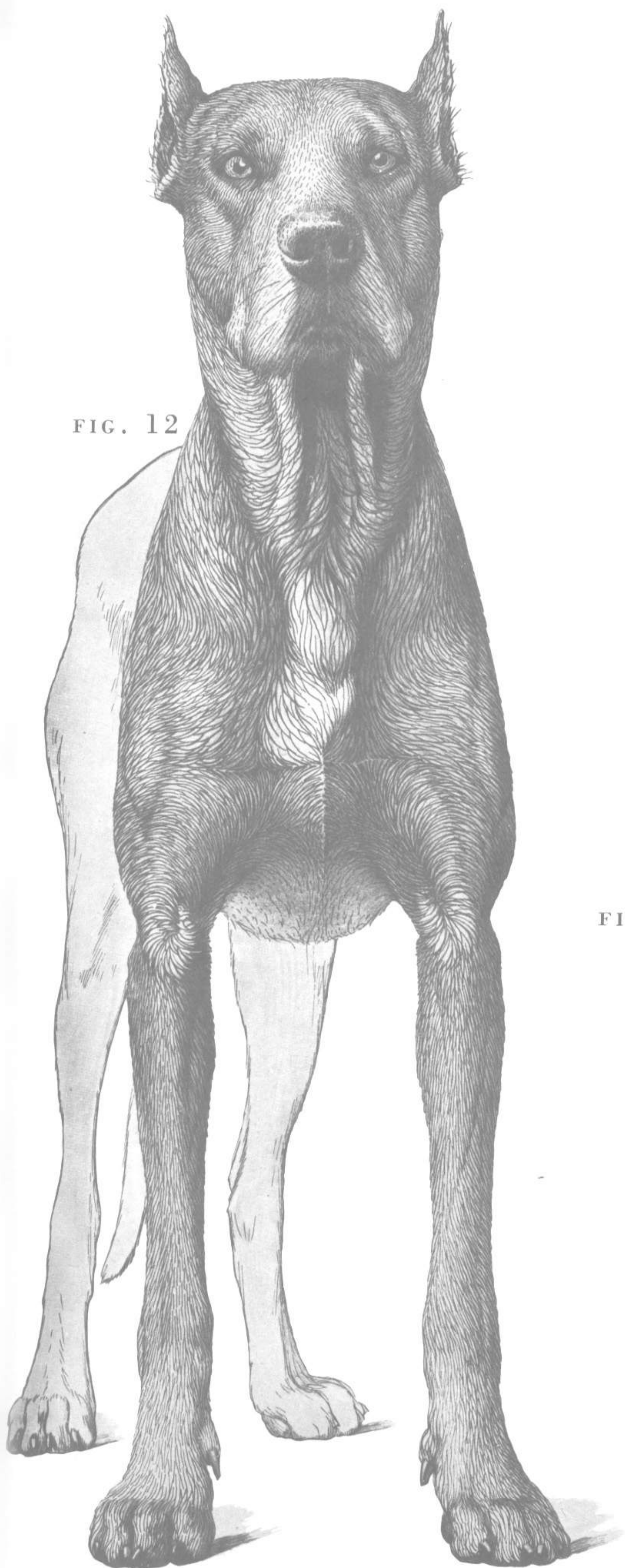
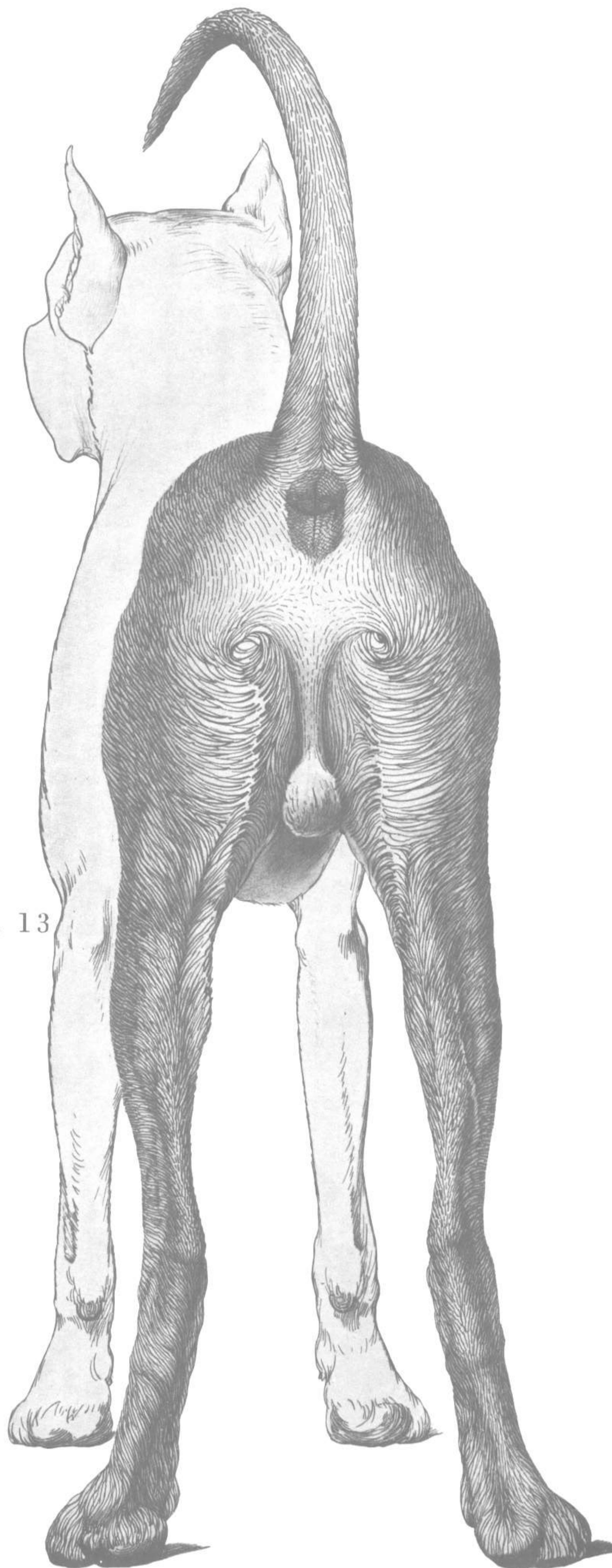


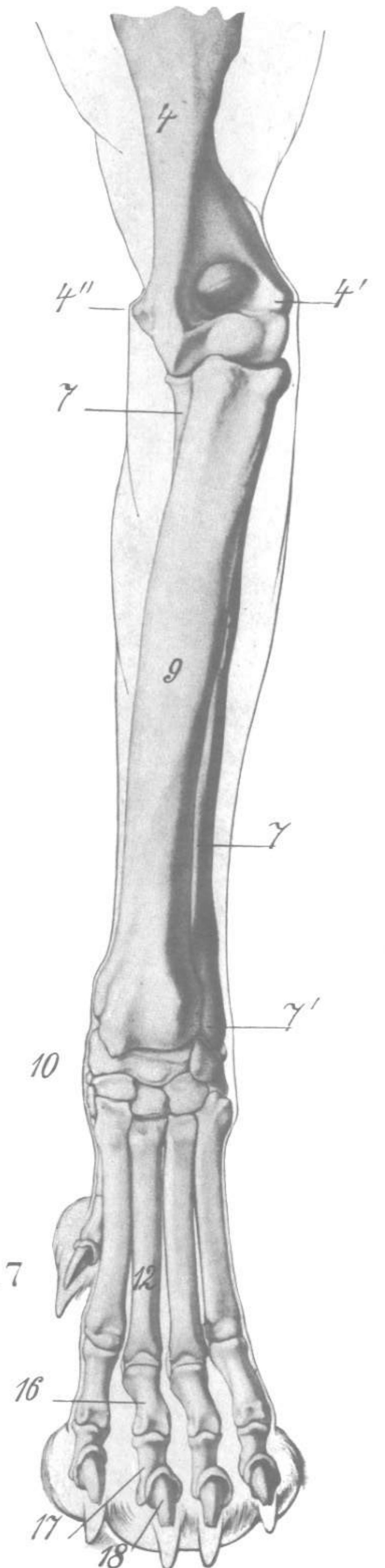
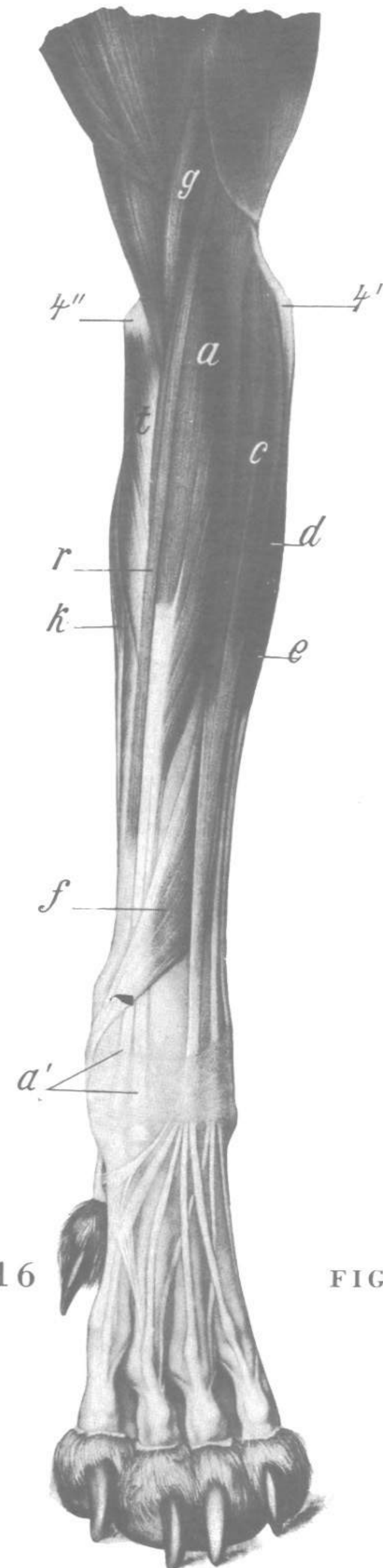
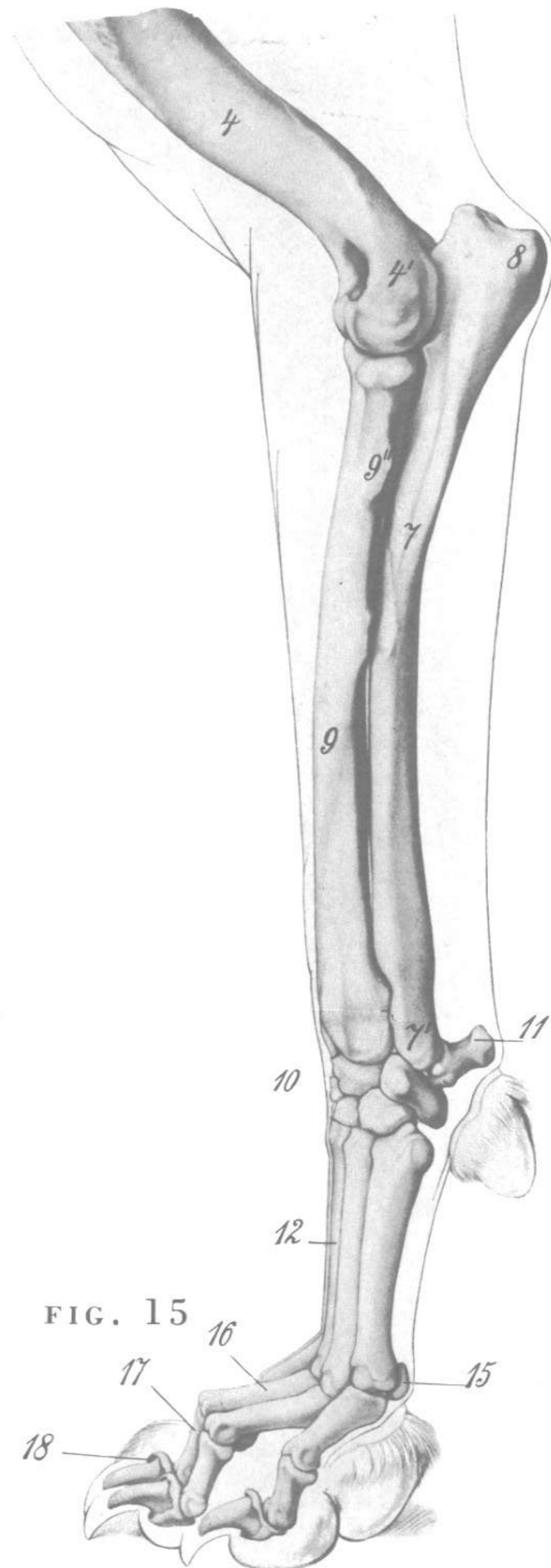
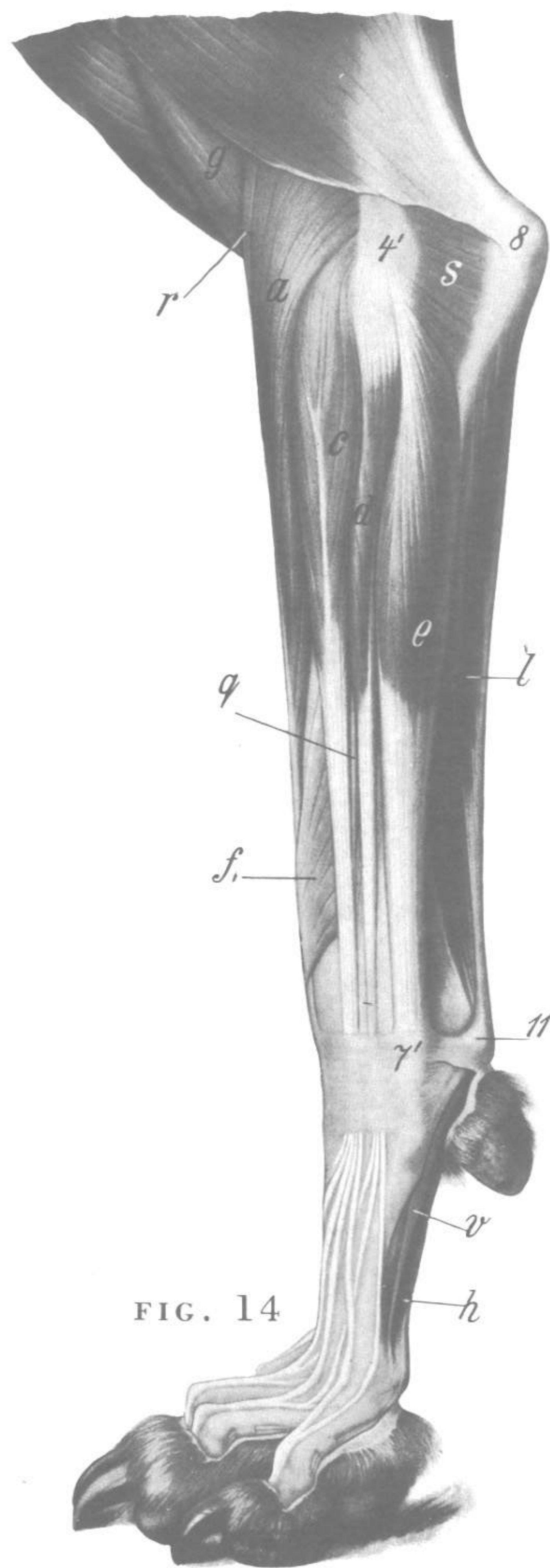
FIG. 13



THE DOG - PLATES 9 10 11

FIGURES 14 15 16 17 18 19 20 21 22 23 24 25 26

- | | | |
|--|---|--|
| A—Plantar ball | m— <i>M. flexor dig. sublimis</i> | 4'—Extensor condyle of humerus |
| B—Digital ball | m'—The four divisions of the lower part of the | 4''—Flexor condyle of humerus |
| B'—Digital ball of the 1st toe | <i>M. flexor dig. sublimis</i> | 7—Ulna |
| C—Carpal ball | o— <i>M. flexor dig. profundus</i> | 7'—Lower end of ulna (external epicondyle) |
| a, a'— <i>M. extensor carpi radialis</i> | o'—The divisions of the lower part of the <i>M.</i> | 8—Olecranon |
| c, c'— <i>M. extensor digitorum communis</i> | <i>flexor dig. profundus</i> | 9—Radius |
| d— <i>M. extensor digiti minimi</i> | q—The thin end tendons of <i>M. extensor pollicis</i> | 9''—Tuberositas radii |
| e— <i>M. extensor carpi ulnaris</i> | <i>longus et indicis proprius</i> | 10—Carpus |
| f— <i>M. abductor pollicis longus</i> | r— <i>M. brachioradialis</i> | 11—Os pisiforme |
| g—End of <i>M. brachialis internus</i> | s— <i>M. anconaeus parvus</i> | 12—Metacarpus |
| g'—End of <i>M. biceps brachii</i> | t— <i>M. pronator teres</i> | 15—Sesamoid bones |
| h, h'— <i>M. interosseus</i> | v— <i>M. abductor digiti V proprius</i> | 16—Phalanx prima |
| k— <i>M. flexor carpi radialis</i> | w—Crural elastic ligament | 17—Phalanx secunda |
| l— <i>M. flexor carpi ulnaris</i> | 4—Humerus | 18—Phalanx tertia |



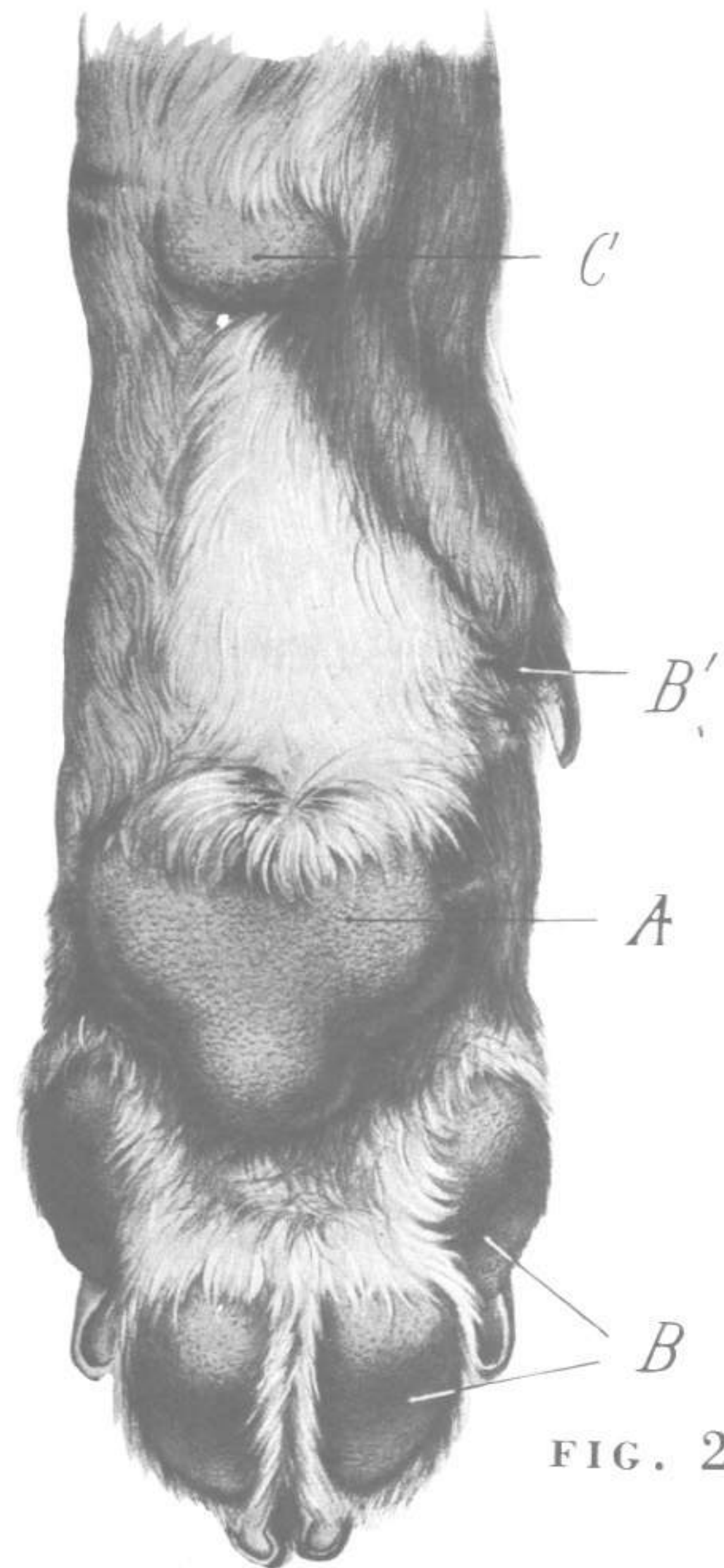


FIG. 22

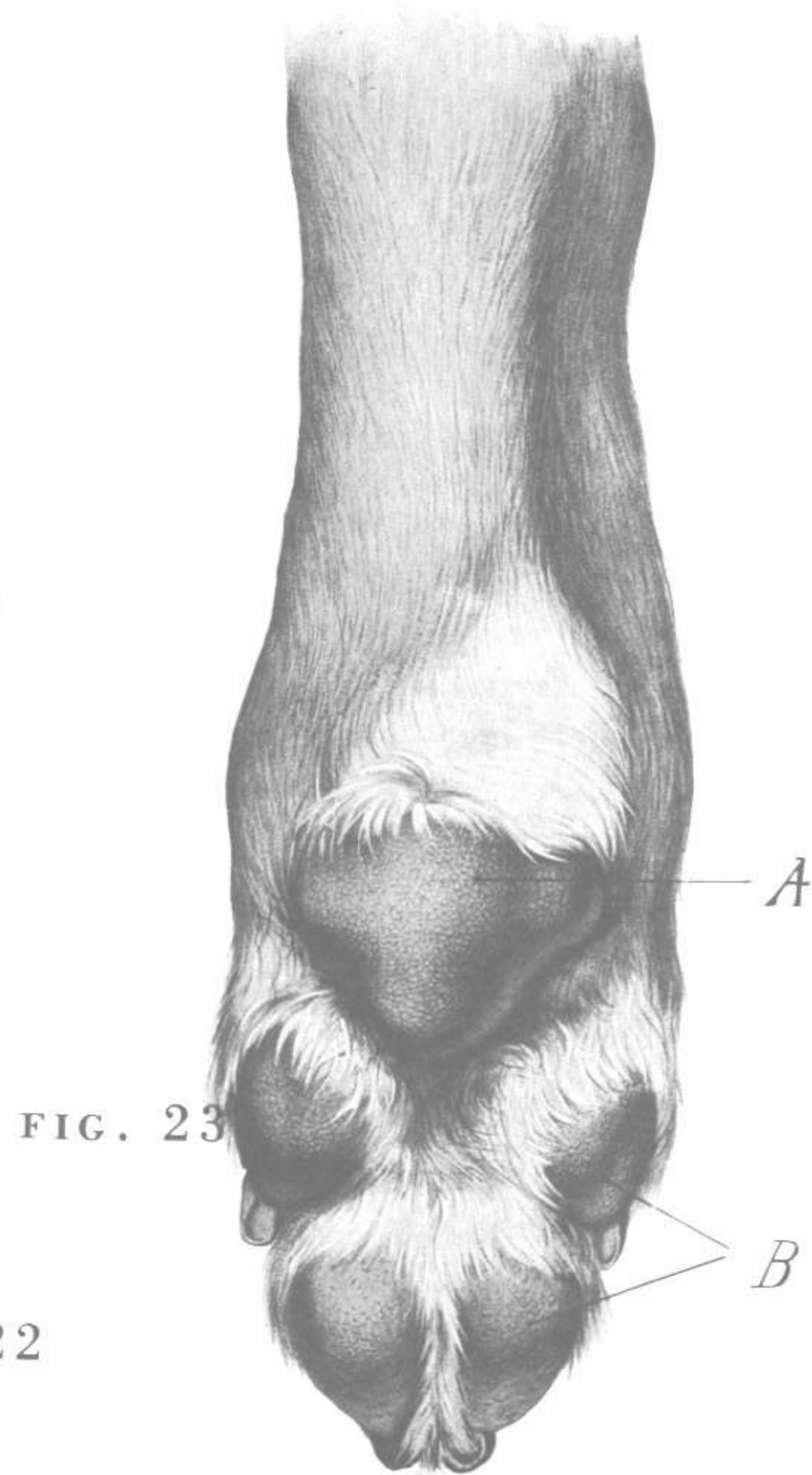


FIG. 23

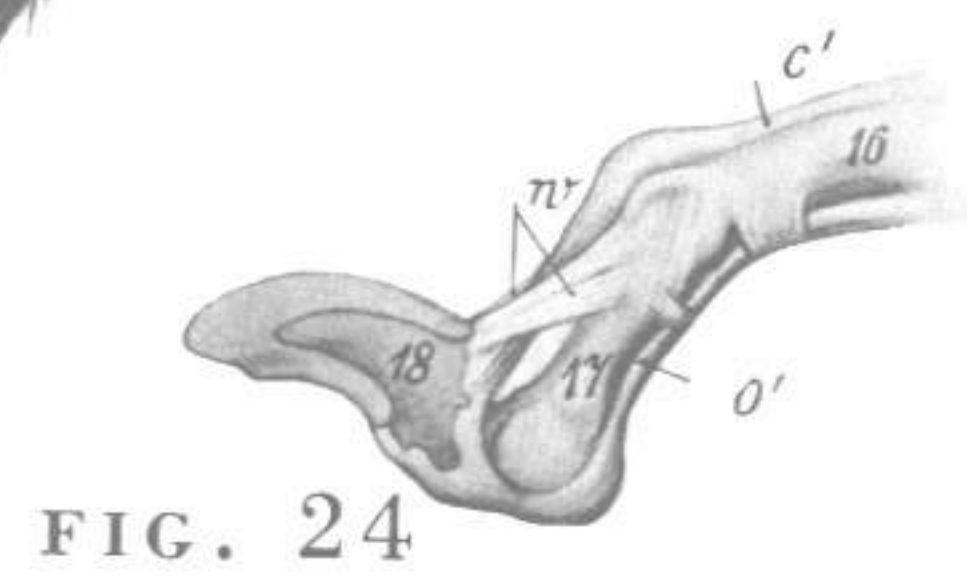


FIG. 24

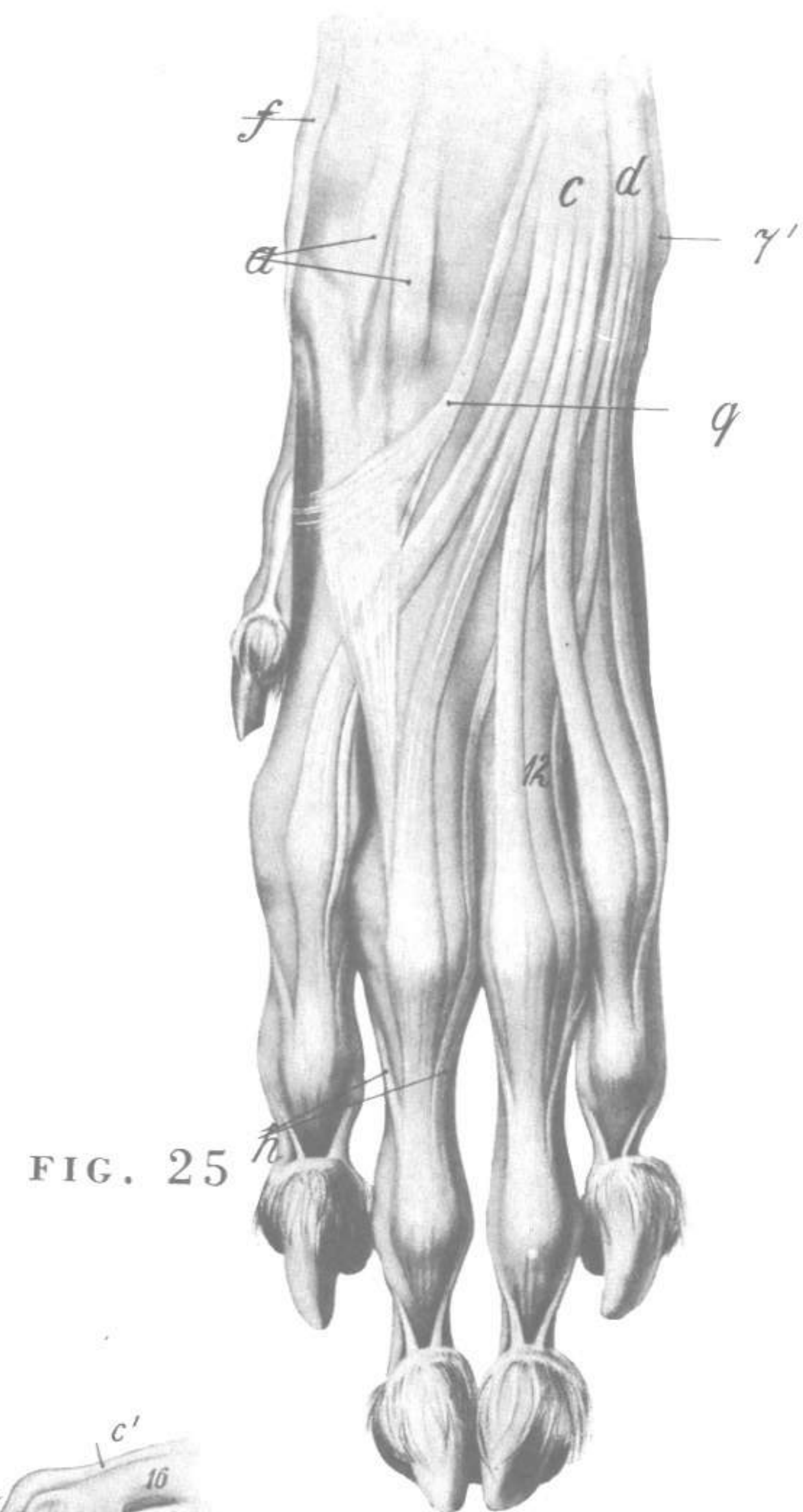


FIG. 25

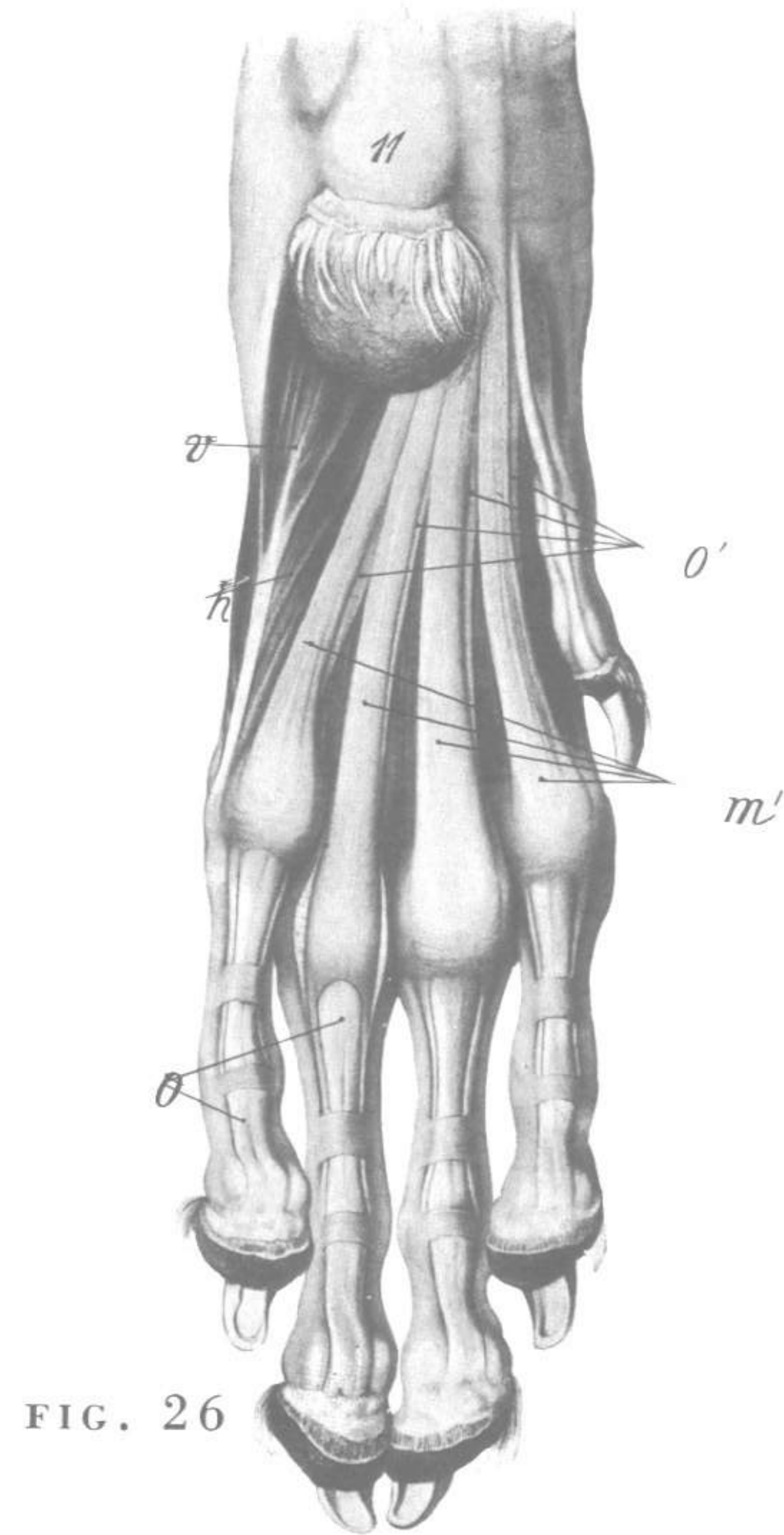


FIG. 26

THE DOG - PLATES 12 13

FIGURES 27 28 29 30 31 32 33 34

a, a'—*M. tibialis anterior*
 b, b'—*M. extensor dig. pedis longus*
 c—*M. peronaeus longus*
 c'—*Tendon*
 d'—*Tendon of M. extensor dig. pedis lateralis*
 d''—*M. peronaeus brevis*
 e—*M. flexor hallucis longus*
 e'—*A tendinous ligament*
 e''—*Tendon of M. tibialis posterior*
 f—*Terminal section of the Mm. gastrocnemii*
 f'—*Tendo Achillis*
 g, g'—*M. flexor dig. pedis sublimis*
 h—*Mm. interossei*
 i—*Annular ligaments*

m, m'—*M. flexor dig. pedis longus*
 n—*Interior lateral ligament of the ankle joint*
 o'—*Fascia lata of femur*
 q, q'—*End of biceps femoris*
 r—*End of M. semitendinosus*
 r', r''—*Two tendons at end of M. semitendinosus*
 w—*End of M. gracilis*
 x, x'—*End of M. sartorius*
 z—*M. extensor dig. pedis brevis*
 18—*Lower end of the femur*
 18'—*Small sesamoid bones*
 20—*Patella*
 21—*Tibia*
 21'—*Interior condyle of tibia*

21''—*Lower end of fibula*
 21'''—*Interior knuckle*
 22—*Tarsus*
 23—*Fibula*
 24—*Tuber calcanei*
 25—*Posterior metatarsus*
 28—*Tuberositas fibiae*
 29—*Sesamoid bones of the toe joints of the*
 metatarsus
 30—*Phalanx prima*
 31—*Phalanx secunda*
 32—*Phalanx tertia*

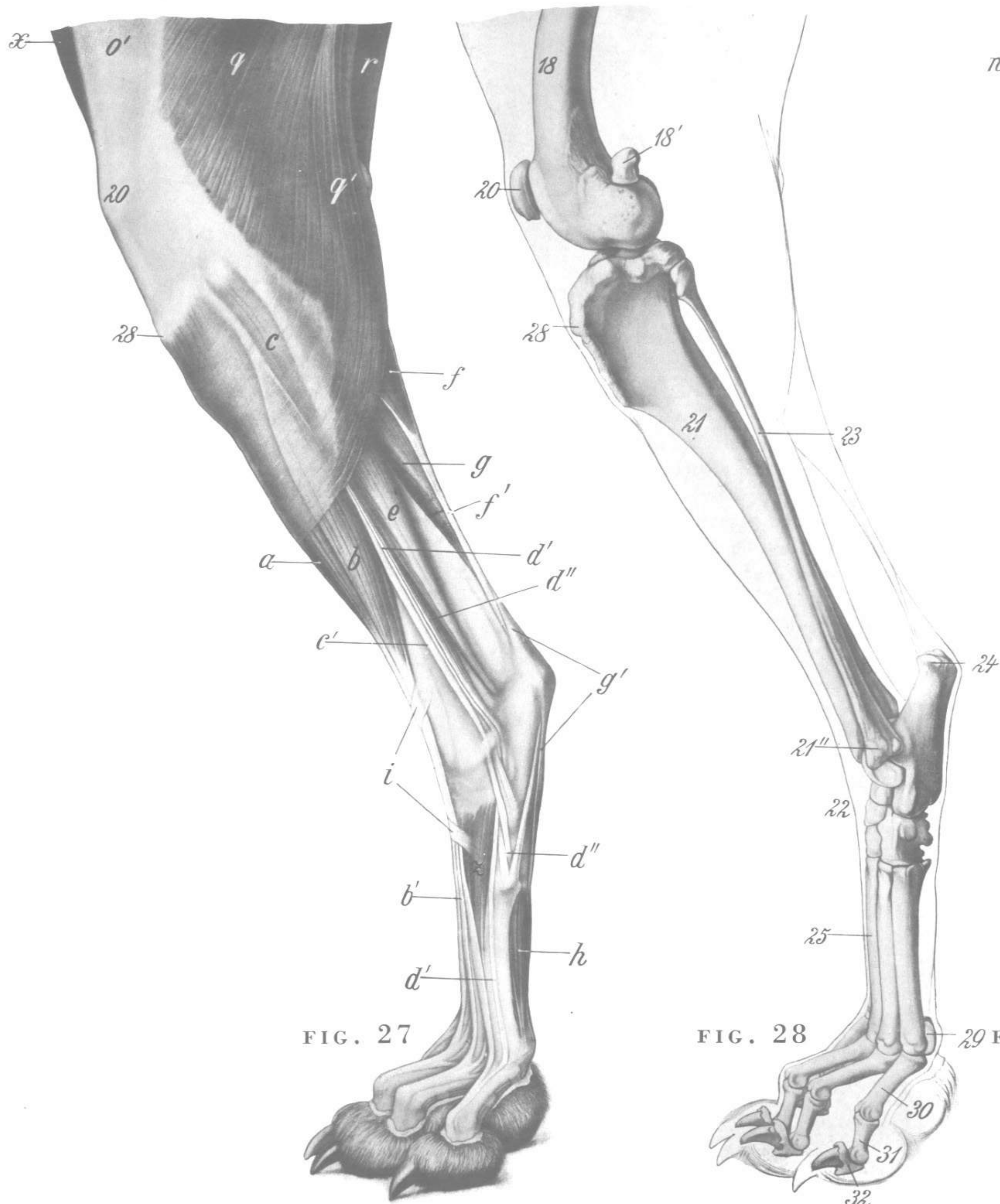


FIG. 28

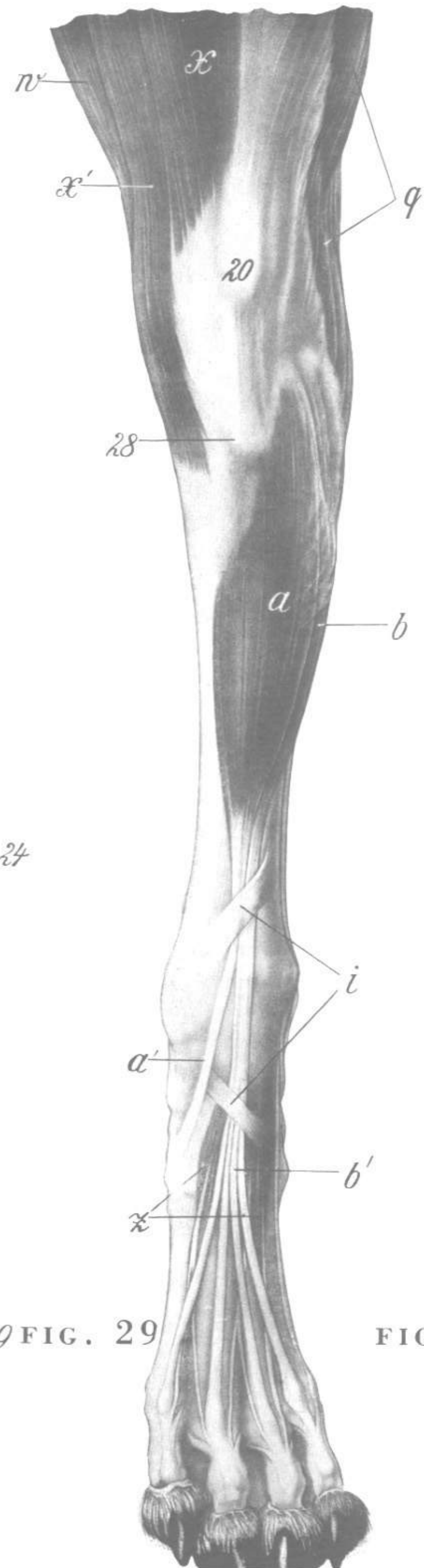
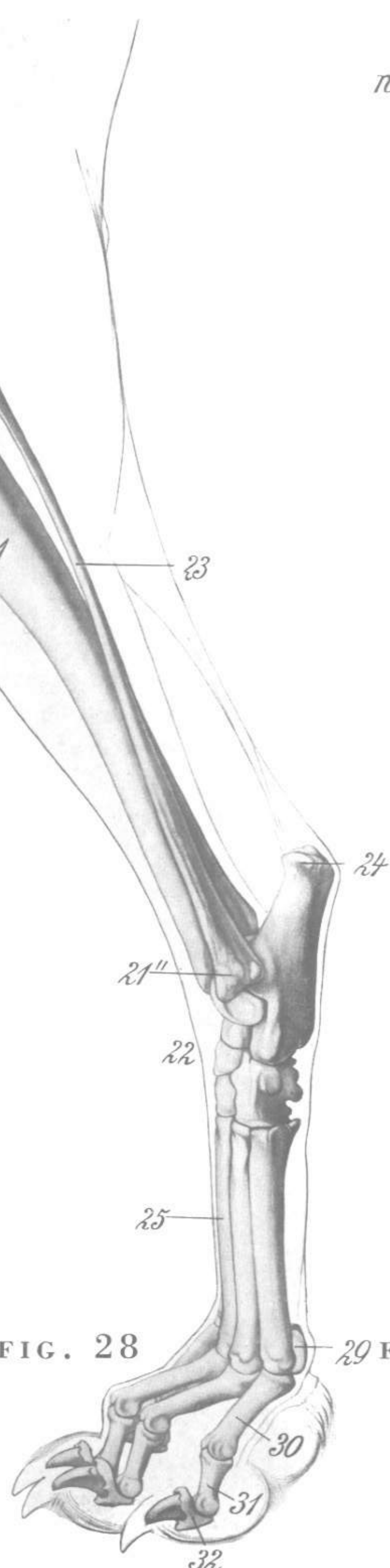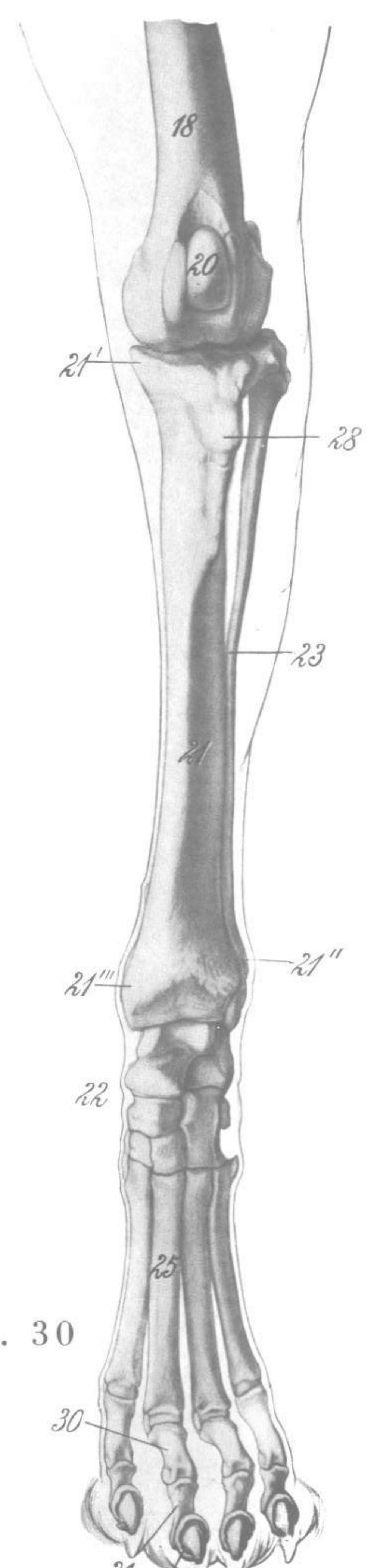
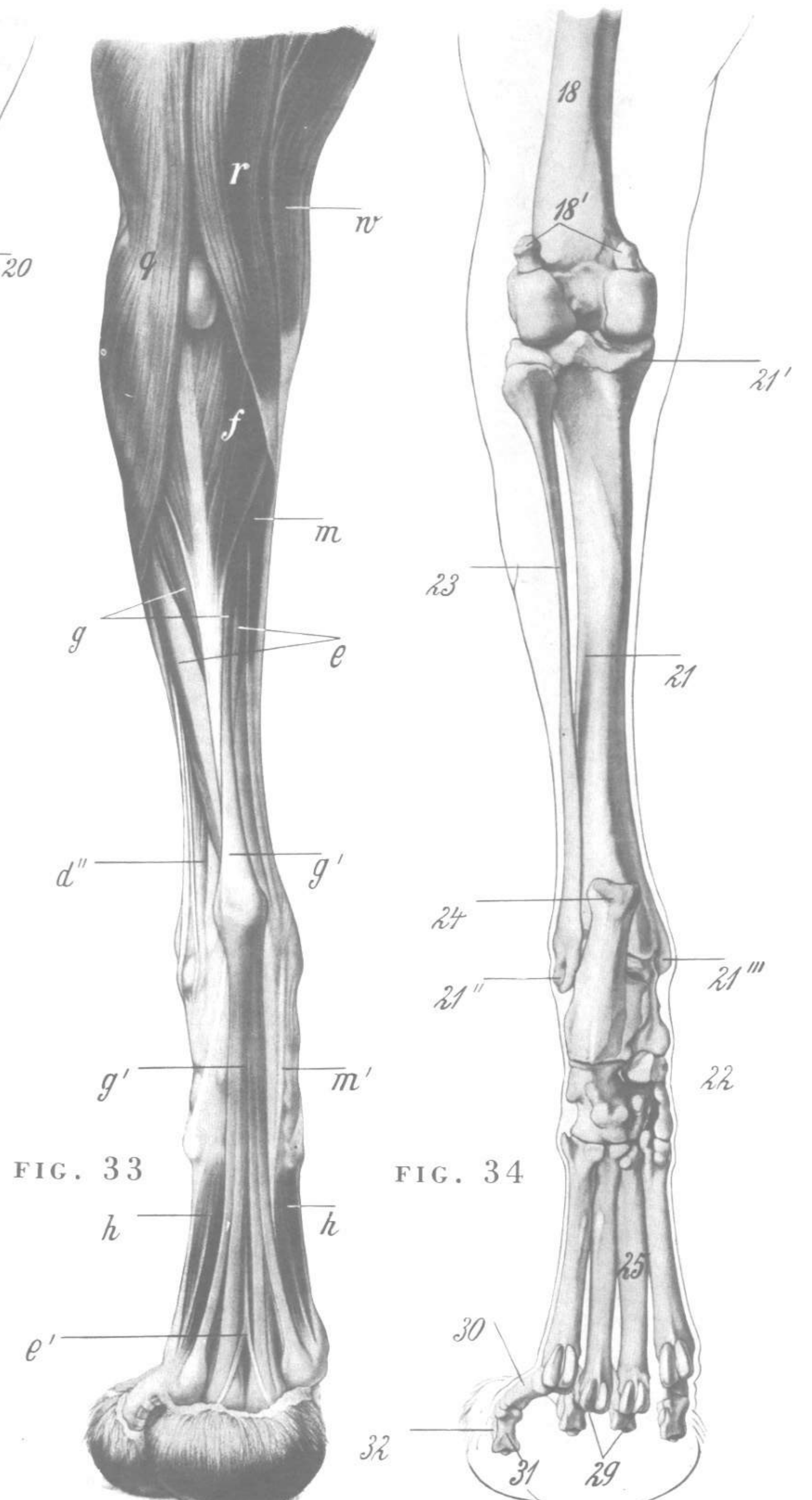
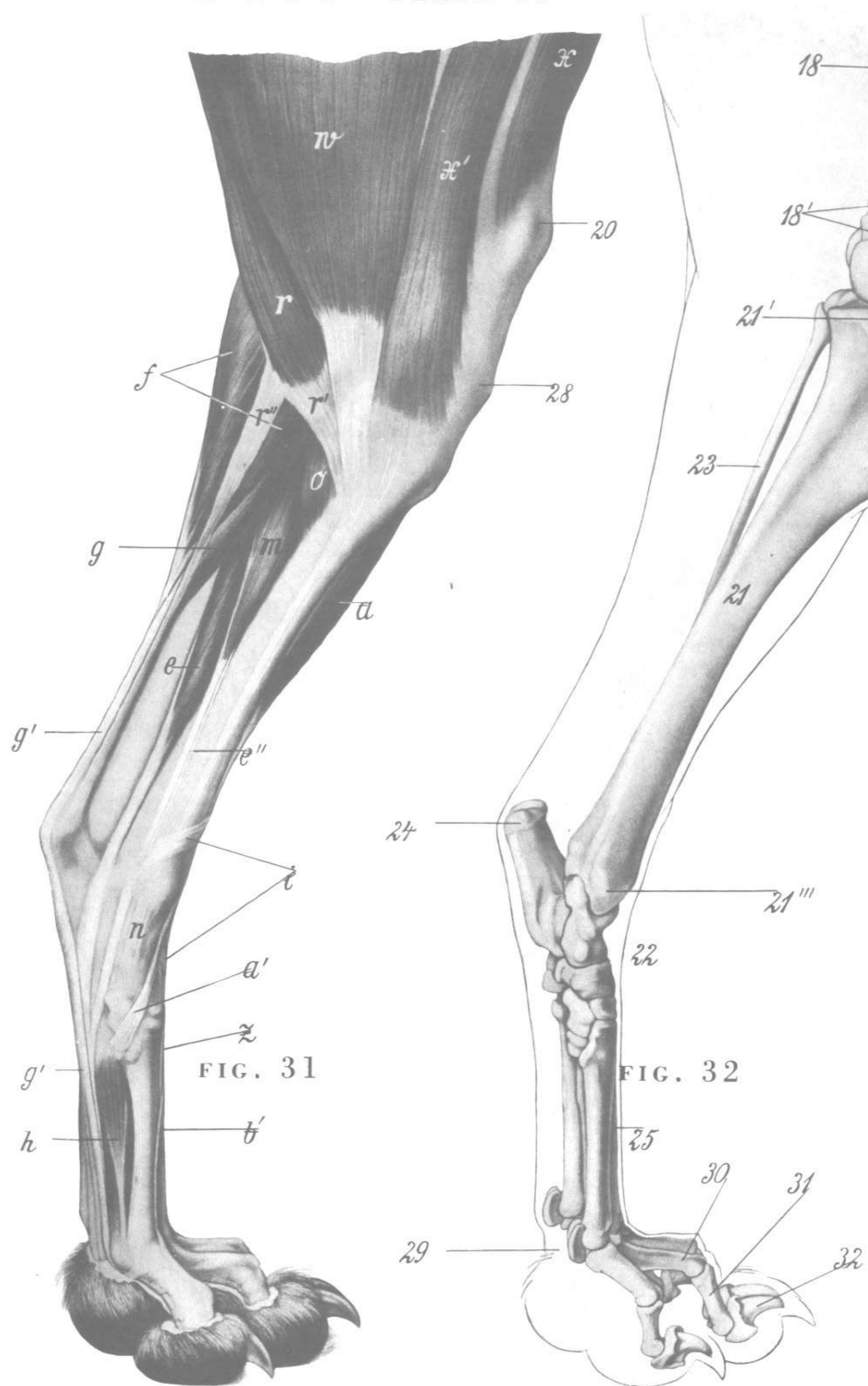


FIG. 30





THE DOG - PLATES 14 15 16

FIGURES 35 36 37 38 39 40 41 42 43 44 45 46 47 48 49 50

a, a'—*M. levator labii superioris proprius*
 b—*M. levator nasolabialis*
 c—*M. brachiocephalicus s. cleidomastoideus*
 c'—*M. sternomastoideus*
 e—End of *Mm. sternohyoidei*
 f—*M. caninus s. pyramidalis nasi*
 g—*M. zygomaticus*
 g'—*M. zygomaticus minor s. M. malaris*
 h—*M. buccalis*
 i—*M. molaris*
 k—*M. orbicularis oris*
 m—*M. masseter*
 n—*M. depressor auris*
 o—Exterior adductor of the ear
 p, p'—Common muscle of the ear
 q—End of the long abductor of the ear
 r—Long levator of the auricle
 u—*M. orbicularis palpebrarum*
 u', u'', u'''—*Mm. corrugatores supercilii*
 v—End of the two-bellied (digastric) muscle
 w—*M. mylohyoideus*
 y—Cervical subcutaneous muscle (cervical
 panniculus)
 z—*M. temporalis*
 z'—*M. occipitalis*

1—Left auricle
 2, 2'—Posterior edge of the auricle
 4—Incisura intertragica
 8—Scutulum
 9—Arcus zygomaticus
 11—Processus coronoideus of the inferior
 maxillary bone
 12—Frontal process of the molar bone
 12'—Zygomatic process of the frontal bone
 12''—Orbital band on the frontal bone
 13—Os occipitale
 13'—Spine of the occipital bone
 13''—Jugular process of the occipital bone
 13'''—Condylod process of the occipital bone
 14—Os parietale
 14'—Crest of the parietal bone
 15—Os frontale
 16—Os temporale
 17—Meatus acusticus externus
 18—Temporo-maxillary articulation
 19—Orbita
 20—Os zygomaticum s. jugale
 21—Os lacrimale
 22—Os nasale
 23—Os incisivum
 24—Upper incisor teeth

24'—Lower incisor teeth
 25—Upper canine tooth
 26—Maxilla
 27—Facial crest
 28—Unpaired portion of the lower jawbone
 28'—Paired portion of the body of the lower
 jawbone
 29—Lower canine tooth
 30—Branch of the lower jaw
 30'—Processus angularis
 31—Condylod process of the lower jaw
 32—Atlas
 34—Upper lateral cartilage of the nose
 34'—Lower lateral cartilage of the nose
 35—External insertion cartilage
 36—Lymph follicle of the oesophagus
 38—*V. jugularis*
 39—*V. facialis*
 44—Glandula parotis
 49—Nose
 50—Glandula submaxillaris
 52—Eyelid
 53—Caruncula lacrimalis
 55—Anterior part of the sclera
 55'—Cornea
 56—Pupil

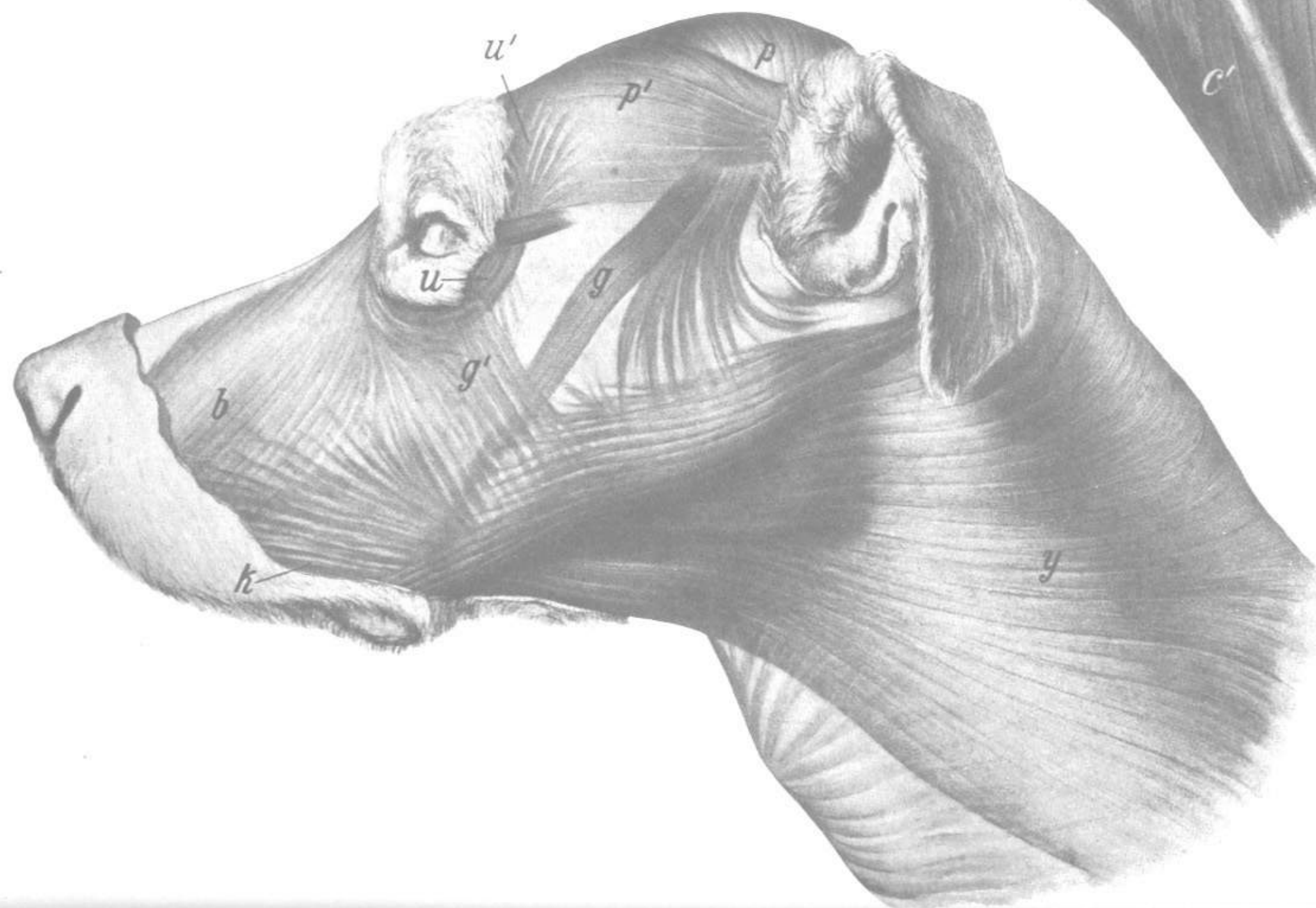
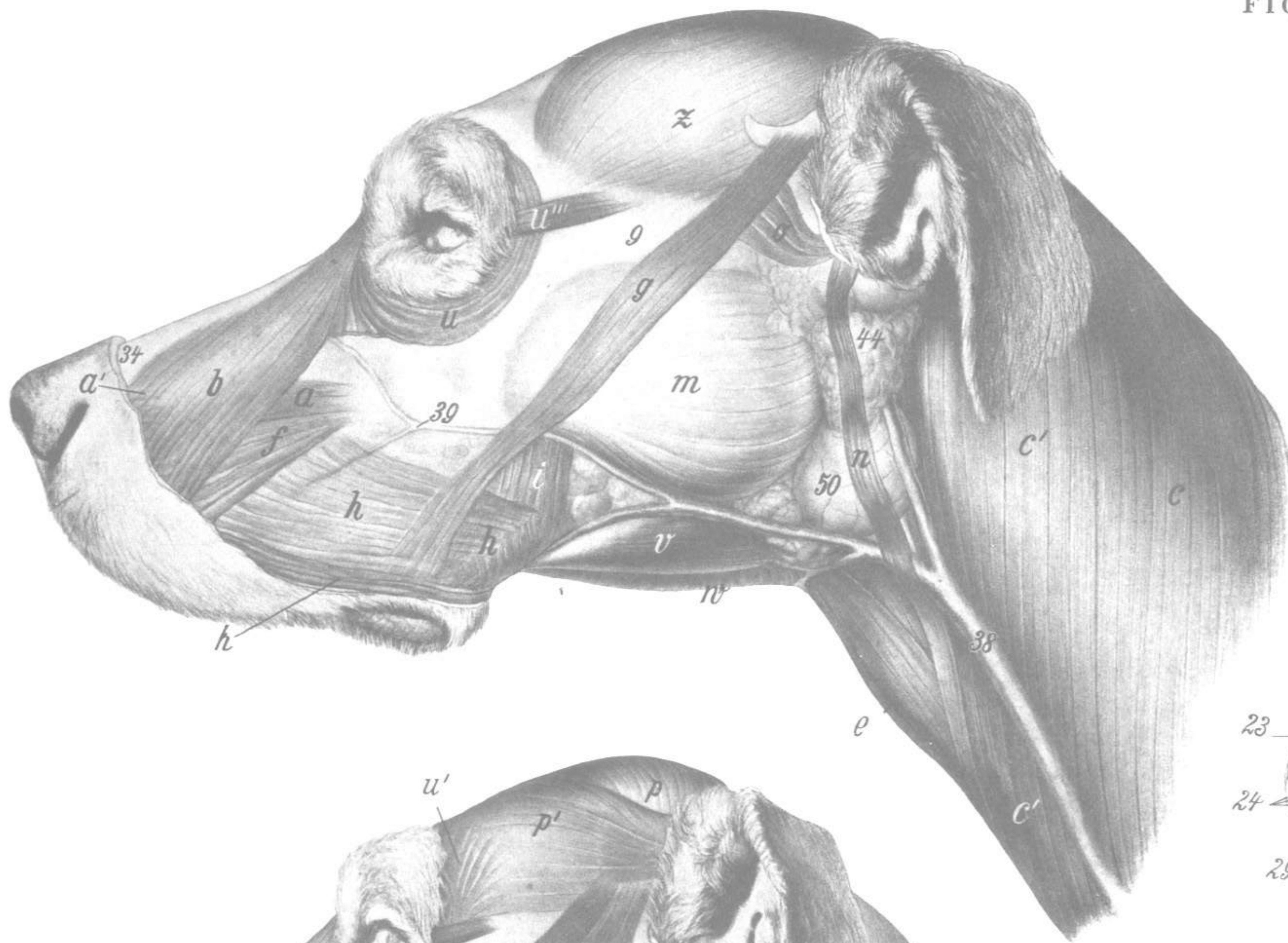


FIG. 47

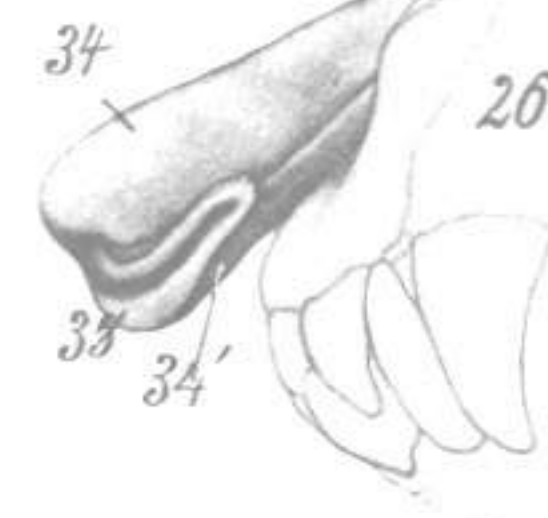


FIG. 39
(SHORT HEAD)

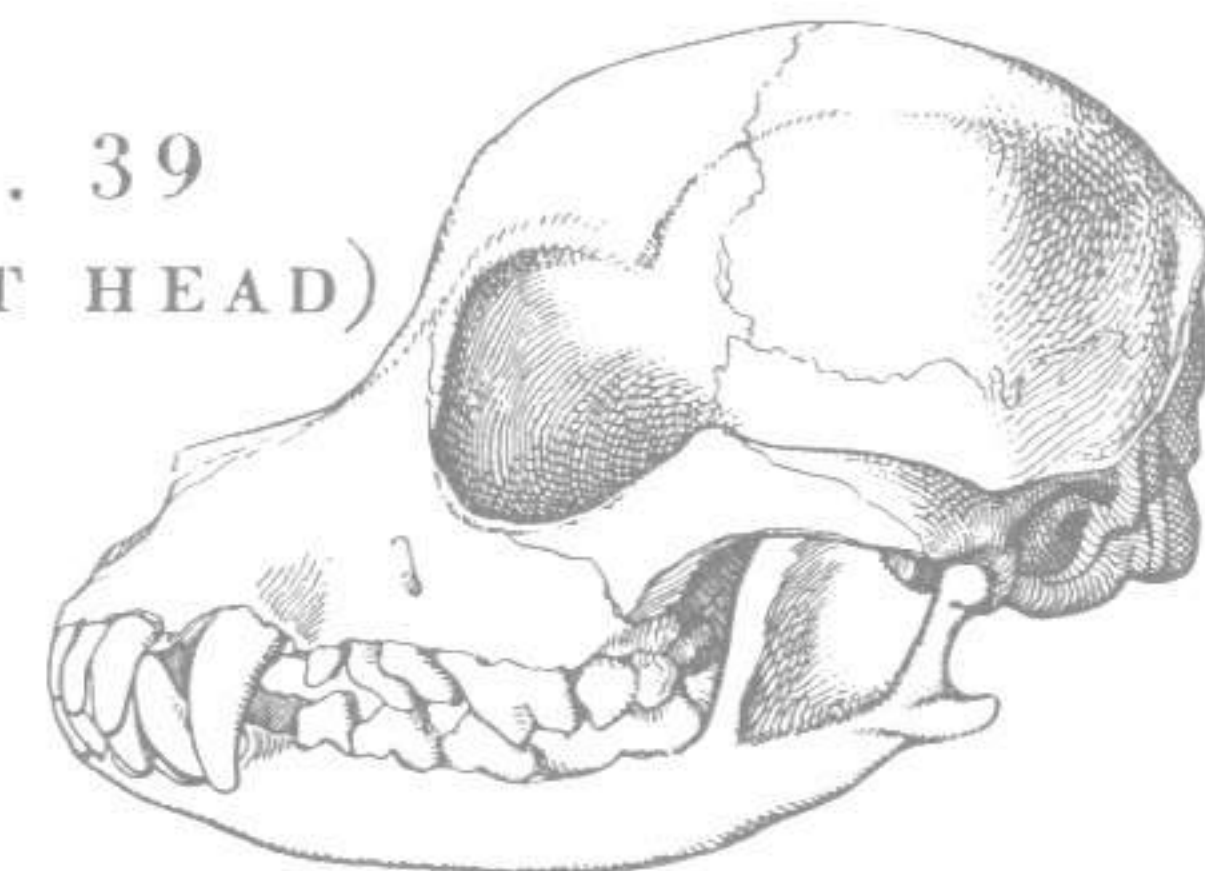


FIG. 36

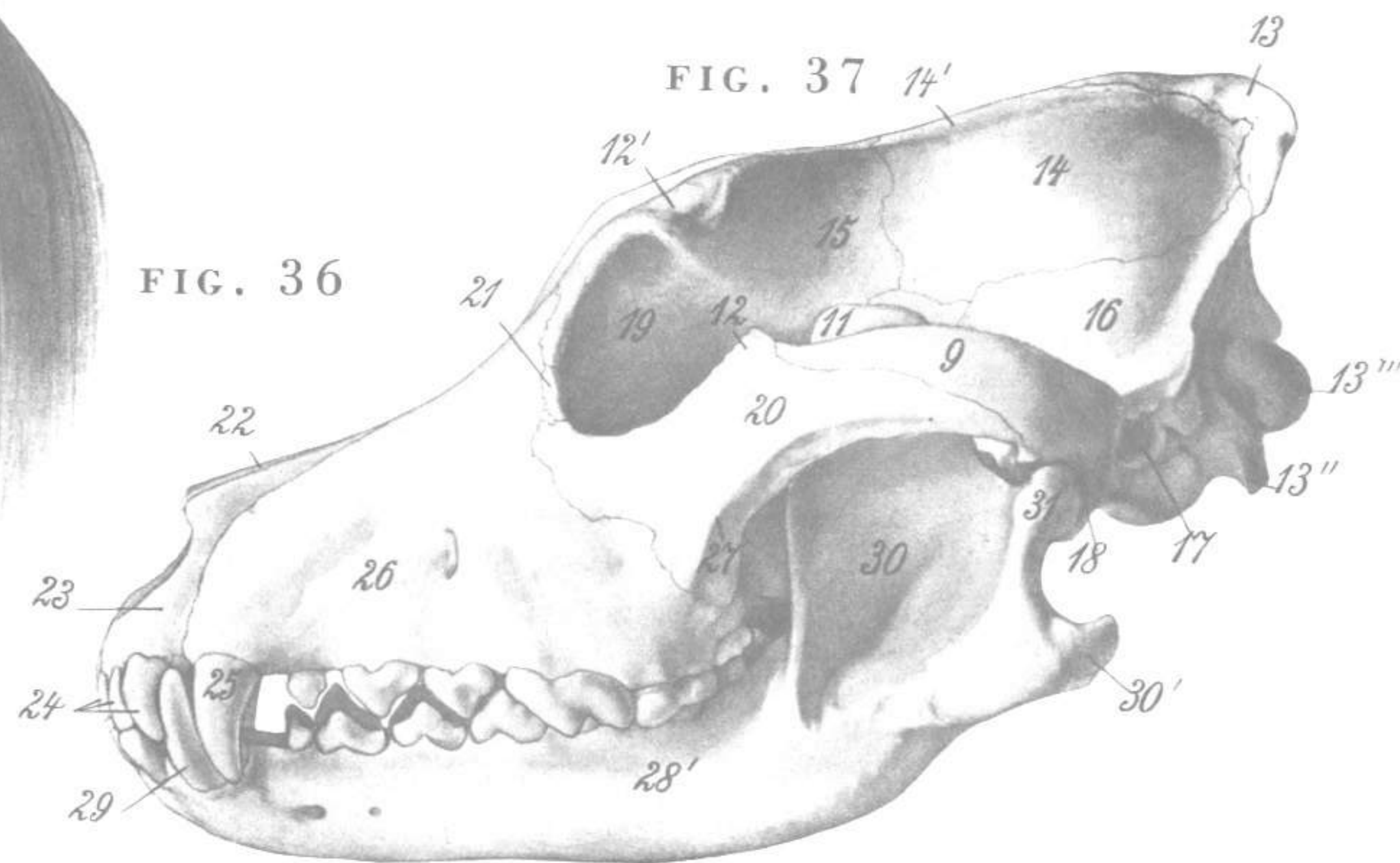


FIG. 37

FIG. 38
(LONG HEAD)

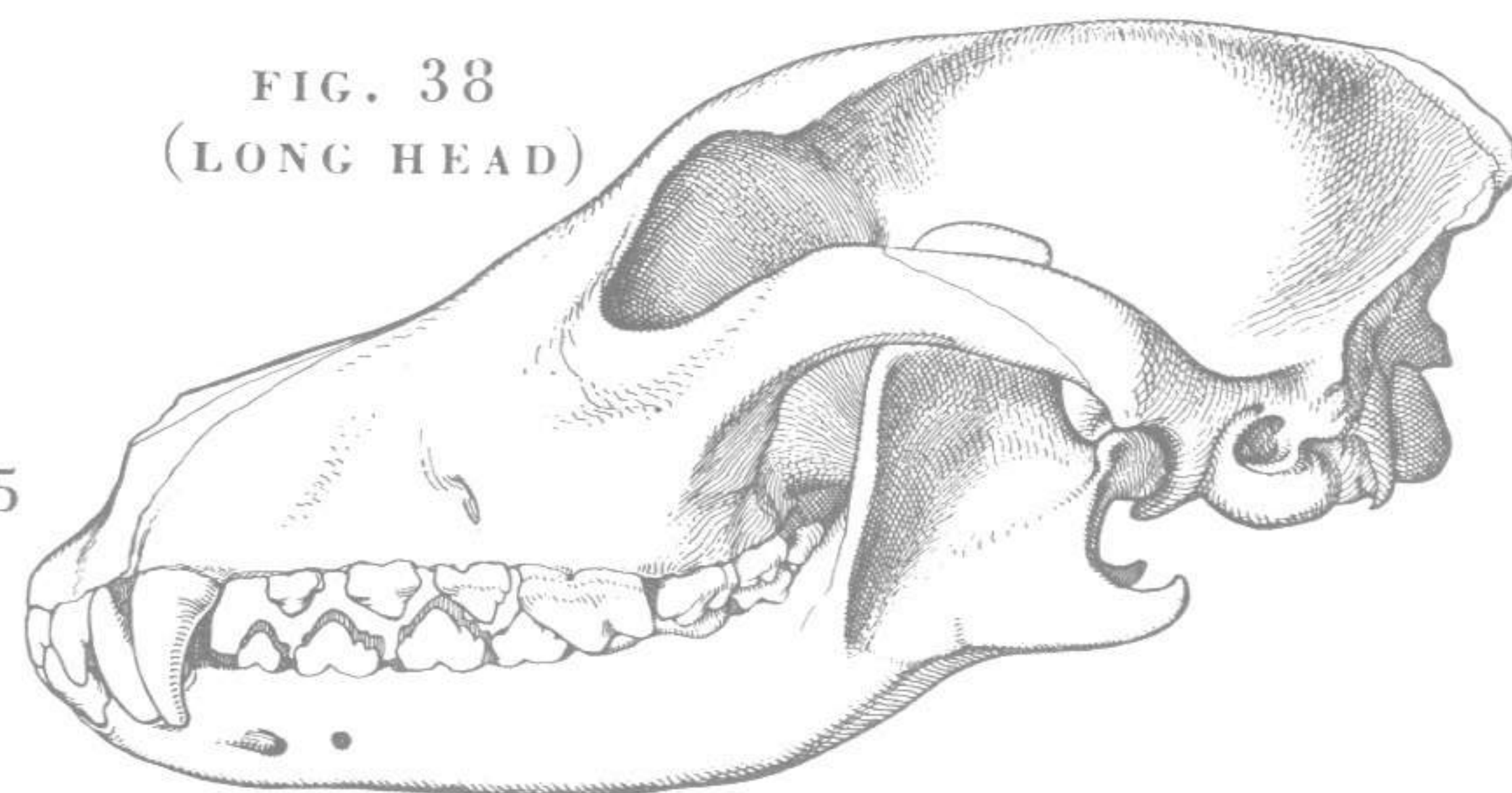


FIG. 35

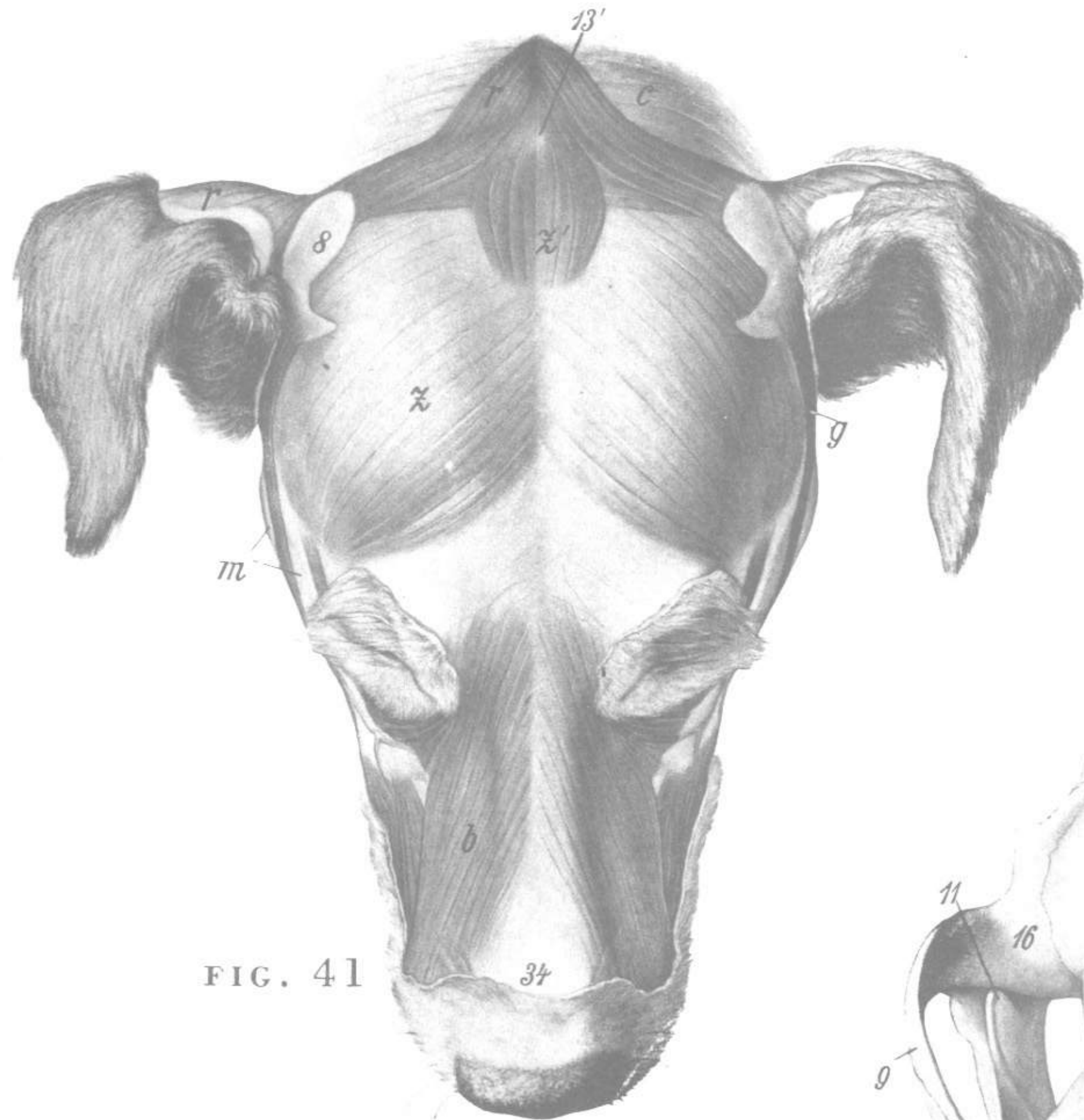


FIG. 41

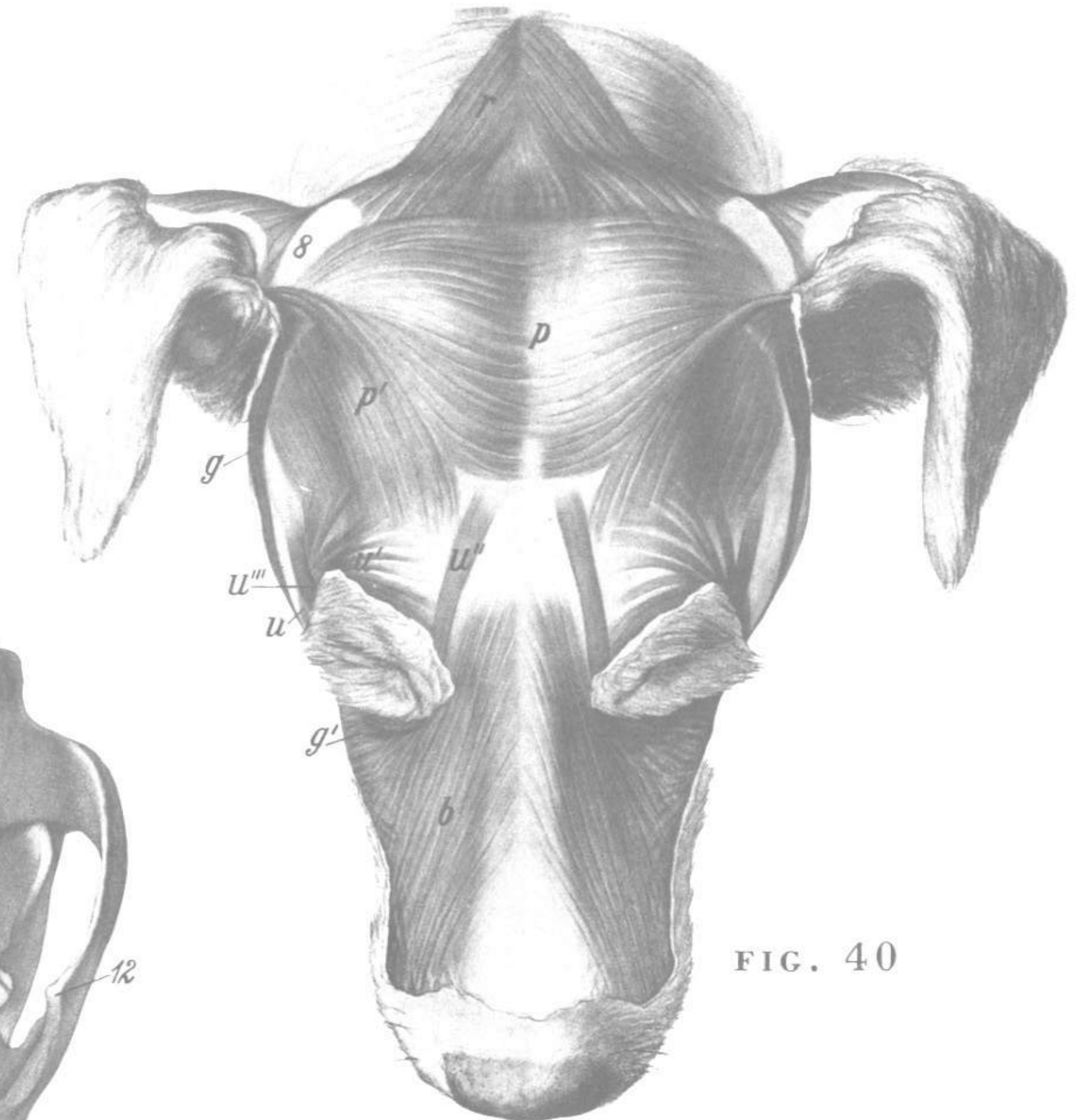


FIG. 40

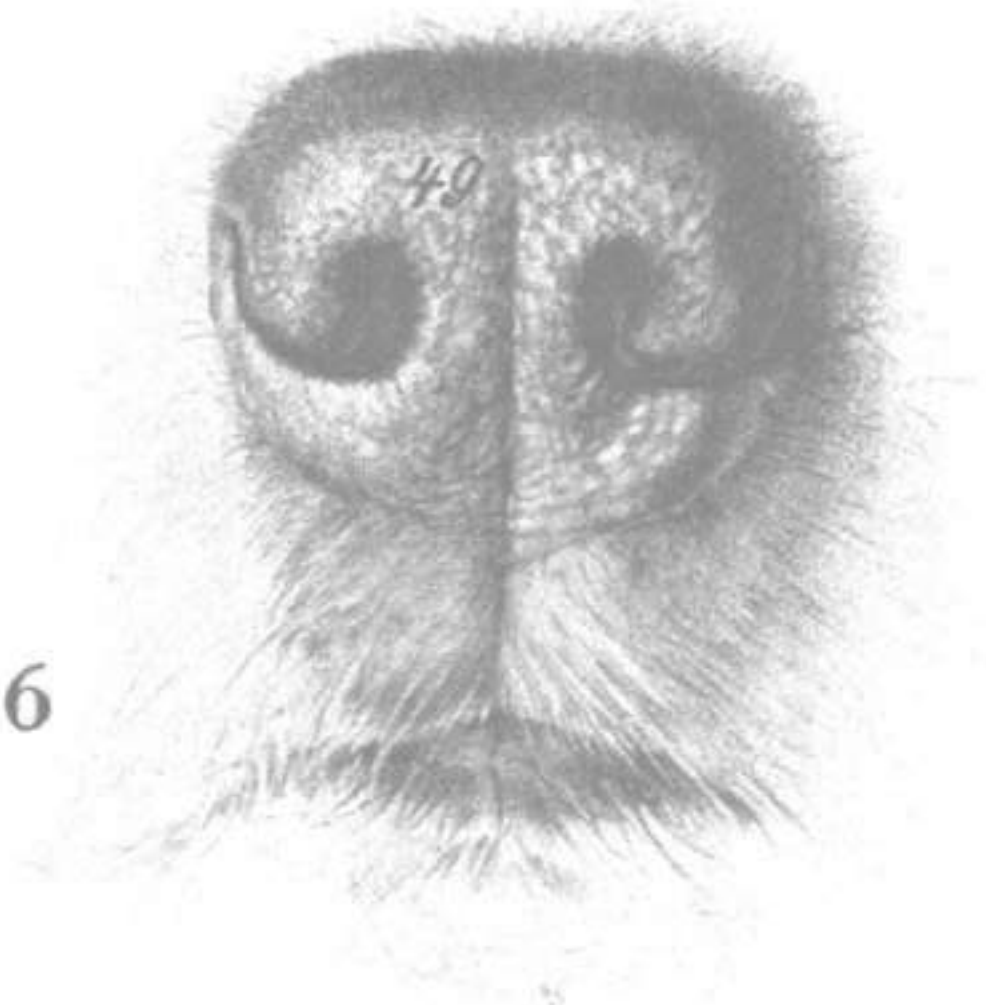


FIG. 46

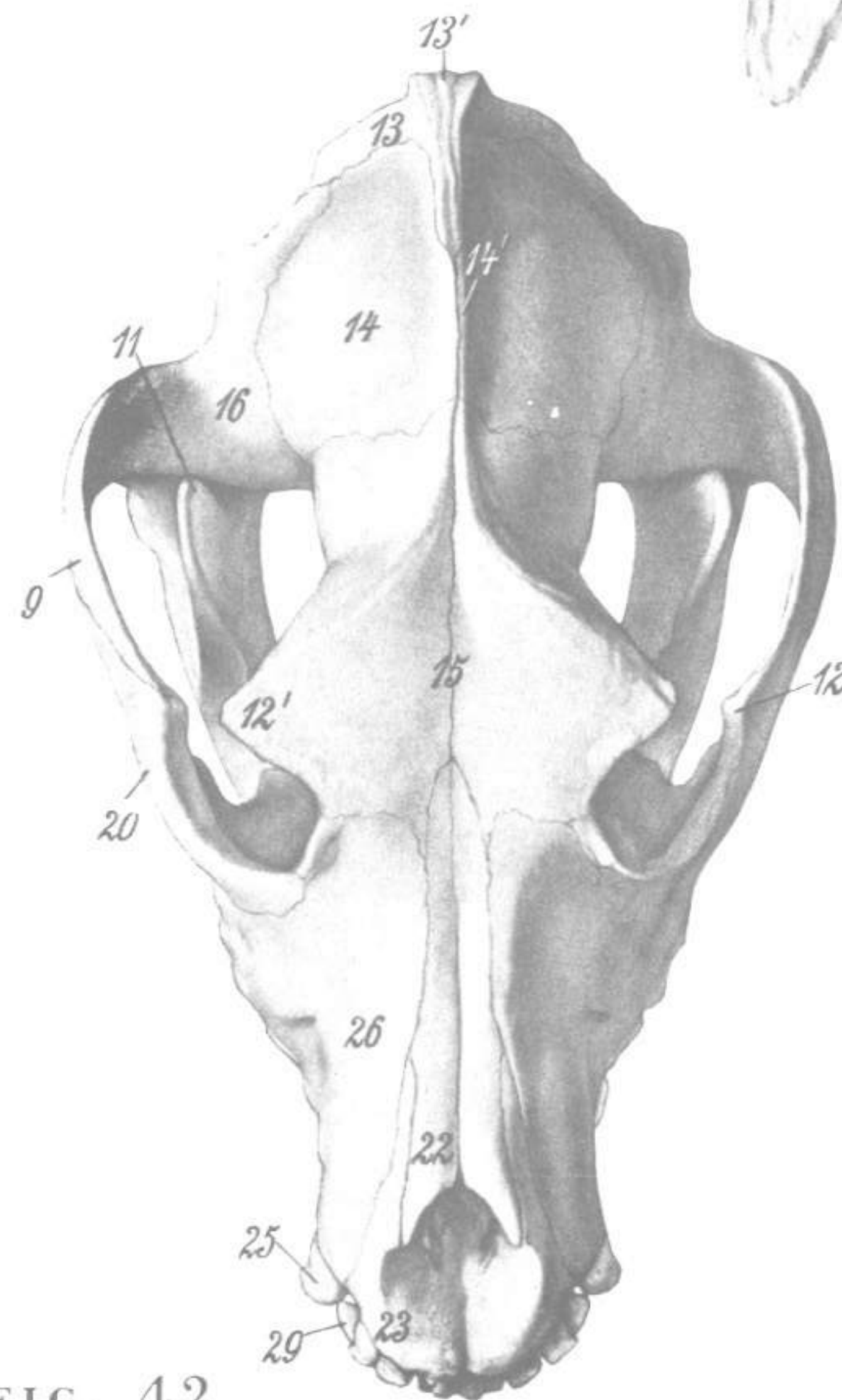


FIG. 42

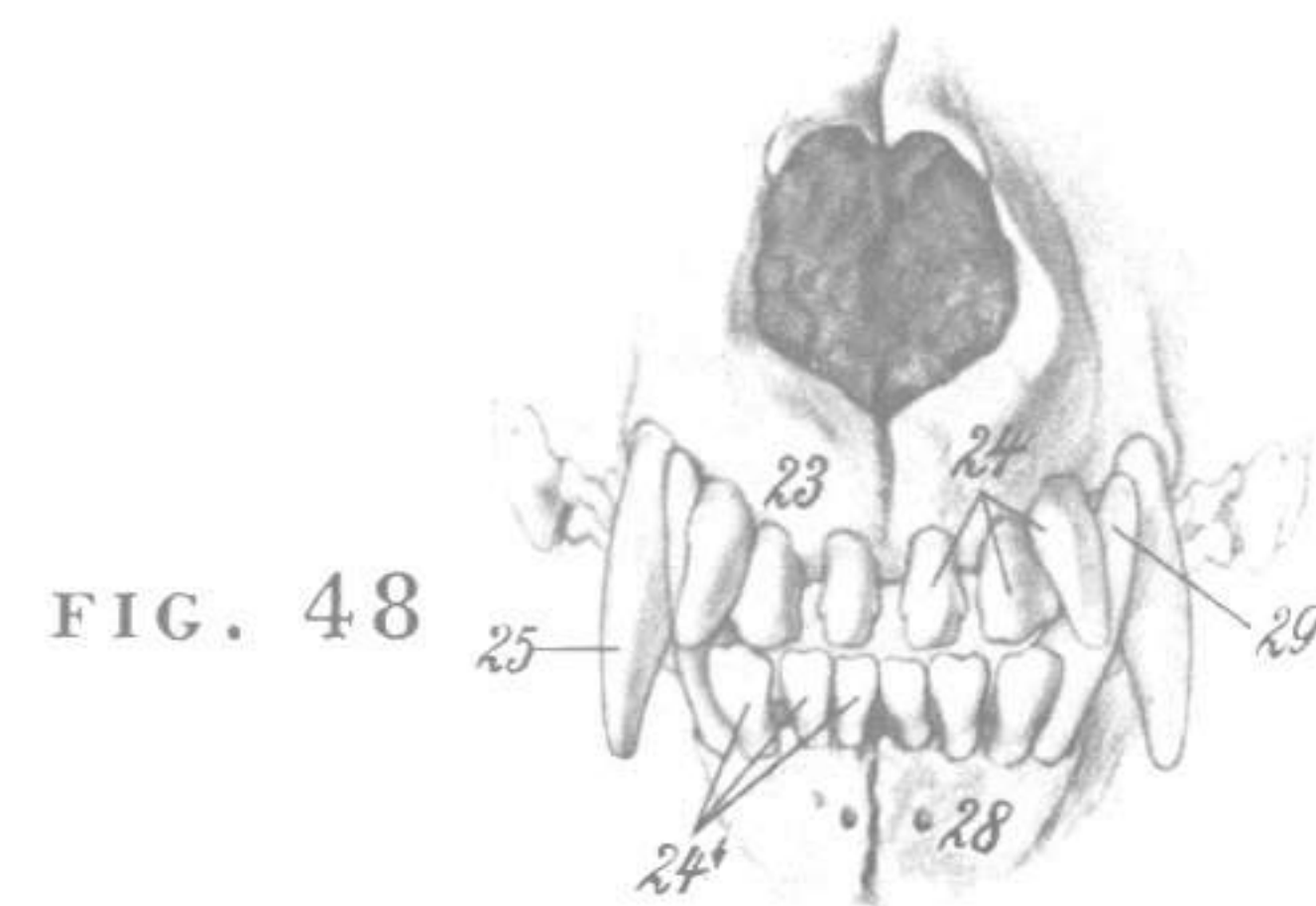


FIG. 48

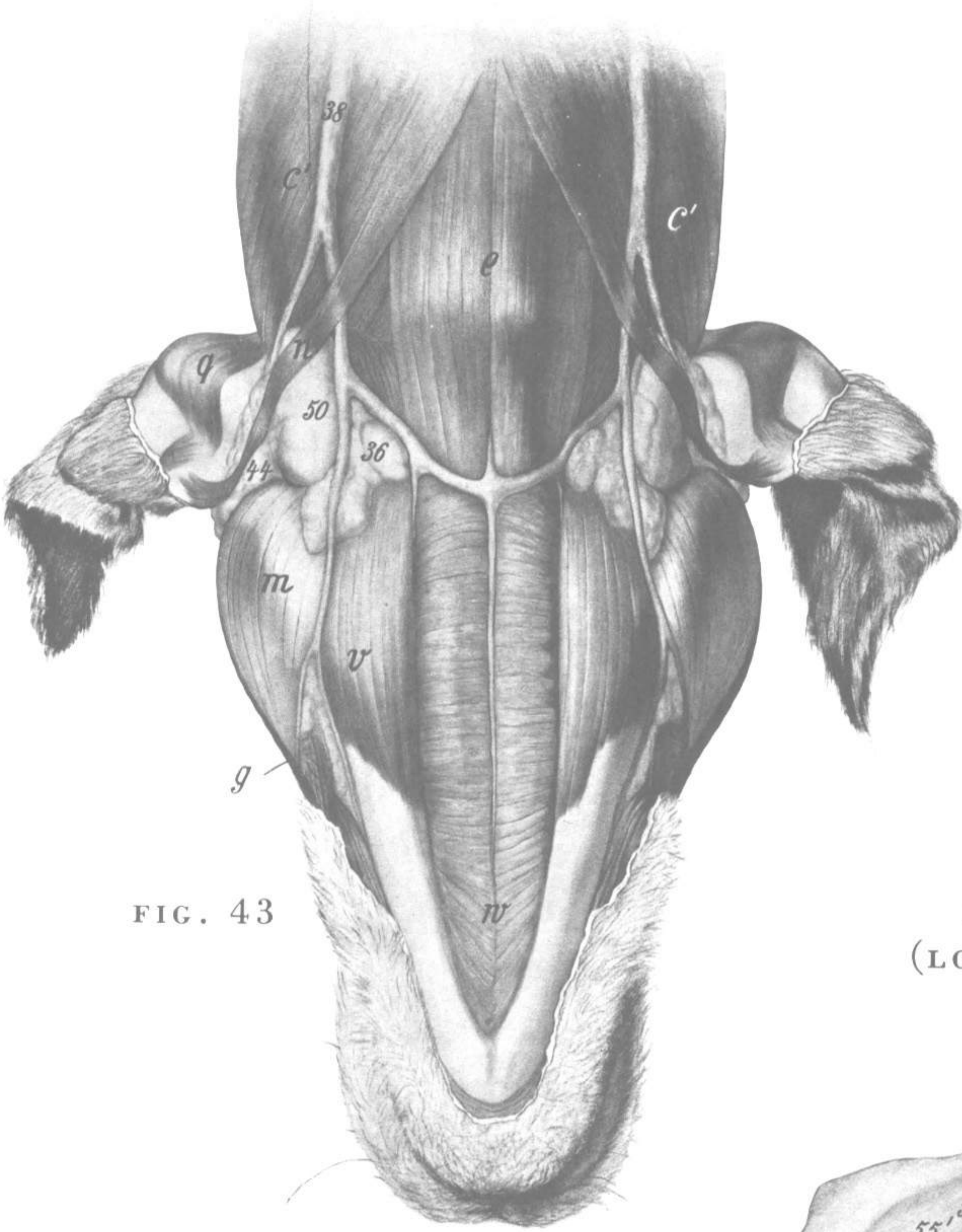


FIG. 43

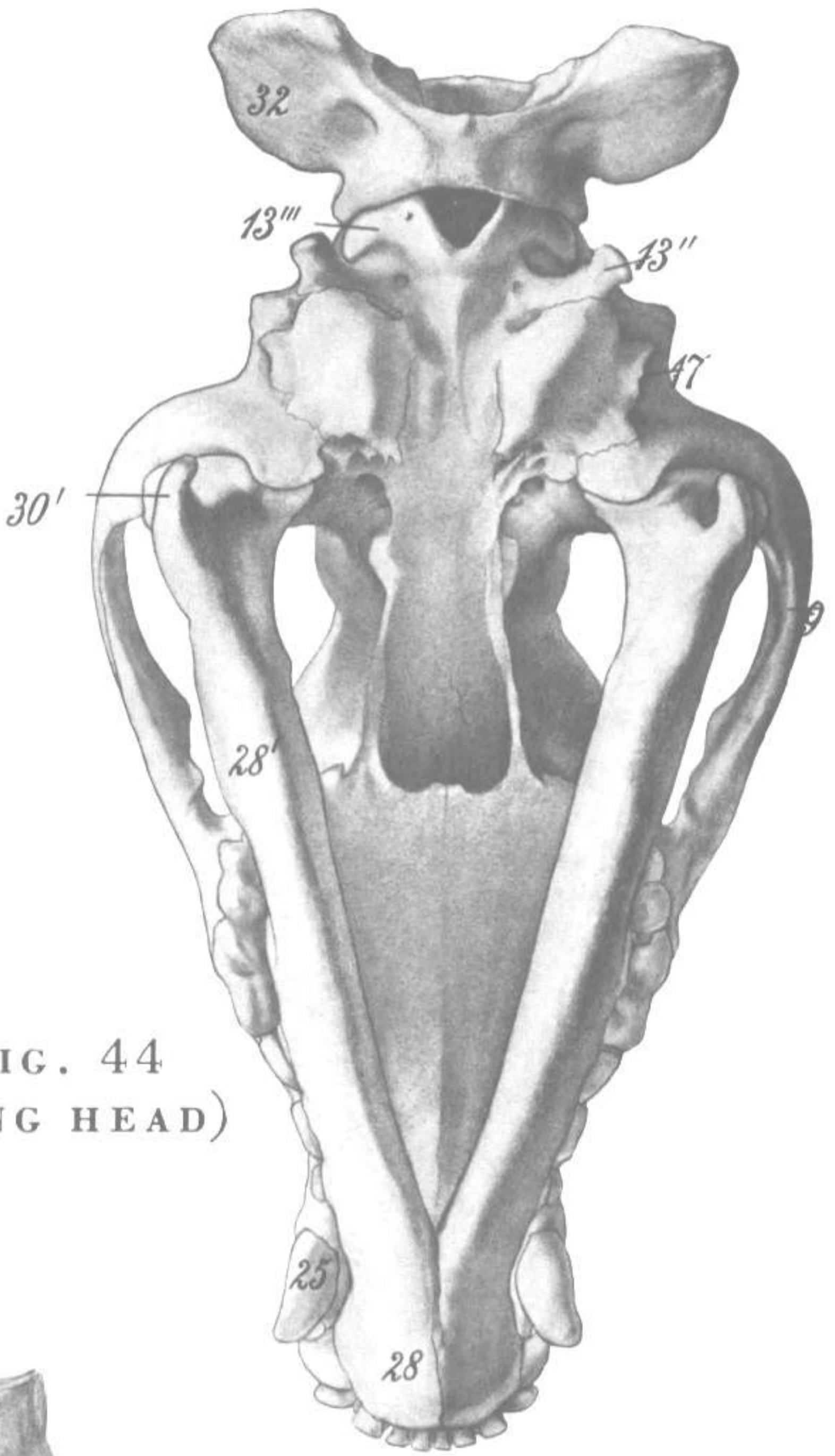


FIG. 44
(LONG HEAD)

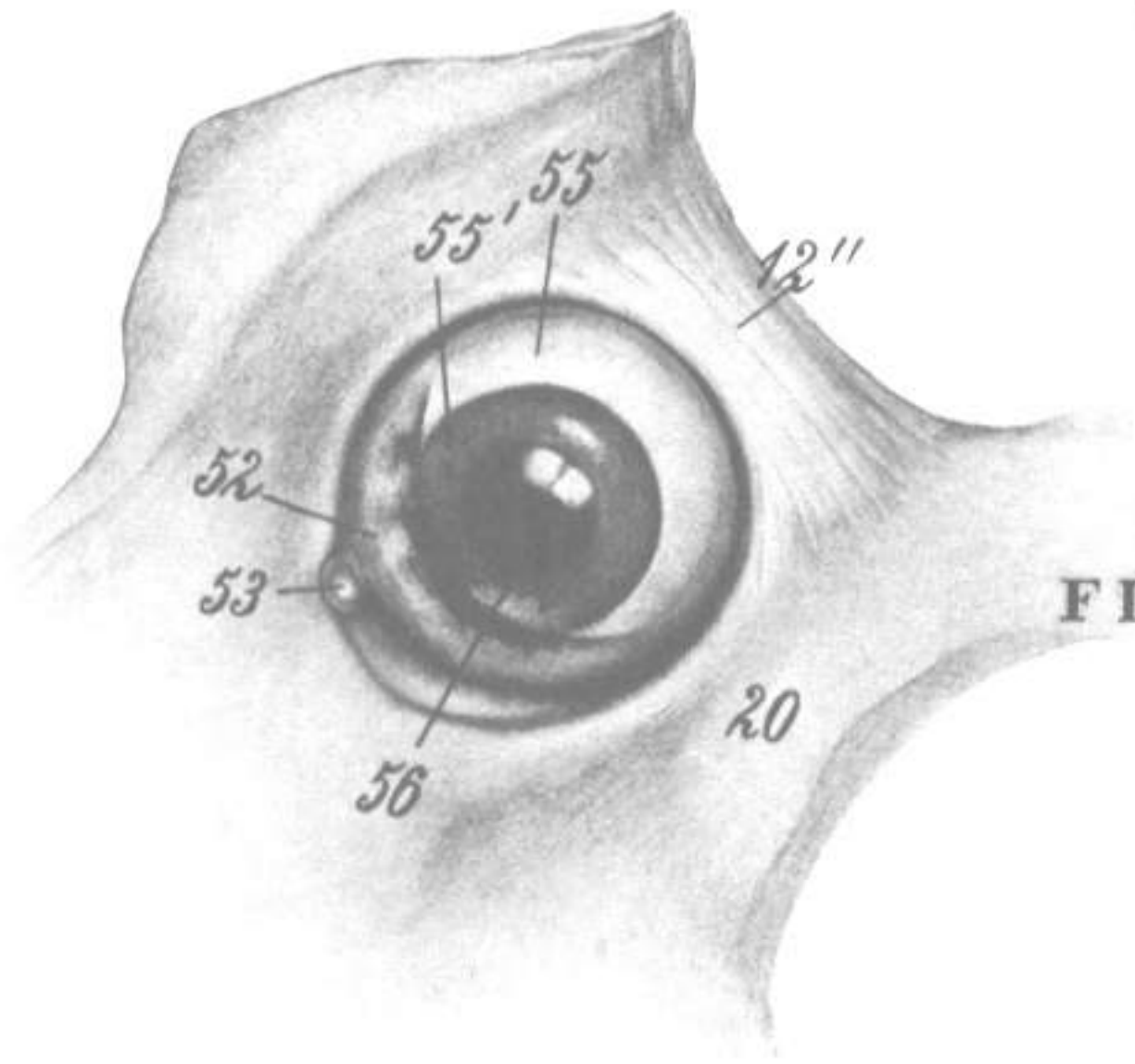


FIG. 49

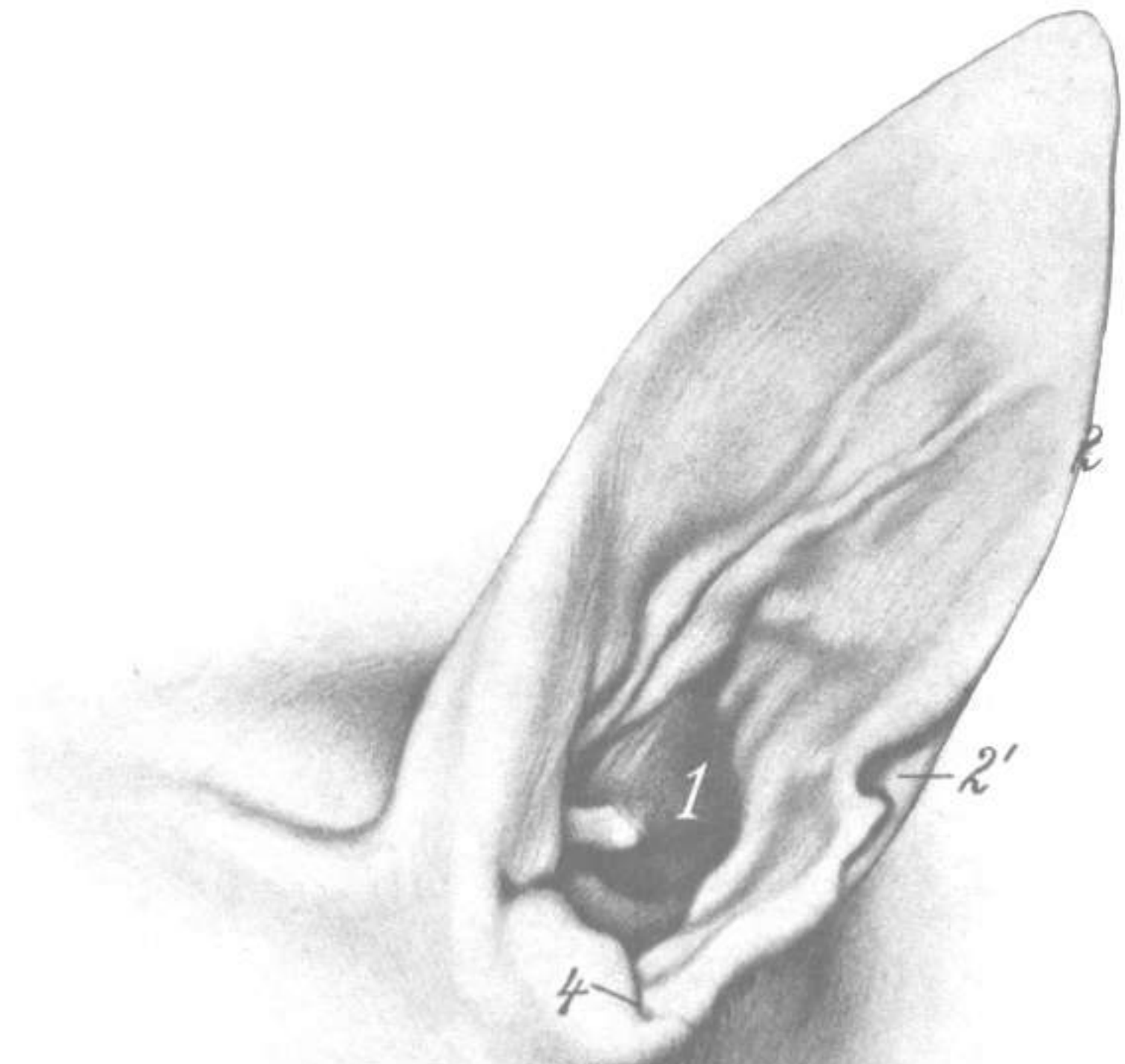


FIG. 50

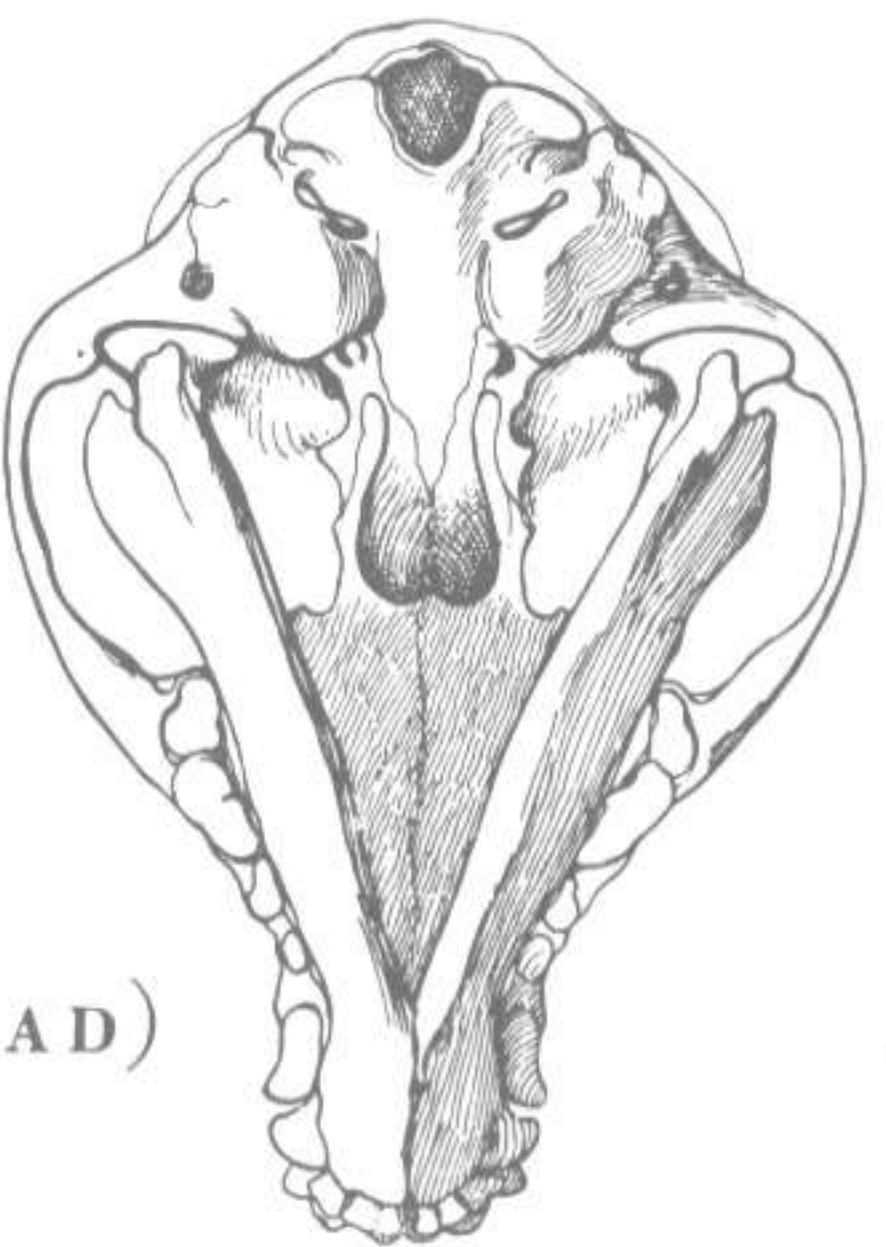


FIG. 45
(SHORT HEAD)

The Lion

THE LION - PLATES 1 2 3 4 5 6

FIGURES 1 2 3 4 5 6 7 8 9

- a, a'—*M. trapezius*
 b—*Shoulder-transverse-process muscle*
 c, c', c''—*M. cleidomastoideus*
 d—*M. sternomandibularis*
 e, e'—*M. deltoideus*
 f, f'—*M. triceps brachii*
 g, g'—*M. pectoralis major*
 h—*Posterior part of the M. pectoralis minor*
 k—*M. latissimus dorsi*
 l—*M. obliquus abdominis externus*
 l'—*Aponeurosis*
 l''—*Fold of muscle at thigh*
 m'—*Lumbo-dorsal fascia*
 o—*M. tensor fasciae latae*
 o'—*Fascia lata*
 o''—*M. glutaeus maximus*
 p—*M. glutaeus medius*
 p'—*Fascia glutaee*
 q, q'—*M. biceps femoris*
 r—*M. semitendinosus*
 s—*Levator of the tail*
 t—*Mm. intertransversarii of the tail*
 v—*M. semimembranosus*
 w—*M. gracilis*
 x—*M. occipitalis*
 y, y'—*Muscles of the ear*
- 1H—*1st cervical vertebra (Atlas)*
 7H—*7th cervical vertebra*
 K—*Sacrum*
 6K—*6th costal cartilage*
 1L—*1st lumbar vertebra*
 7L—*7th lumbar vertebra*
 1R—*1st rib*
 6R—*6th rib*
 12R—*12th thoracic (dorsal) vertebra*
 13R—*13th rib*
 1Rx—*1st thoracic (dorsal) vertebra*
 1S—*1st caudal vertebra*
 *—*Ala border of atlas*
 1—*Scapula*
 2—*Spina scapulae*
 3—*Acromion*
 4—*Humerus*
 4'—*External epicondyle*
 5—*External tuberosity*
 6—*Rotator*
 7—*Ulna*
 8—*Olecranon*
 9—*Radius*
 10—*Carpus*
 11—*Os pisiforme*
 12—*Metacarpus*
- 13—*Phalanges manus*
 14—*Sternum*
 14'—*Manubrium sterni*
 15—*Ossa pelvis*
 16—*Tuber coxae*
 17—*Tuber ischiadicum*
 18—*Os femoris*
 19—*Trochanter major*
 20—*Patella*
 21—*Tibia*
 21'—*External condyle of the tibia*
 22—*Tarsus*
 23—*Fibula*
 24—*Tuber calcanei*
 25—*Metatarsus*
 26—*Phalanges pedis*
 27'—*Occipital tuberosity*
 28—*Parietal bones*
 30—*Transverse processes of the lumbar vertebrae*
 44—*Incipient part of the M. rectus abdominis*
 46—*Anterior belly of the M. sartorius*
 47—*M. tensor fasciae antebrachii*
 48—*M. abductor cruris anterior*

THE LION PLATE 1

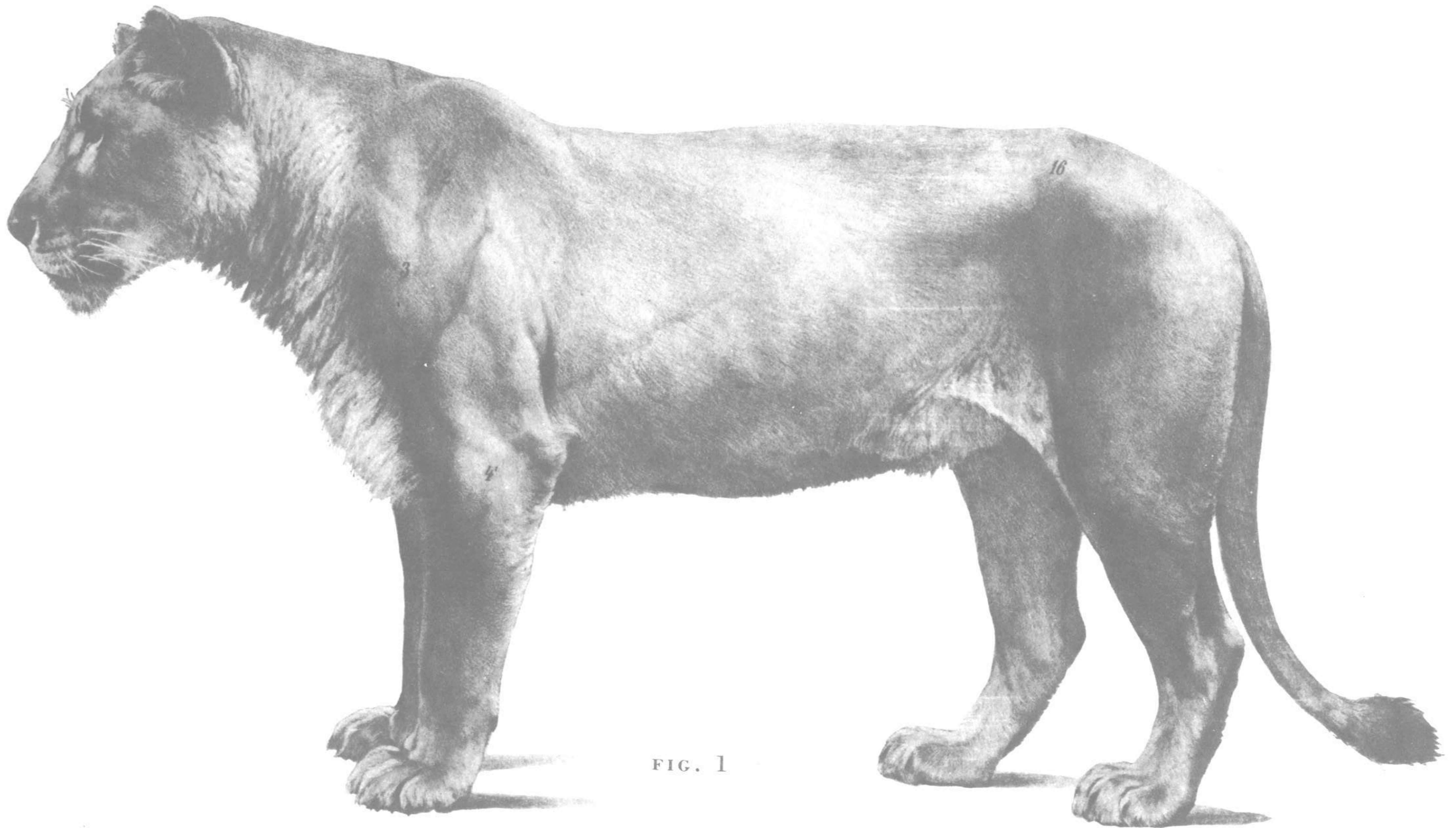


FIG. 1

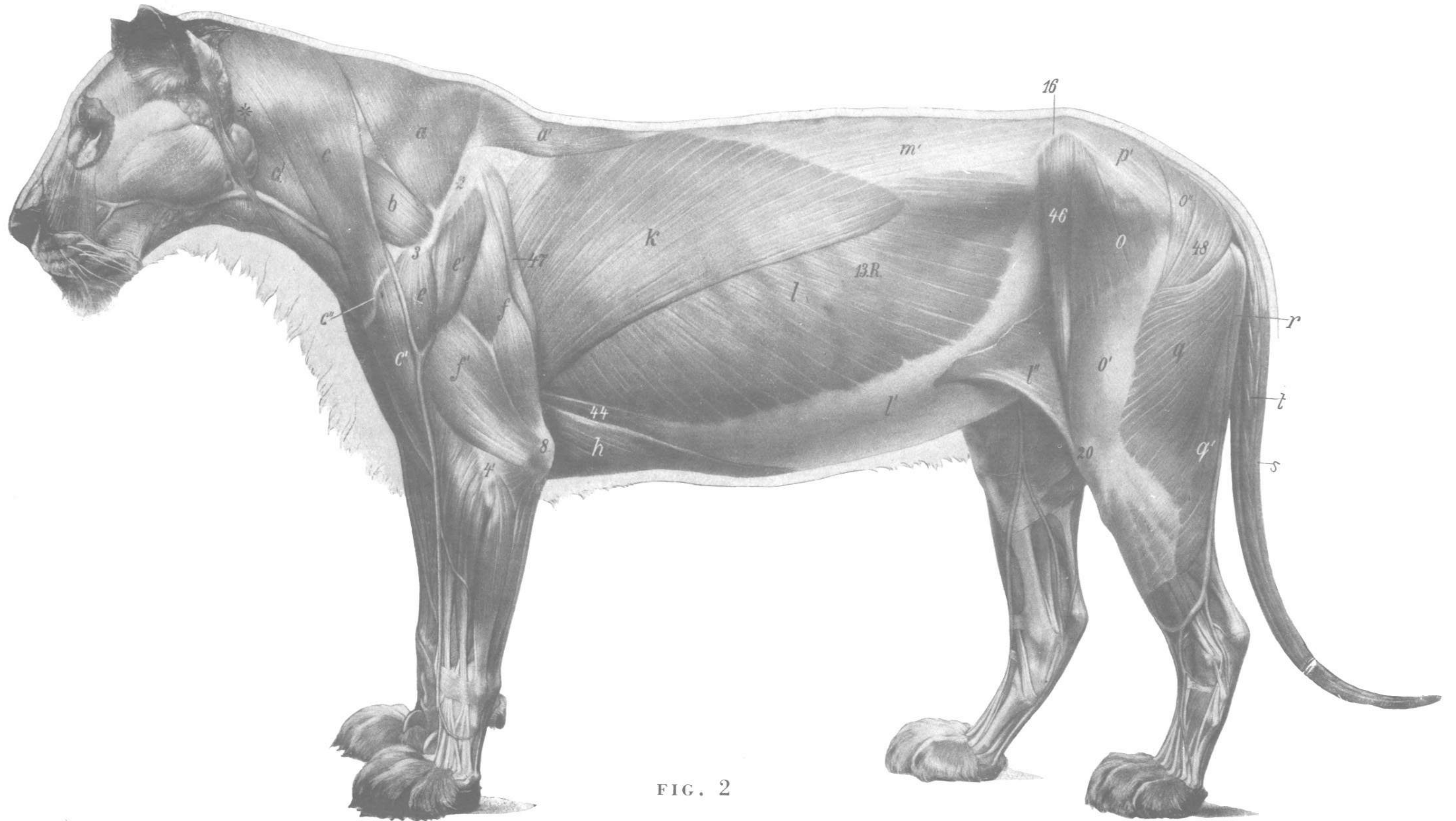


FIG. 2

THE LION PLATE 3

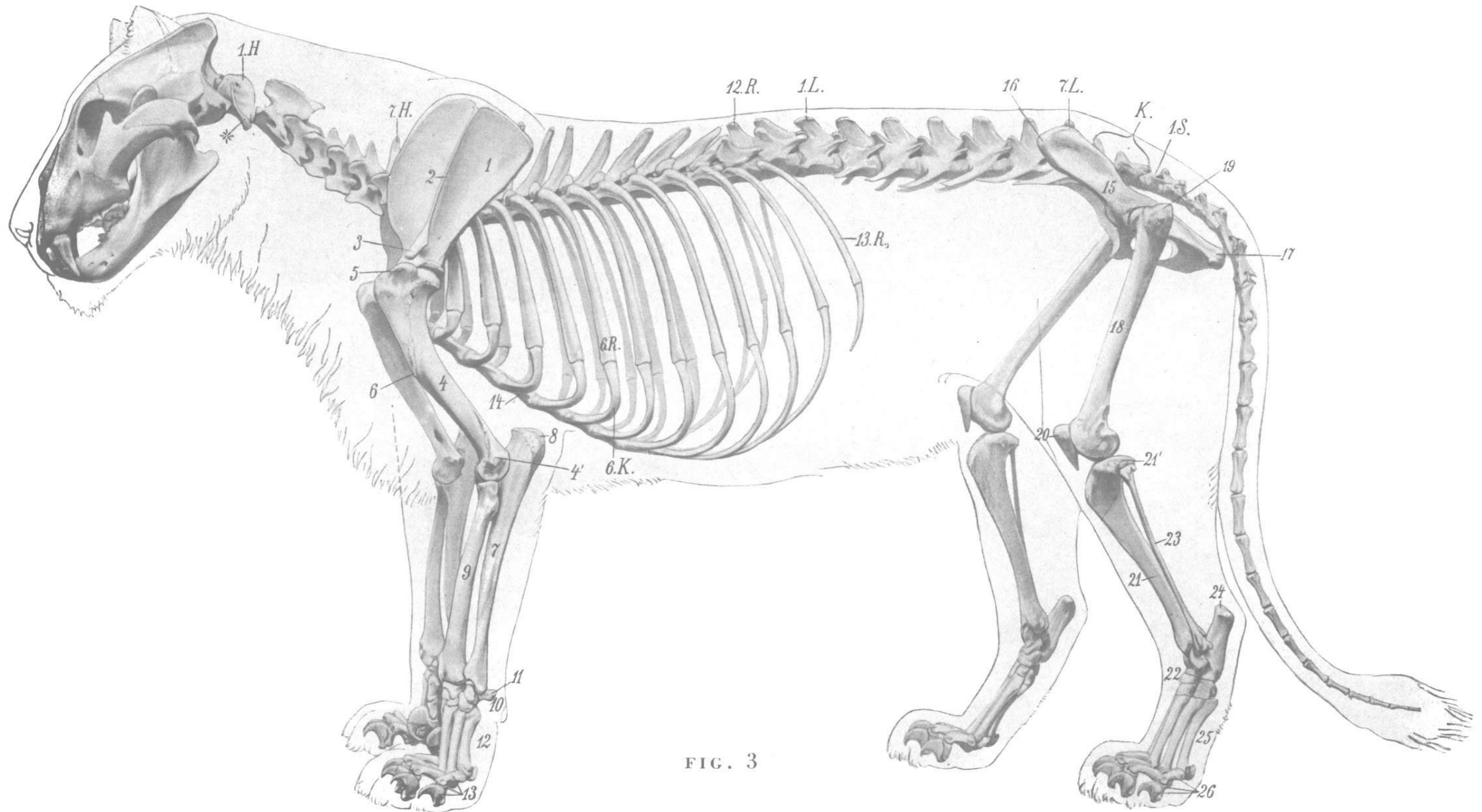


FIG. 3

THE LION PLATE 4

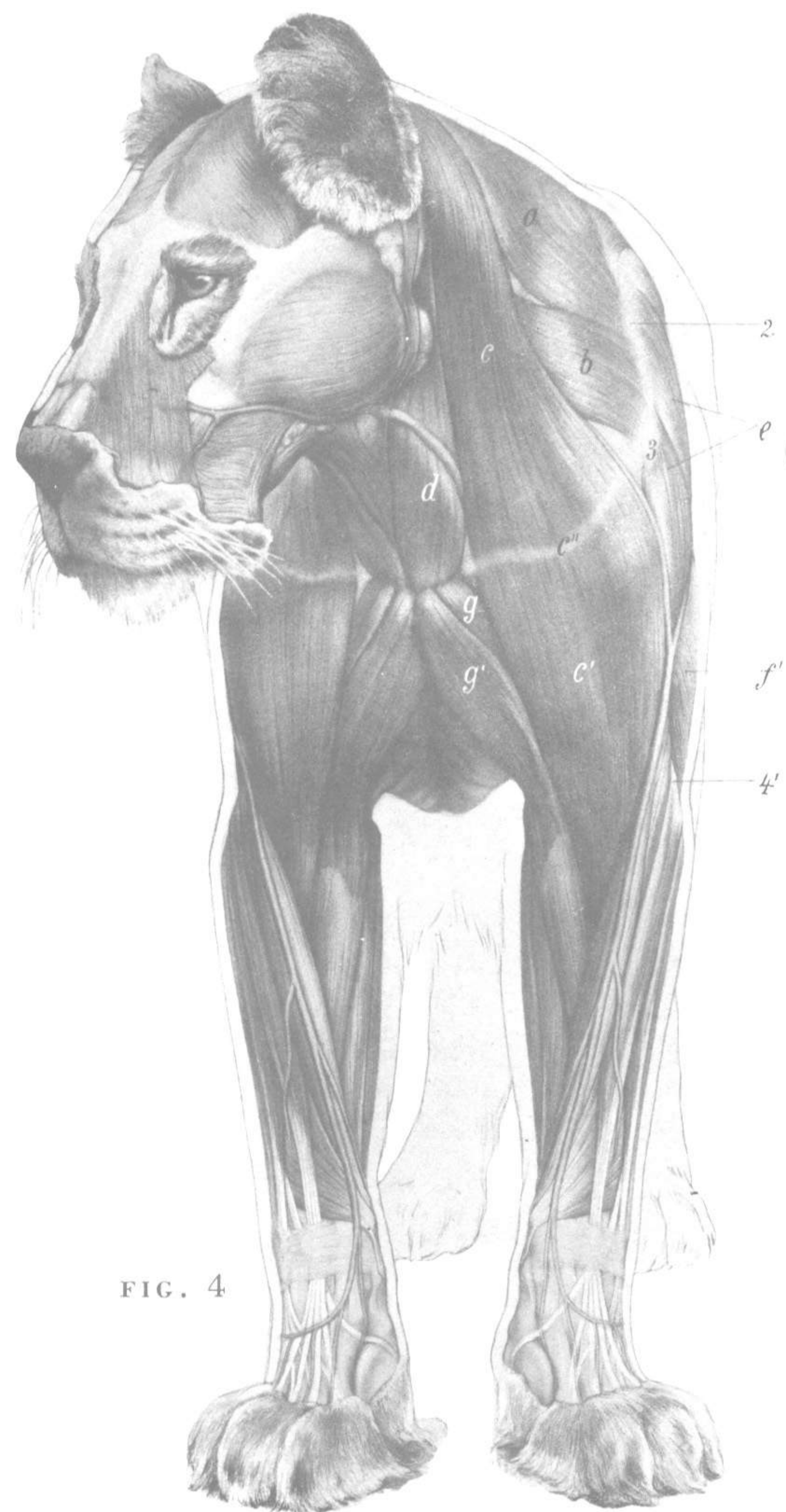

FIG. 4

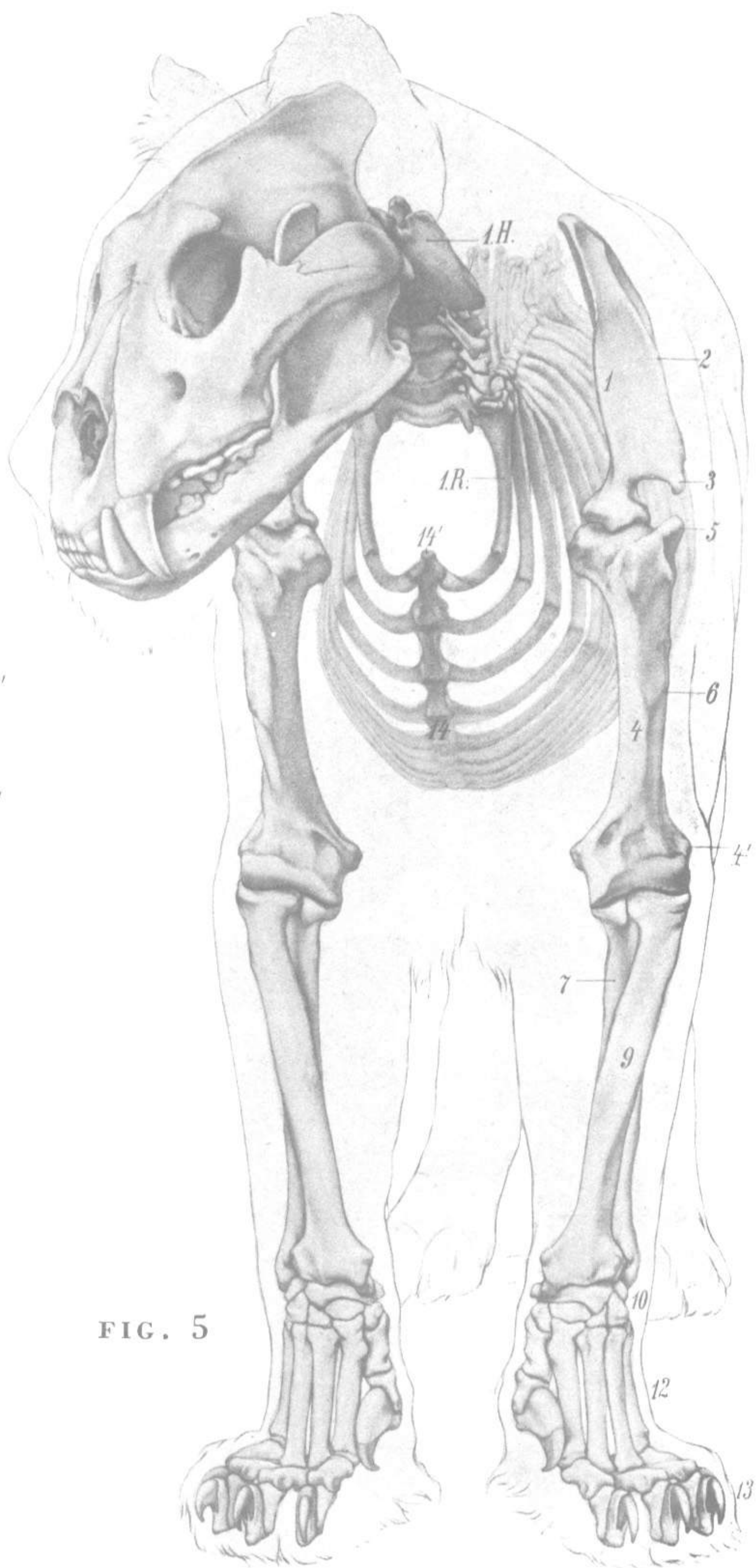


FIG. 5

THE LION PLATE 5

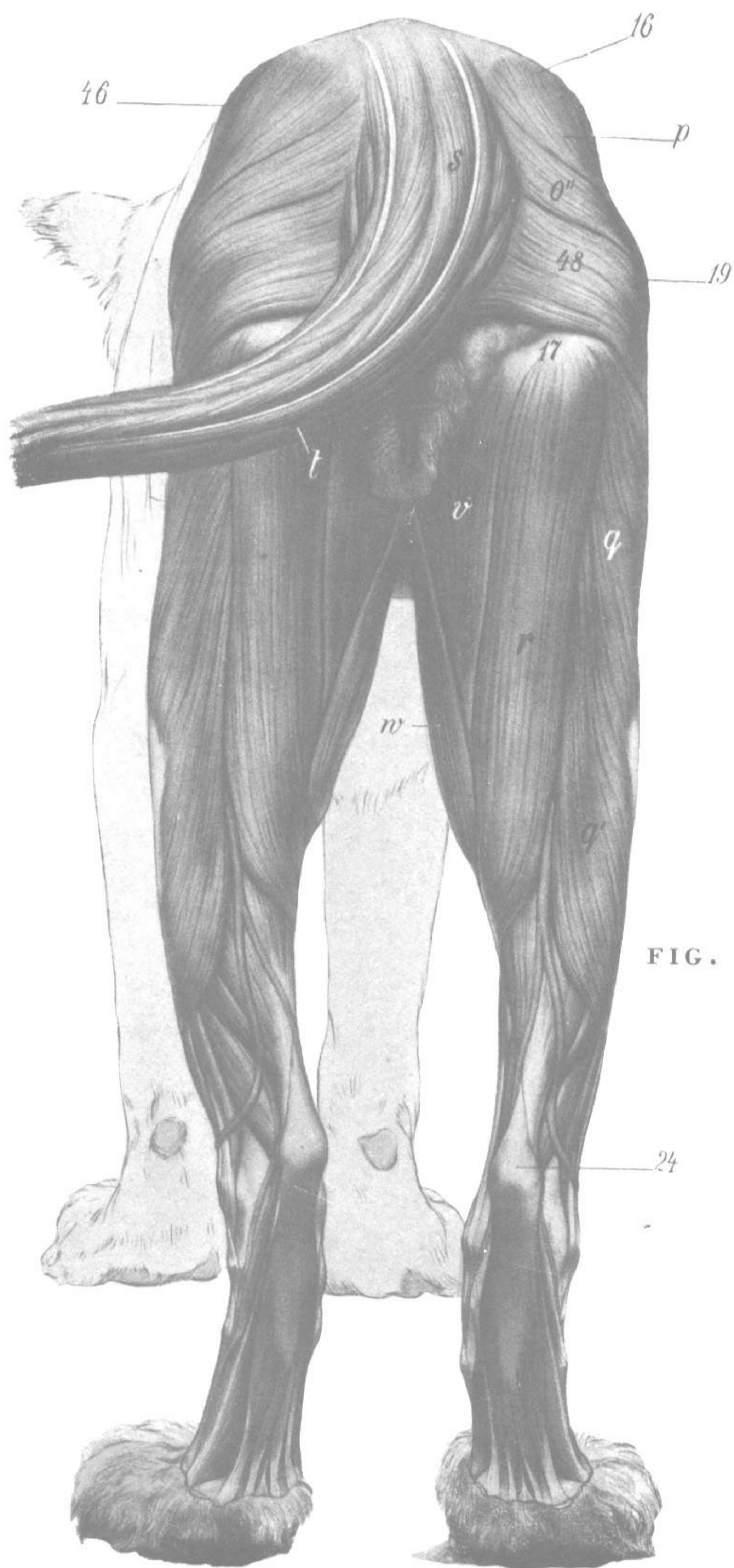


FIG. 6

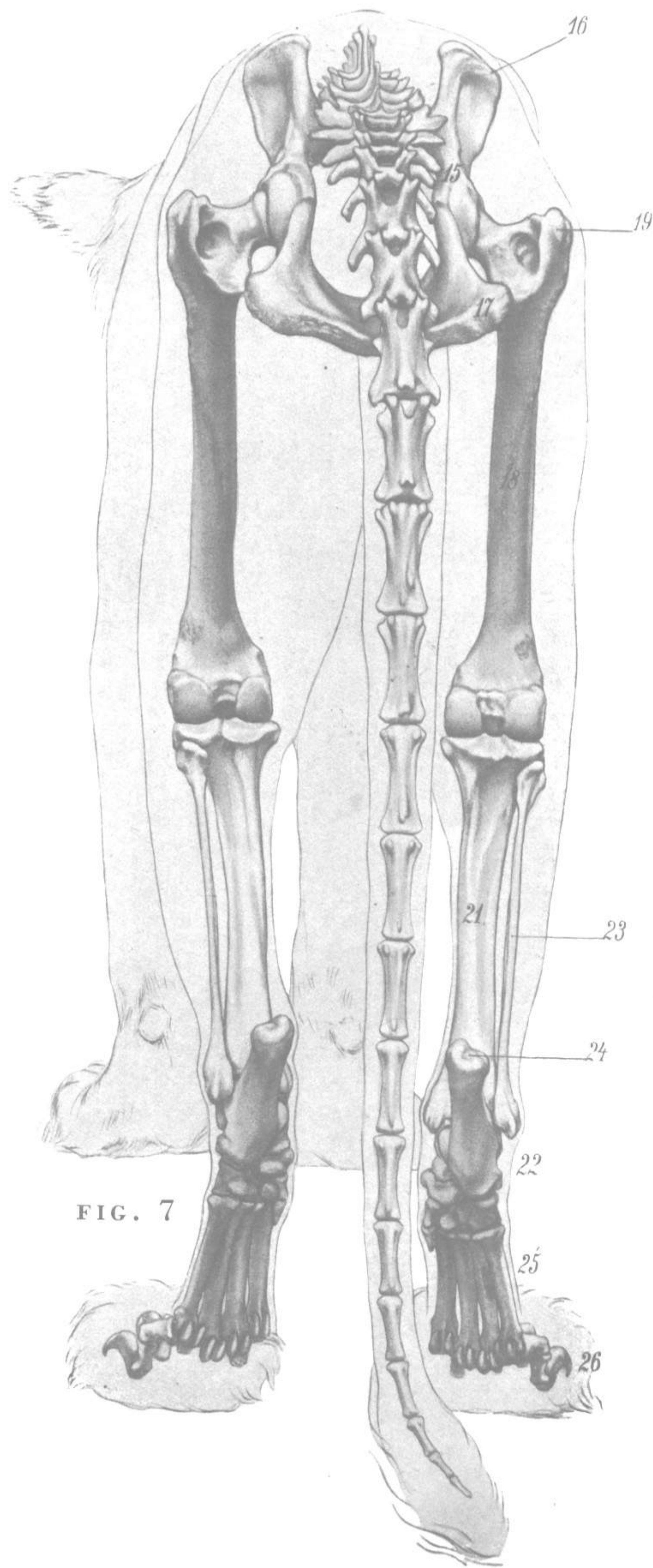


FIG. 7

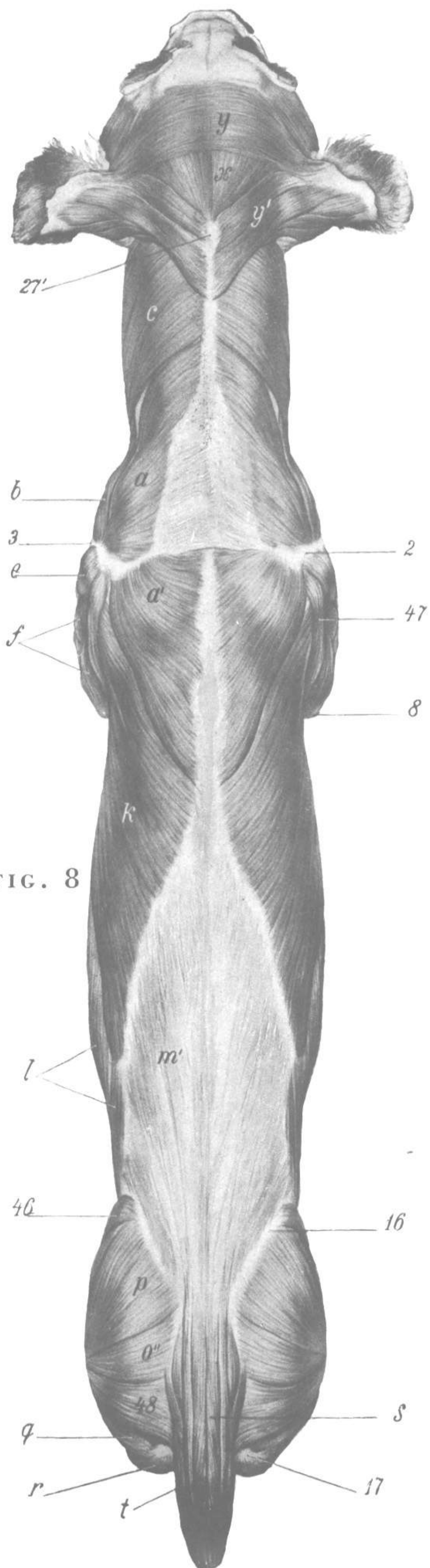


FIG. 8

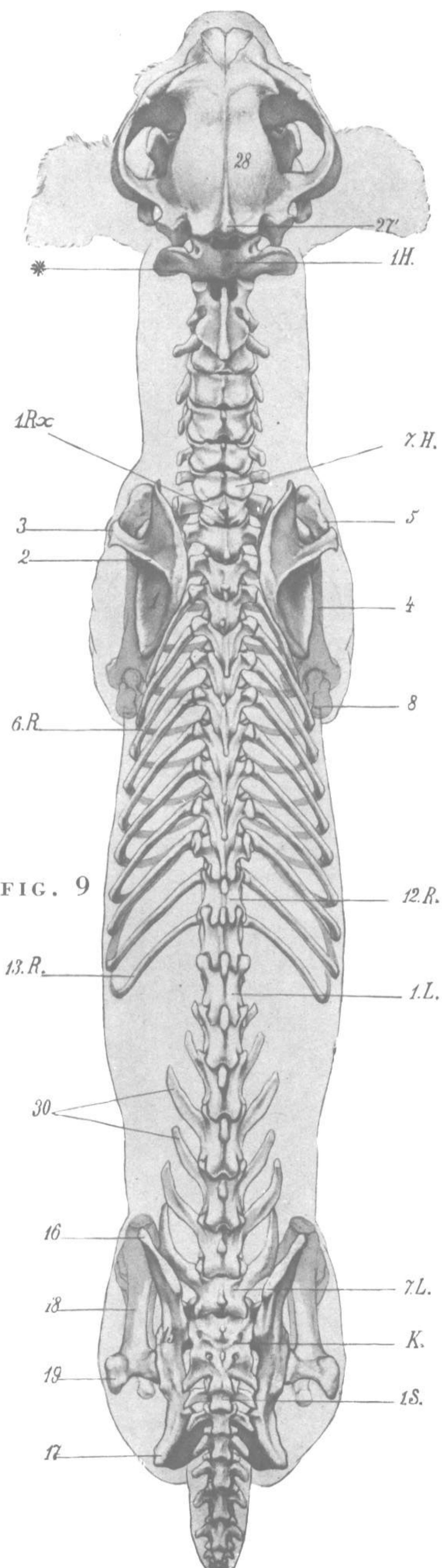


FIG. 9

THE LION - PLATES 7 8 9

FIGURES 10 11 12 13 14 15 16 17 18 19 20 21 22

a, a'—*M. extensor carpi radialis*
 c—*M. extensor digitorum communis*
 c'—*Tendons on phalanx of toe*
 d—*M. extensor digitorum lateralis s. digiti quinti proprius*
 e—*M. extensor carpi ulnaris*
 f—*M. abductor pollicis longus*
 g—*End of the M. brachialis internus*
 g'—*End of the M. pectoralis major*
 h—*One of the Mm. interossei*
 h'—*Extensor tendon*
 i—*Flexor tendons*
 k—*M. flexor carpi radialis*
 l, l'—*M. flexor carpi ulnaris*
 m—*M. flexor digitorum sublimis*
 m'—*Tendons from M. flexor digitorum sublimis*

o—*Parts of the M. flexor digitorum profundus*
 q—*M. extensor pollicis et indicis proprius*
 r—*M. brachioradialis*
 s—*M. anconaeus parvus*
 t—*M. pronator teres*
 u—*M. plantaris brevis*
 v—*M. abductor digiti quinti*
 w—*A strong elastic ligament*
 x—*Caput mediale of the M. triceps brachii*
 y—*Plantar balls*
 y'—*Digital balls*
 4—*Humerus*
 4'—*Its extensor condyle*
 4''—*Its flexor condyle*
 7—*Ulna*

7'—*Lower end of the ulna*
 8—*Olecranon*
 9—*Radius*
 9''—*Tuberositas radii lateralis*
 10—*Carpus*
 11—*Os pisiforme*
 12—*Metacarpus*
 15—*Sesamoid bones of the 3rd & 4th metatarsal digital joint*
 16—*Phalanx prima*
 17—*Phalanx secunda*
 17'—*Ball-like beginning of ligament connecting phalanx secunda with phalanx tertia*
 18—*Phalanx tertia*
 19—*Ring-shaped fold of skin*

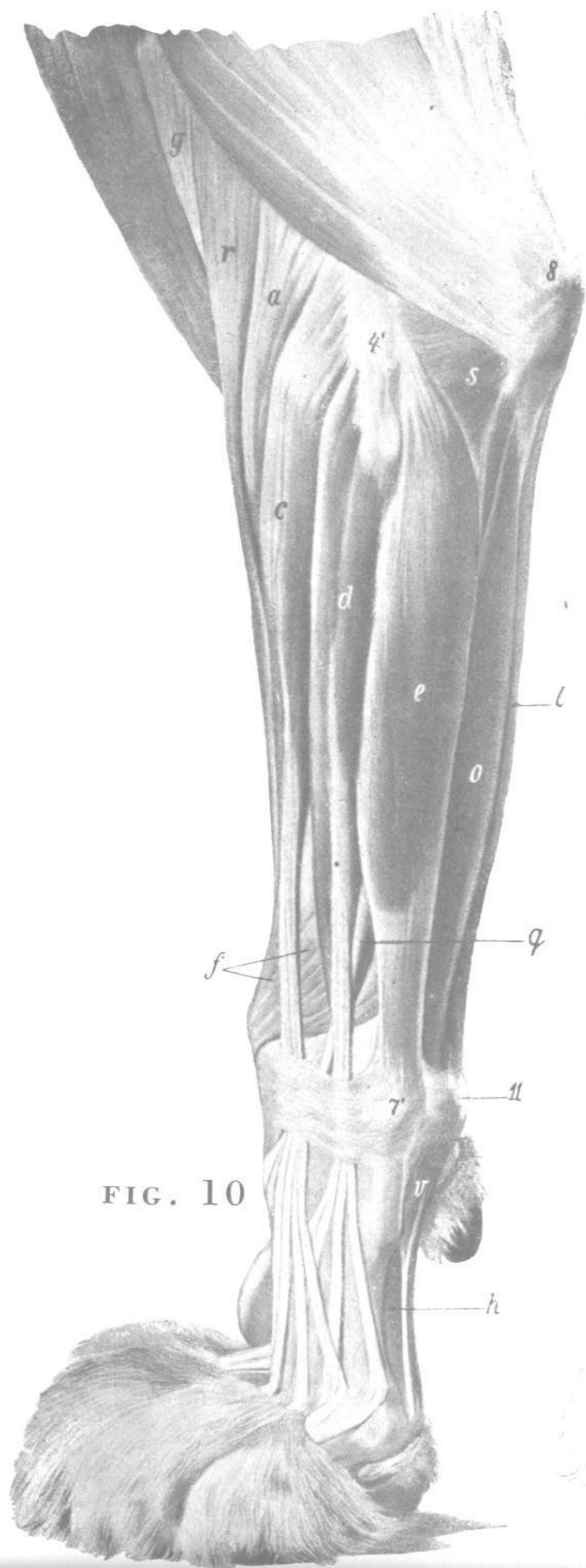


FIG. 10

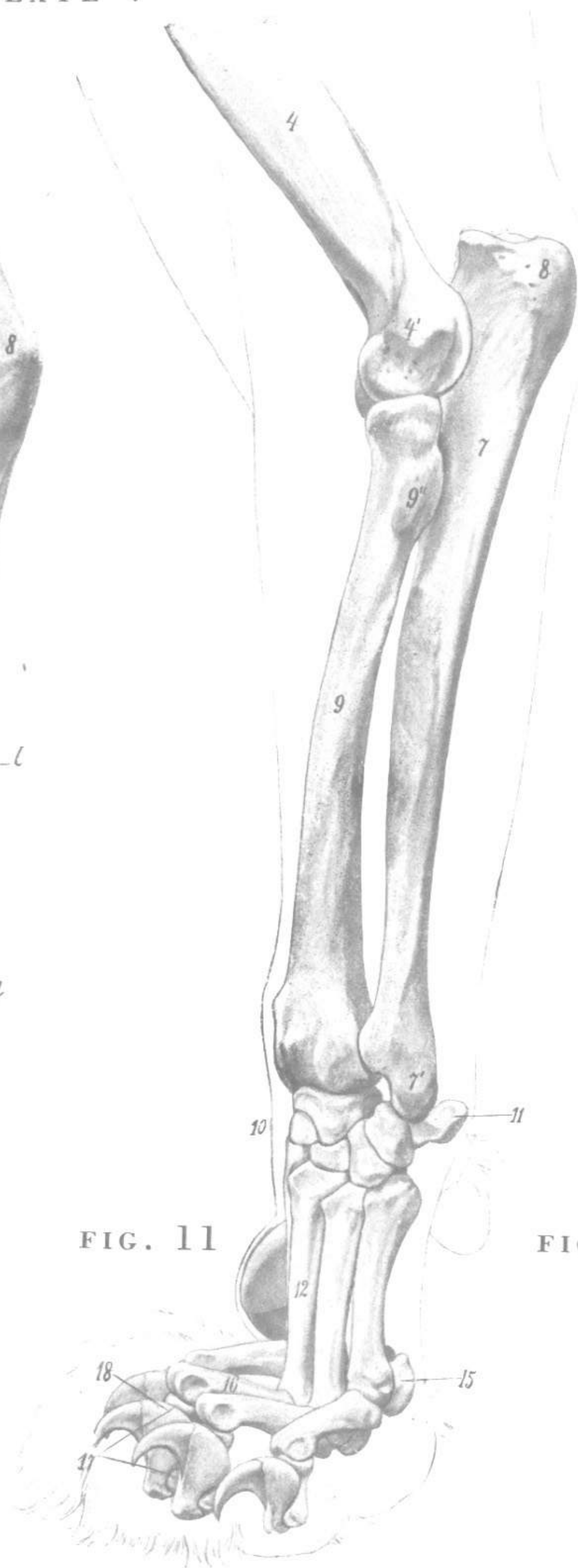

FIG. 11

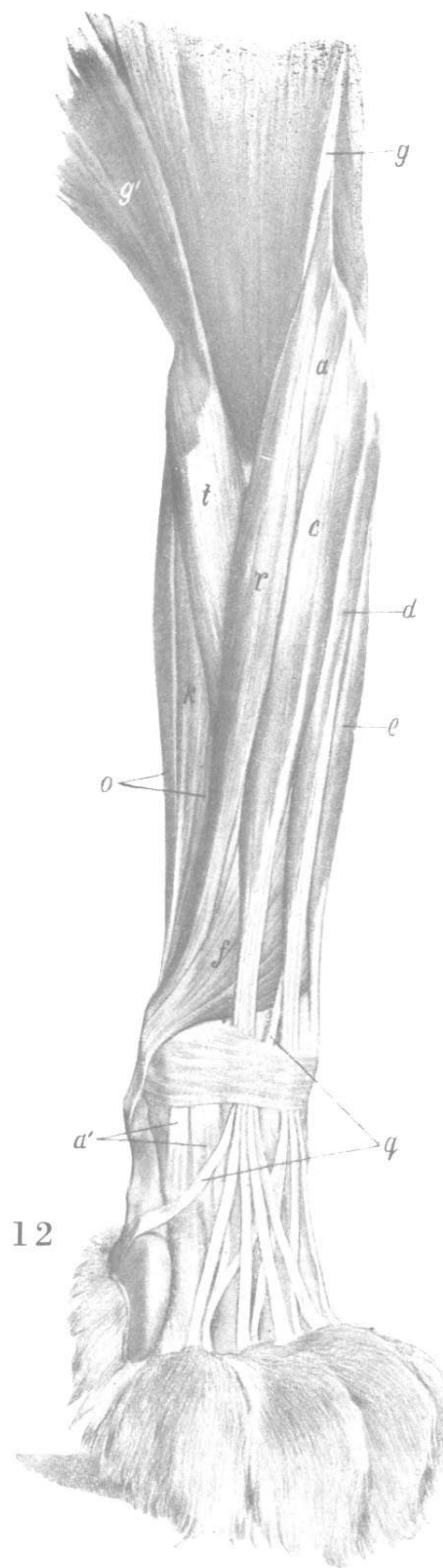


FIG. 12

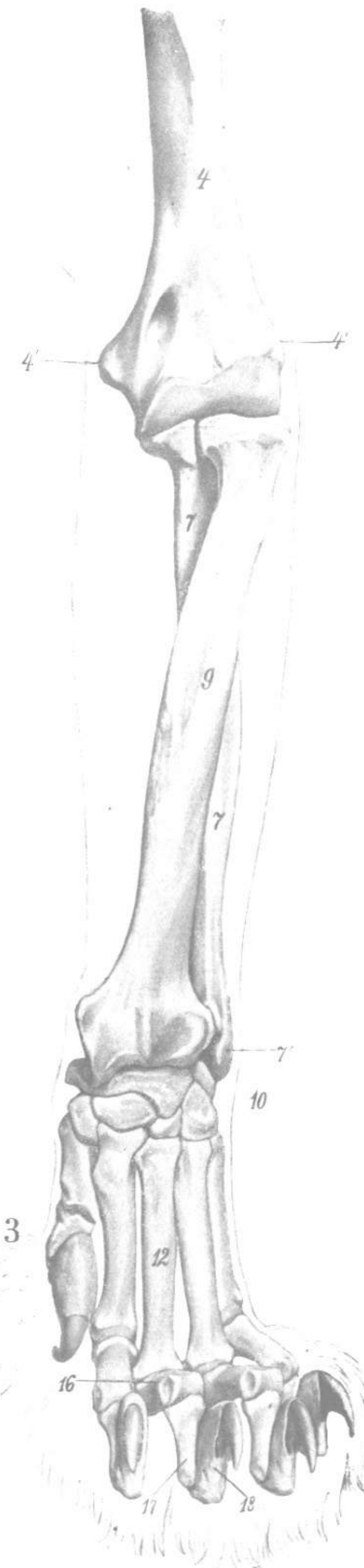


FIG. 13

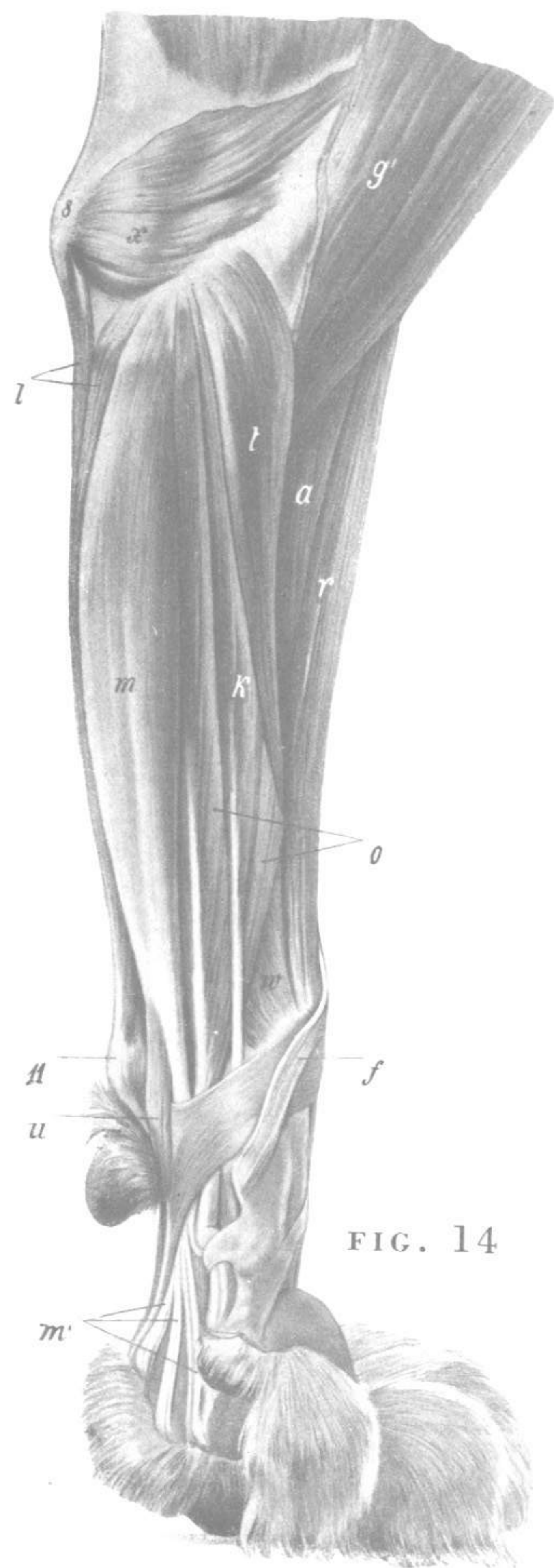


FIG. 14

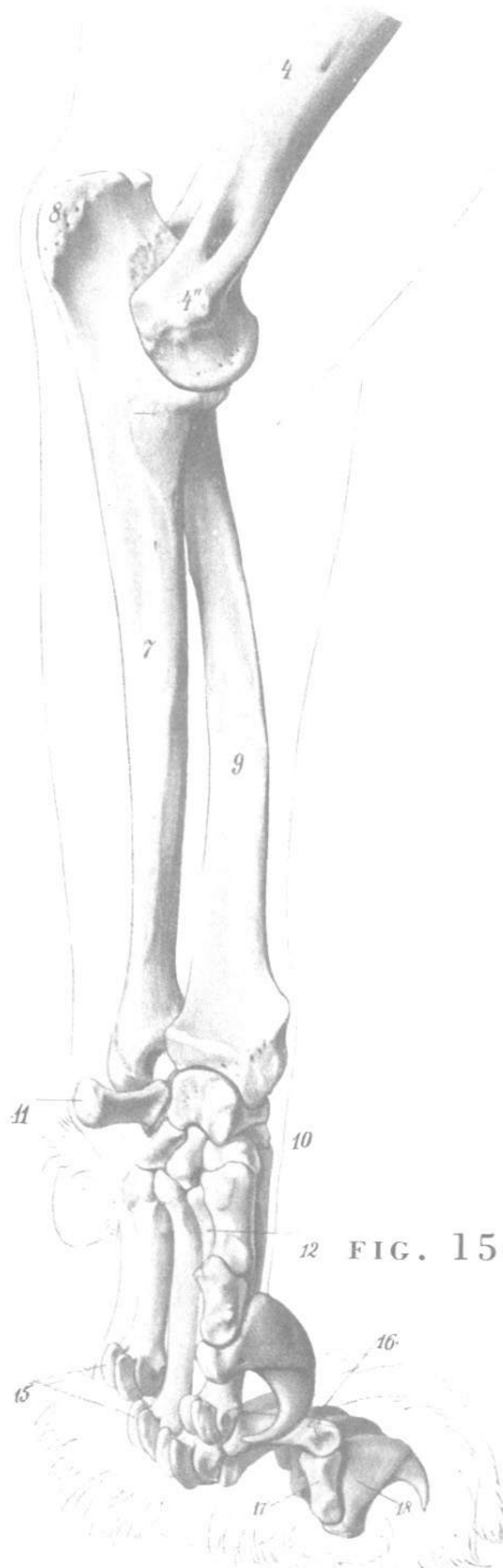


FIG. 15

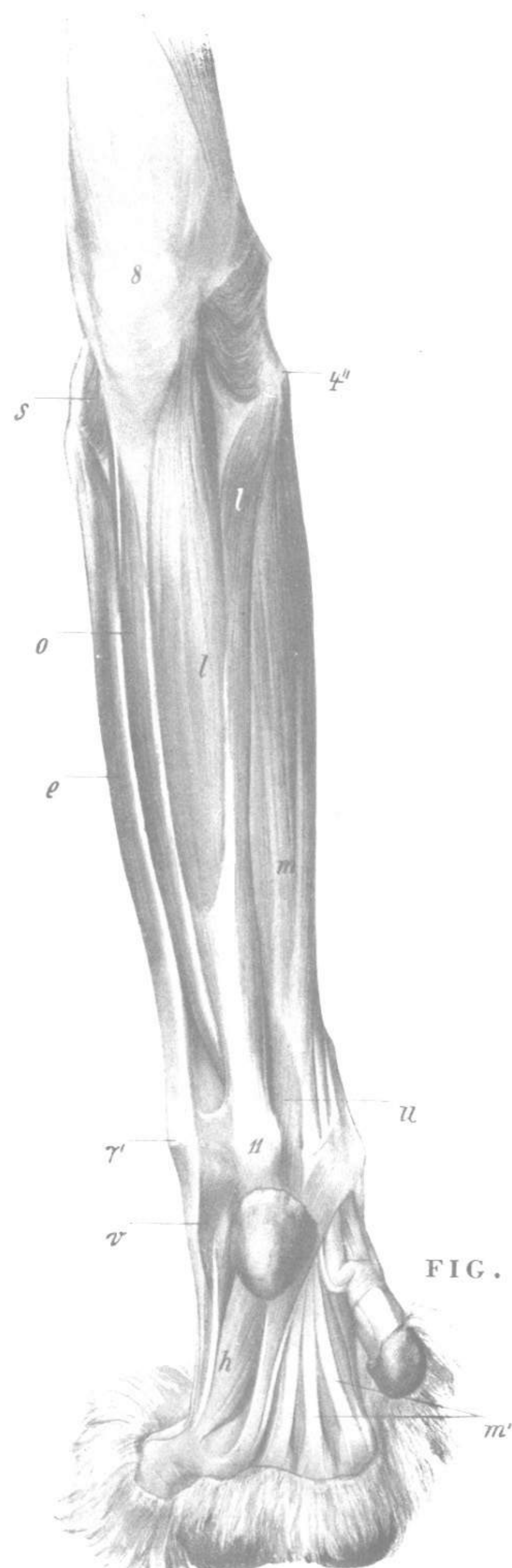


FIG. 16

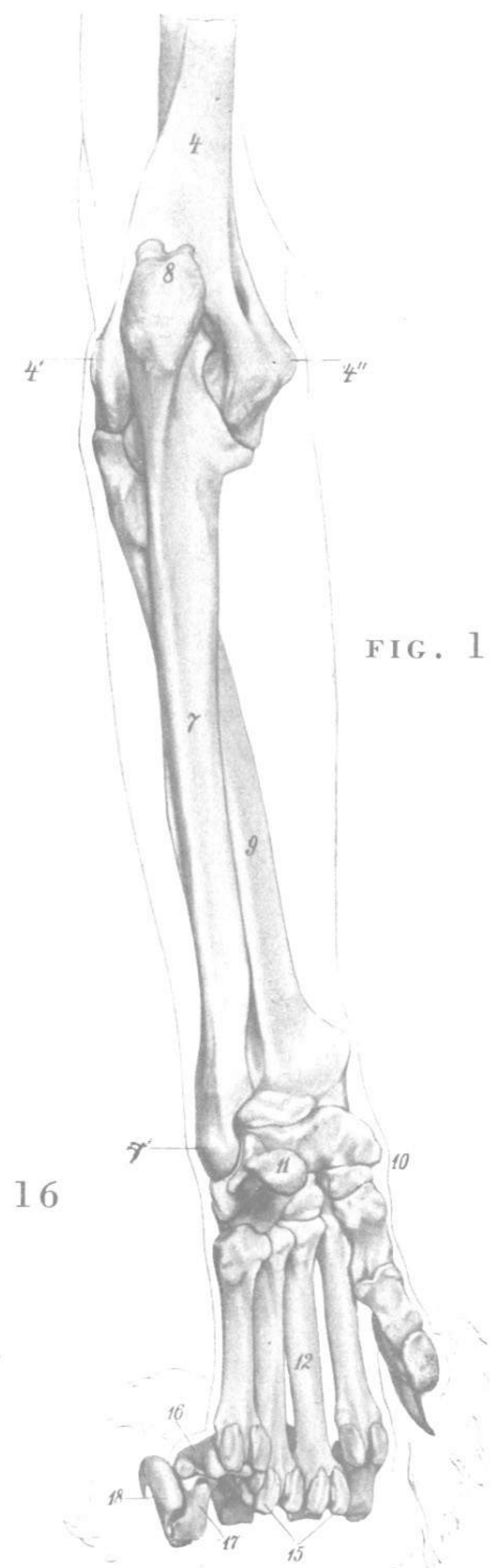


FIG. 17

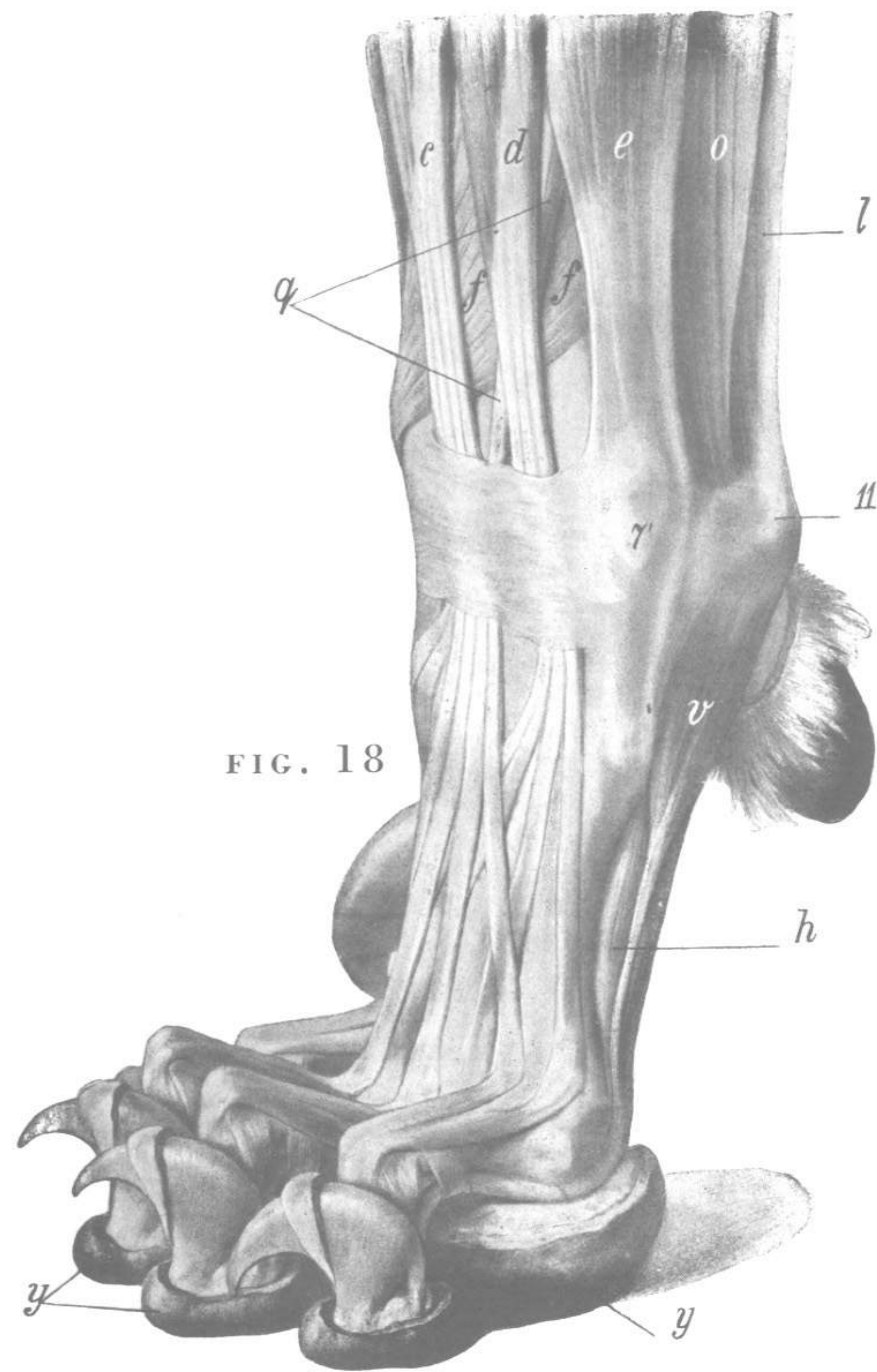


FIG. 18

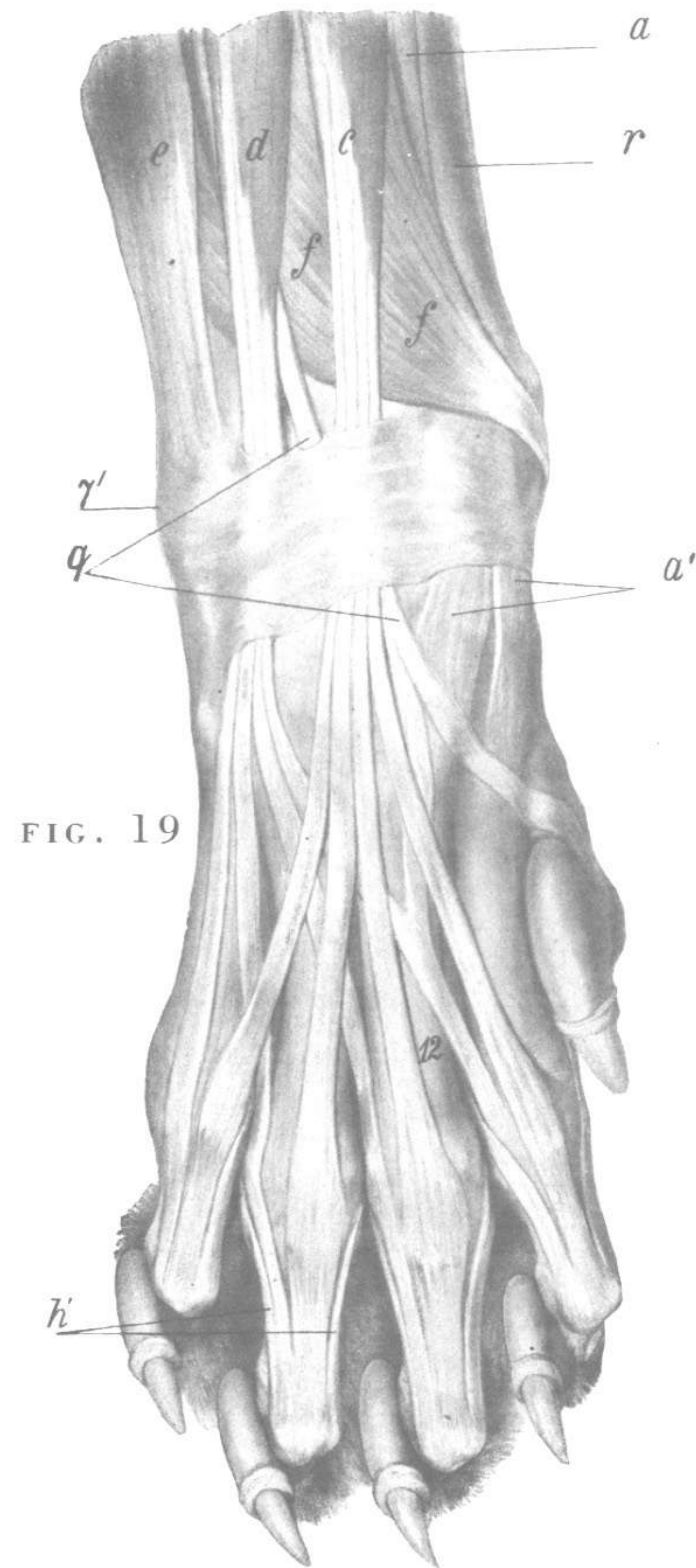


FIG. 19

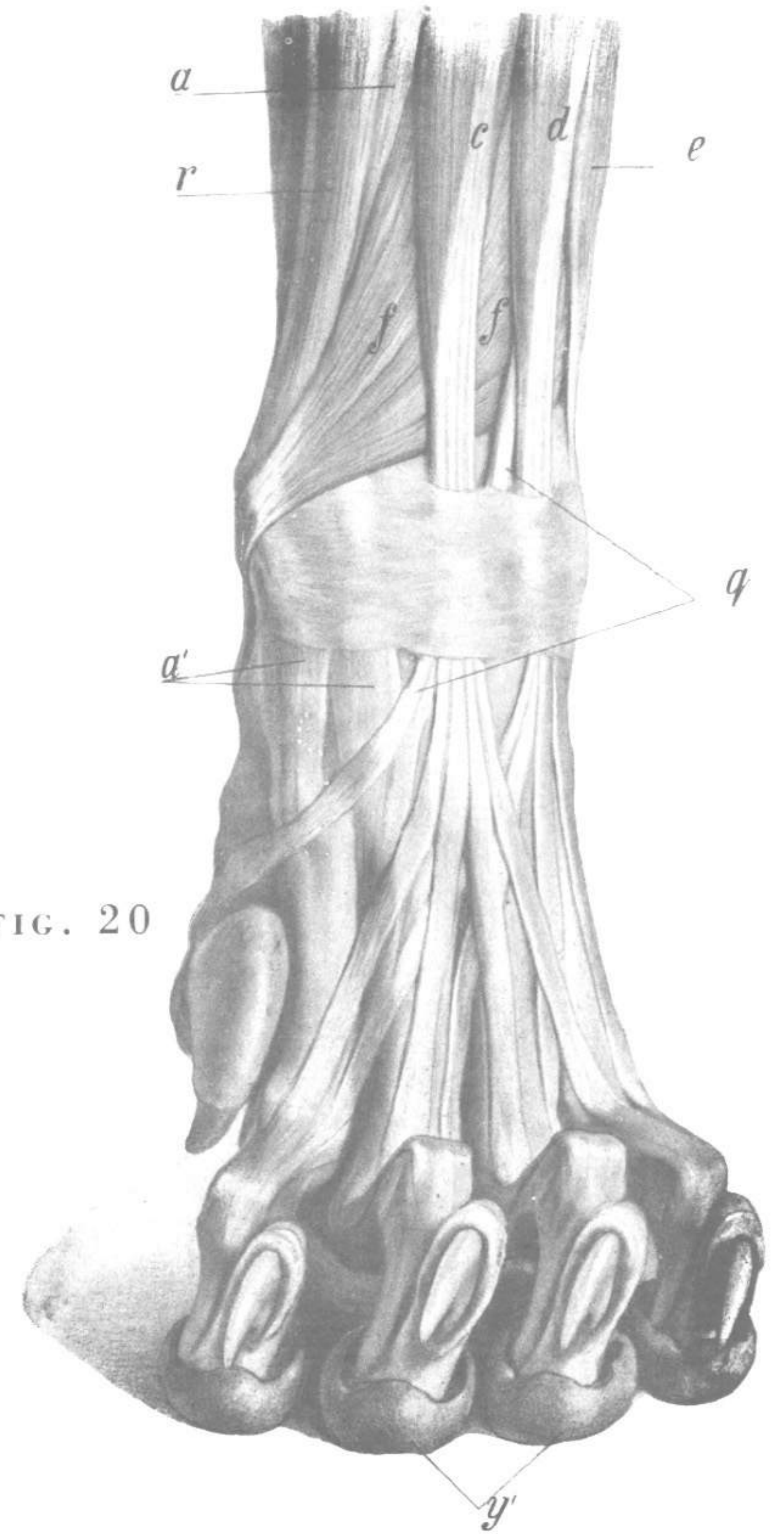


FIG. 20

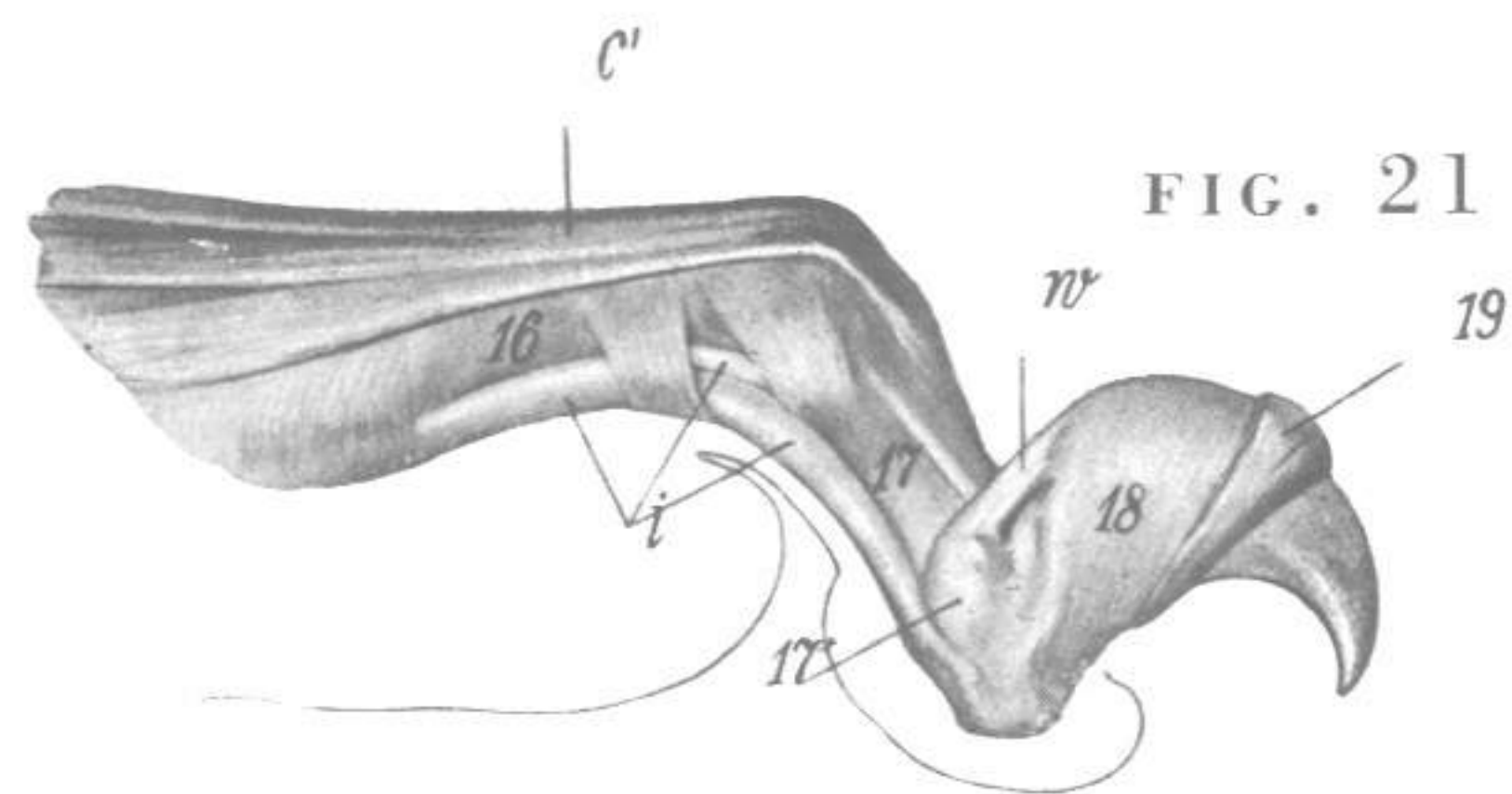


FIG. 21

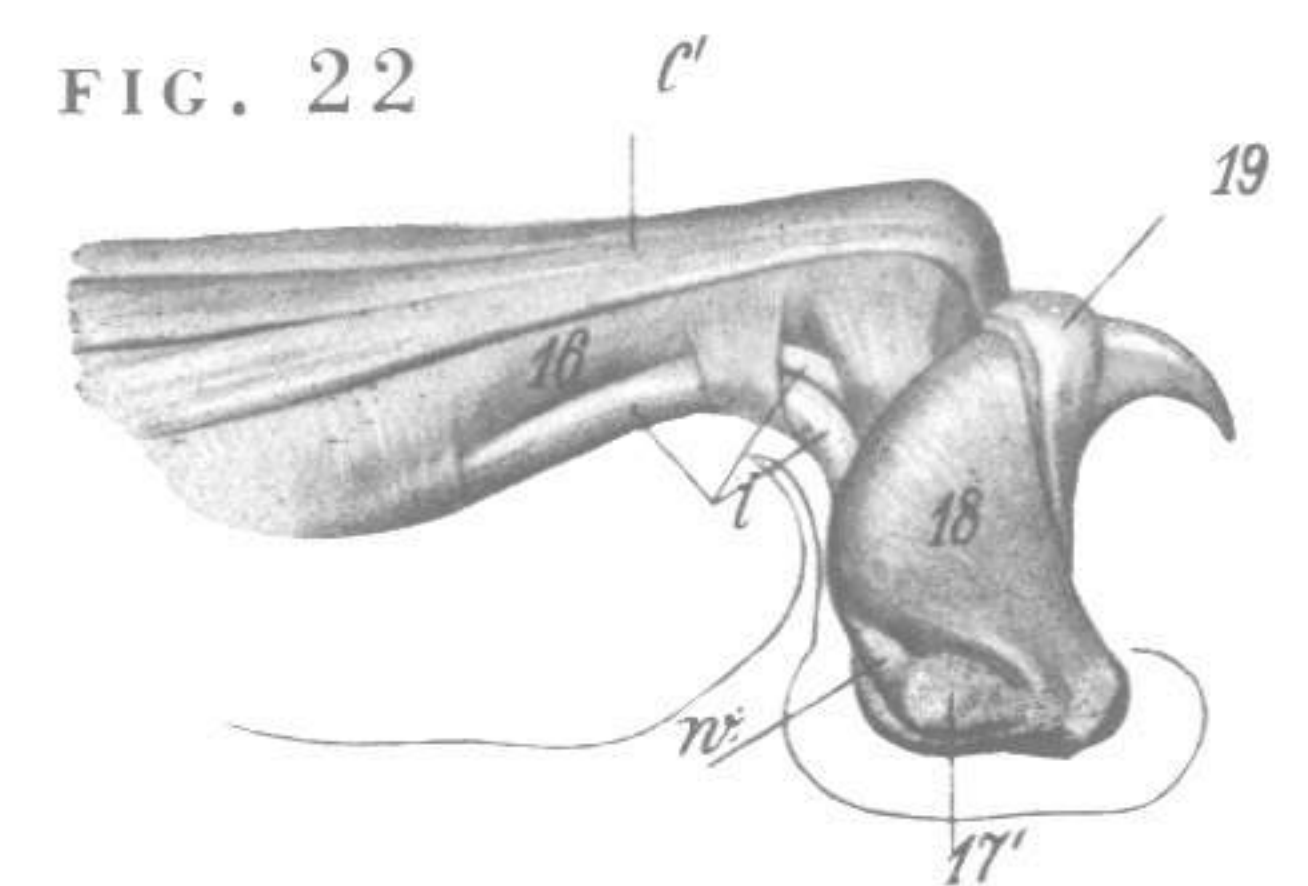


FIG. 22

THE LION - PLATE 10

FIGURES 23 24 25 26 27

A—Plantar balls
 B, B'—Digital balls
 C—Tarsal balls
 D—Joint between 1st and 2nd digit
 E, E'—East of the 3rd digit
 b—Shoulder-transverse-process muscle
 c, c', c''—*M. cleidomastoideus*
 d—*M. sternomandibularis*
 e, e'—*M. deltoideus*
 f, f'—*Caput longum et laterale of M. triceps
 brachii*
 h—Posterior part of *M. pectoralis minor*
 i—Thoracic portion of *M. serratus anterior*
 i'—Cervical portion of *M. serratus anterior*

k—*M. latissimus dorsi*
 l—*M. obliquus abdominis externus*
 m—*M. serratus posterior*
 o''—*M. glutaeus maximus*
 p—*M. glutaeus medius*
 q, q'—*M. biceps femoris*
 r—*M. semitendinosus*
 s—*Levator of the tail*
 t—*Mm. intertransversarii of the tail*
 x—Cervical portion of *M. rhomboideus*
 z—*M. supraspinatus*
 13R—13th rib
 2—*Spina scapulae*
 3—Acromion

8—*Olecranon*
 16—*Tuber coxae*
 20—*Patella*
 21'—*External condyle of tibia*
 28, 28'—*M. quadriceps femoris*
 30—*M. gastrocnemius*
 36—*Lumbar portion of M. longissimus dorsi*
 38—*Parts of origin of M. teres major*
 43—*M. transversus abdominis*
 44—*Incipient part of the M. rectus abdominis*
 44'—*End of M. rectus abdominis*
 46—*M. sartorius*
 47—*M. tensor fasciae antebrachii*
 48—*M. abductor cruris anterior*

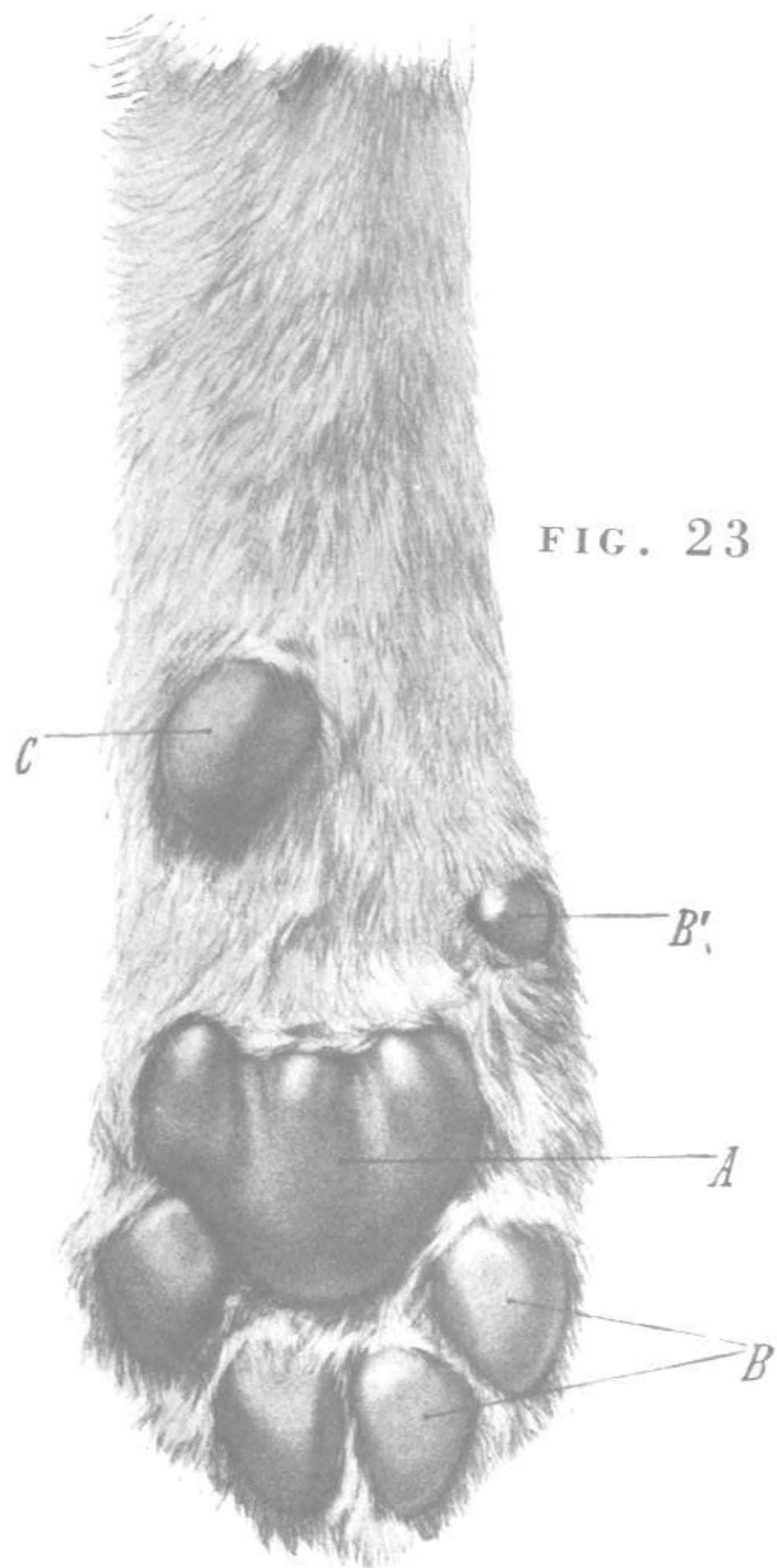


FIG. 23

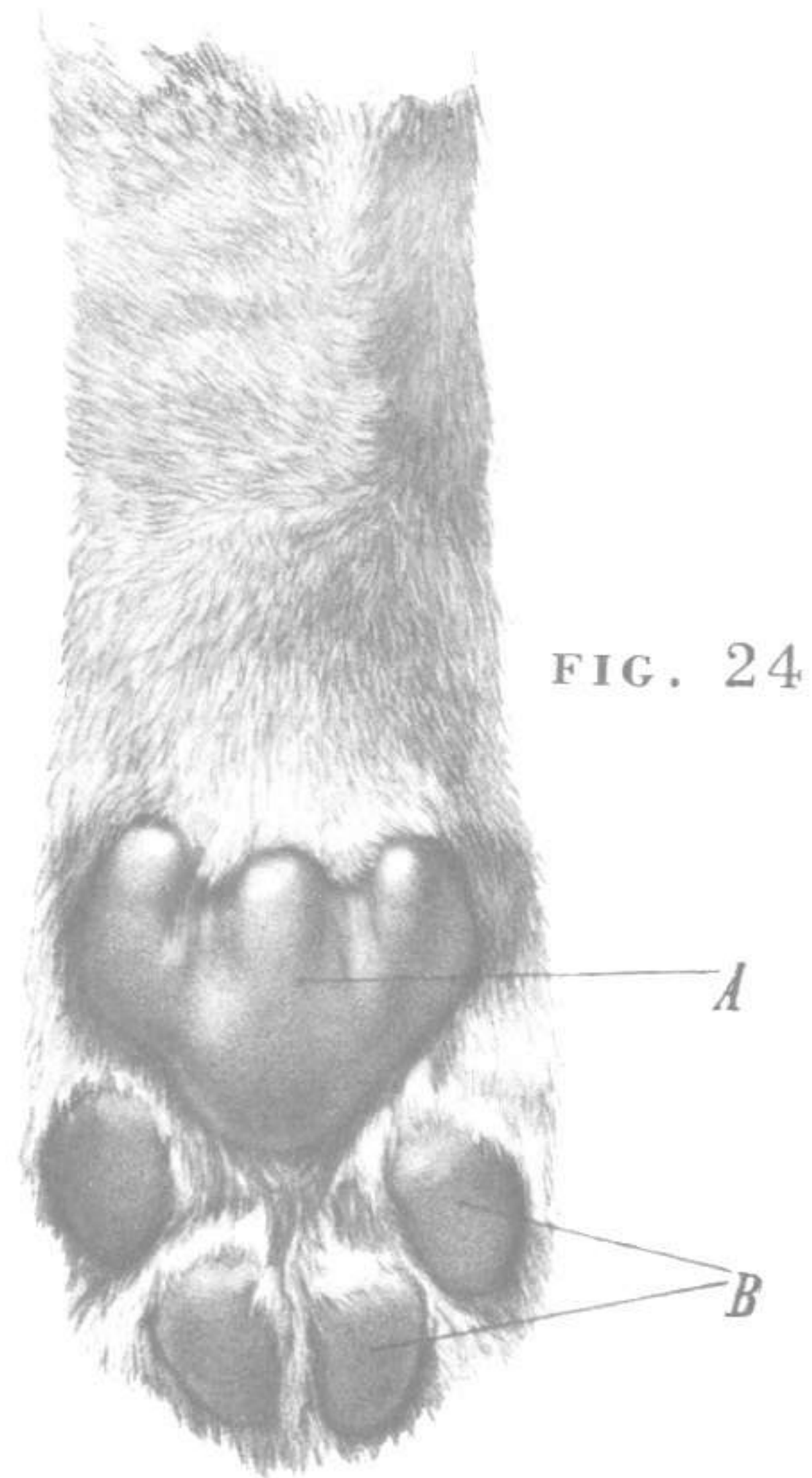


FIG. 24

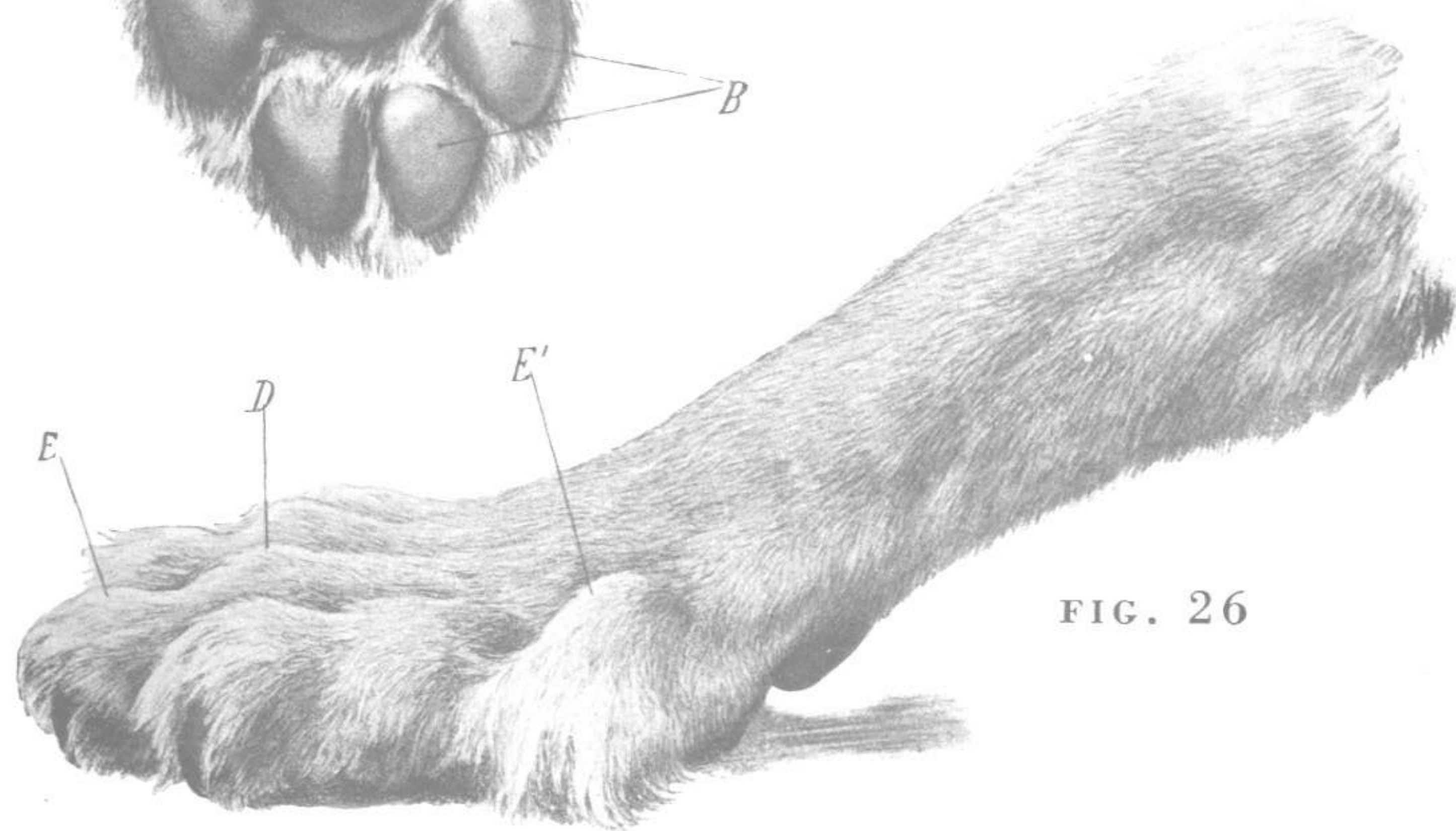


FIG. 26

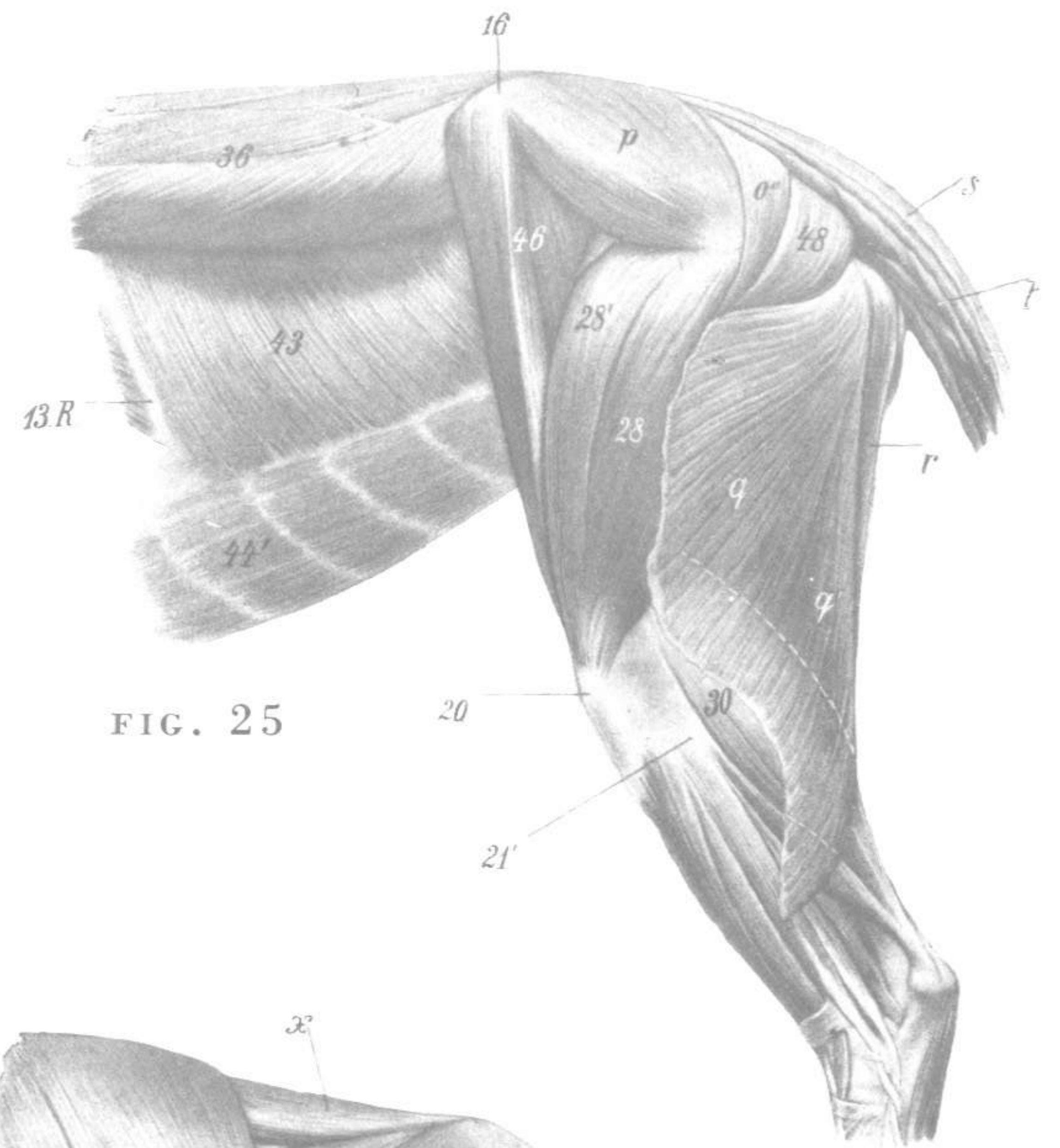


FIG. 25

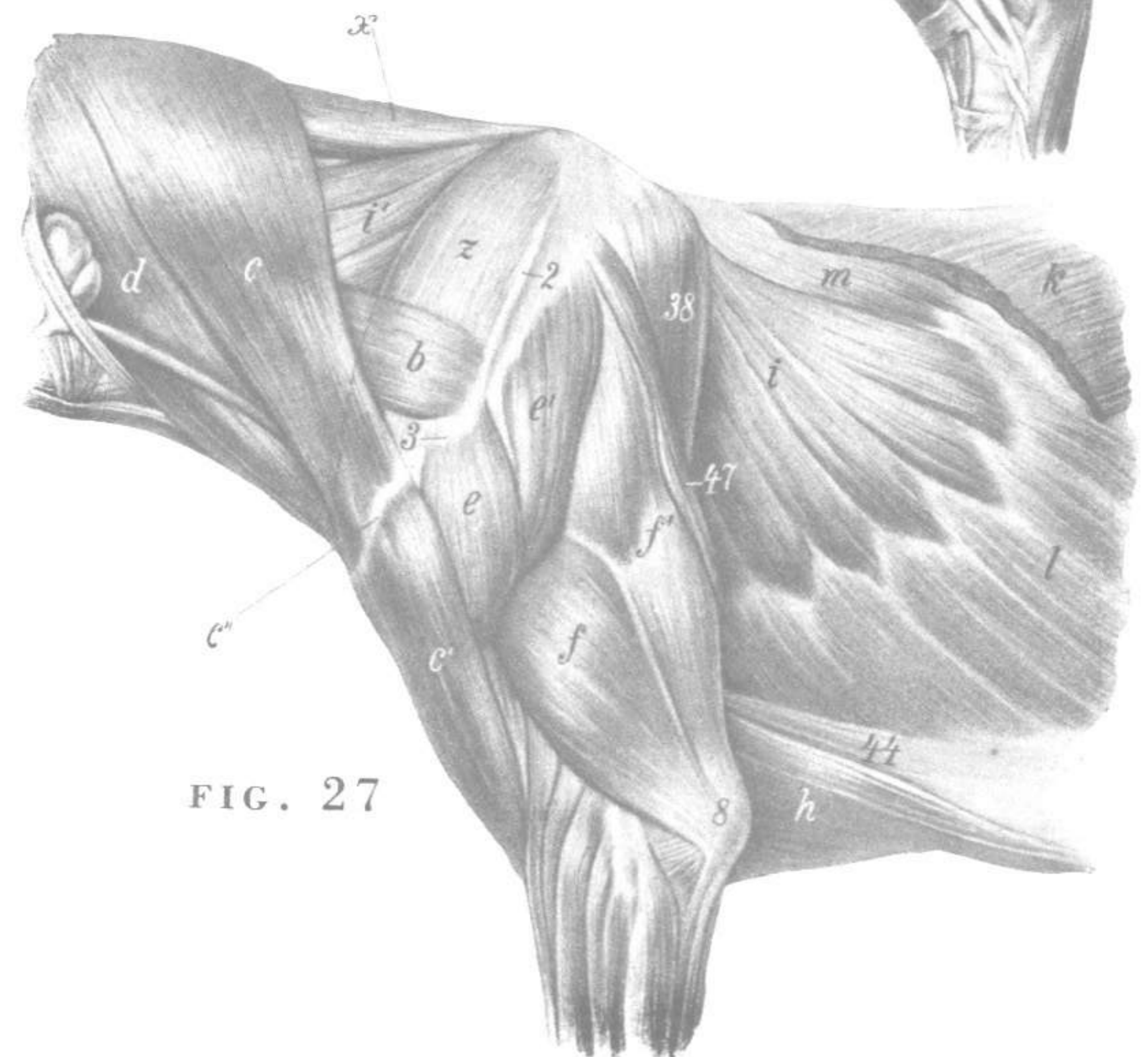
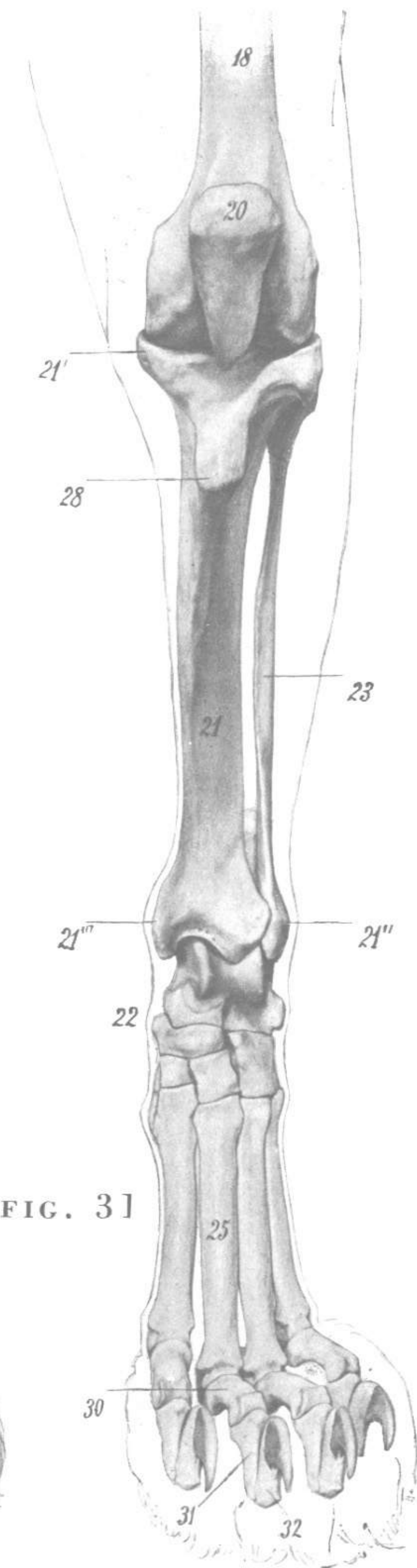
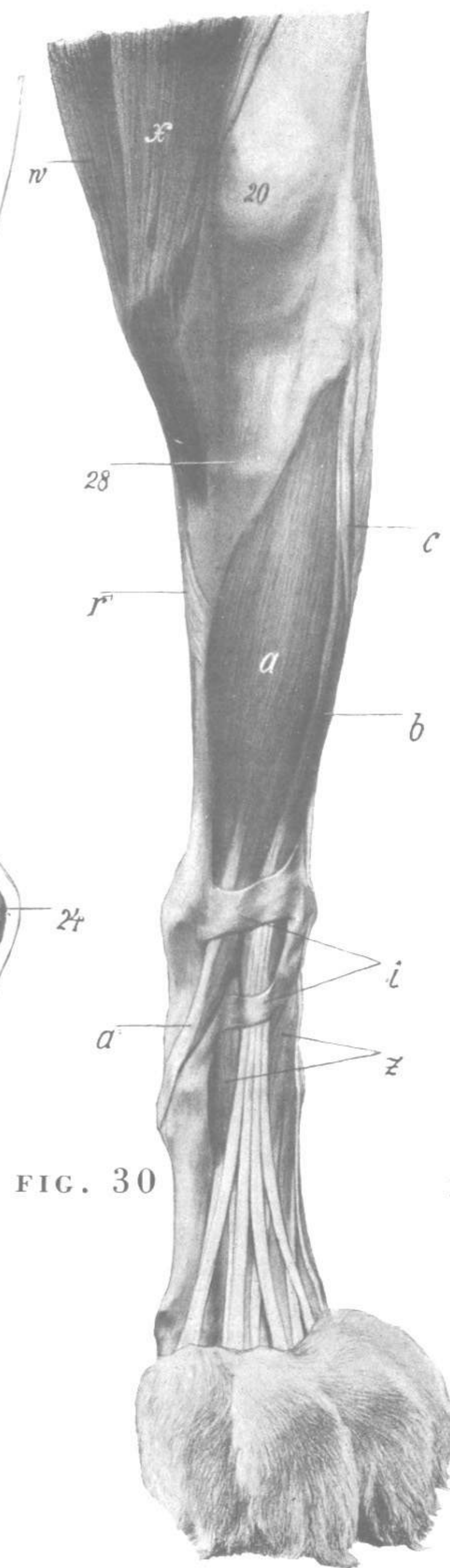
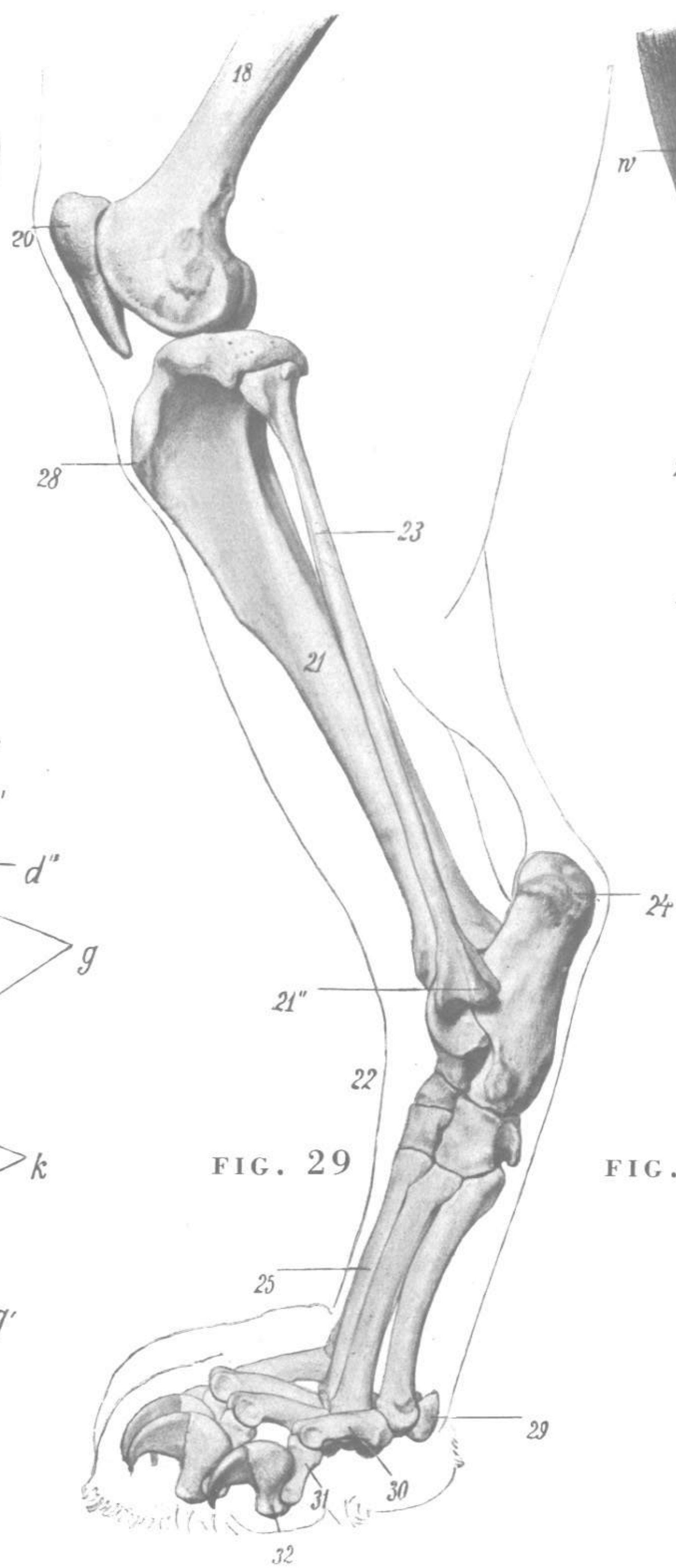
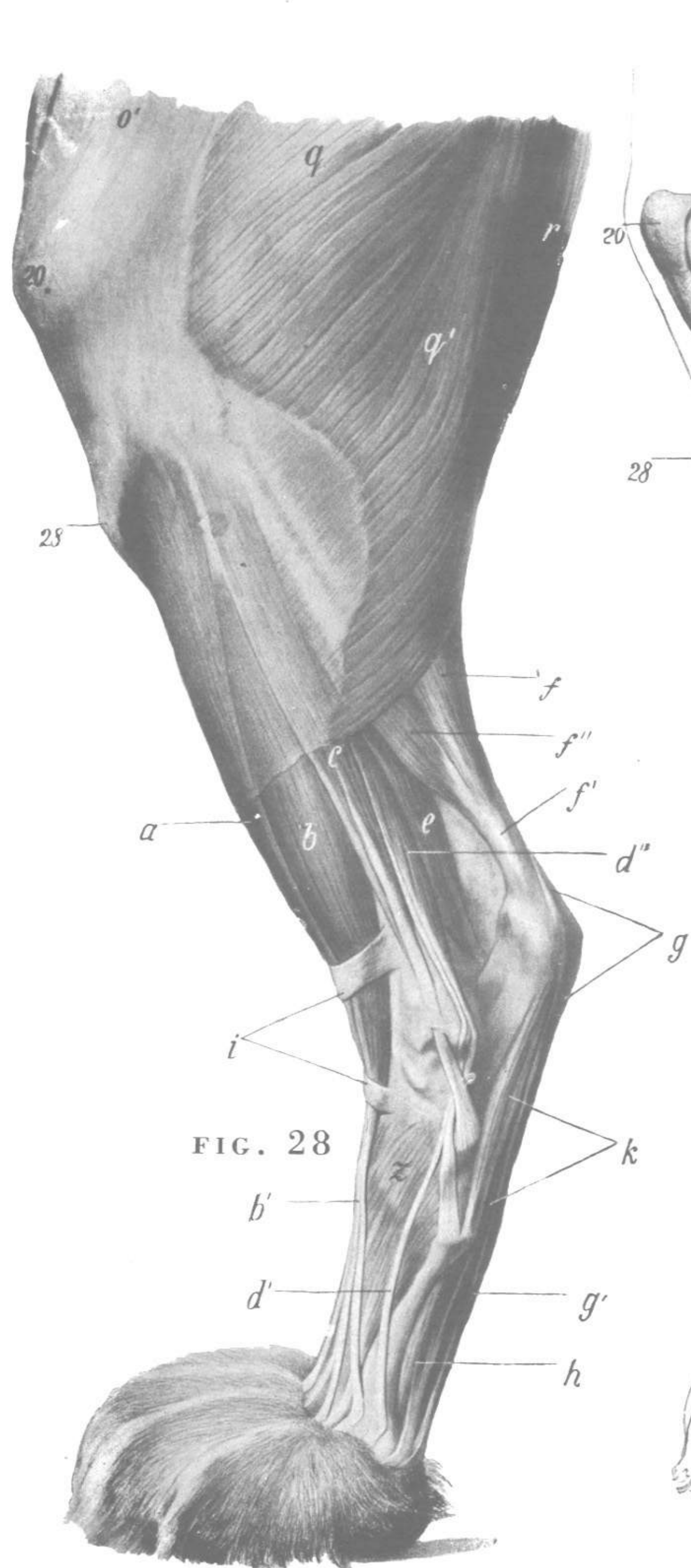


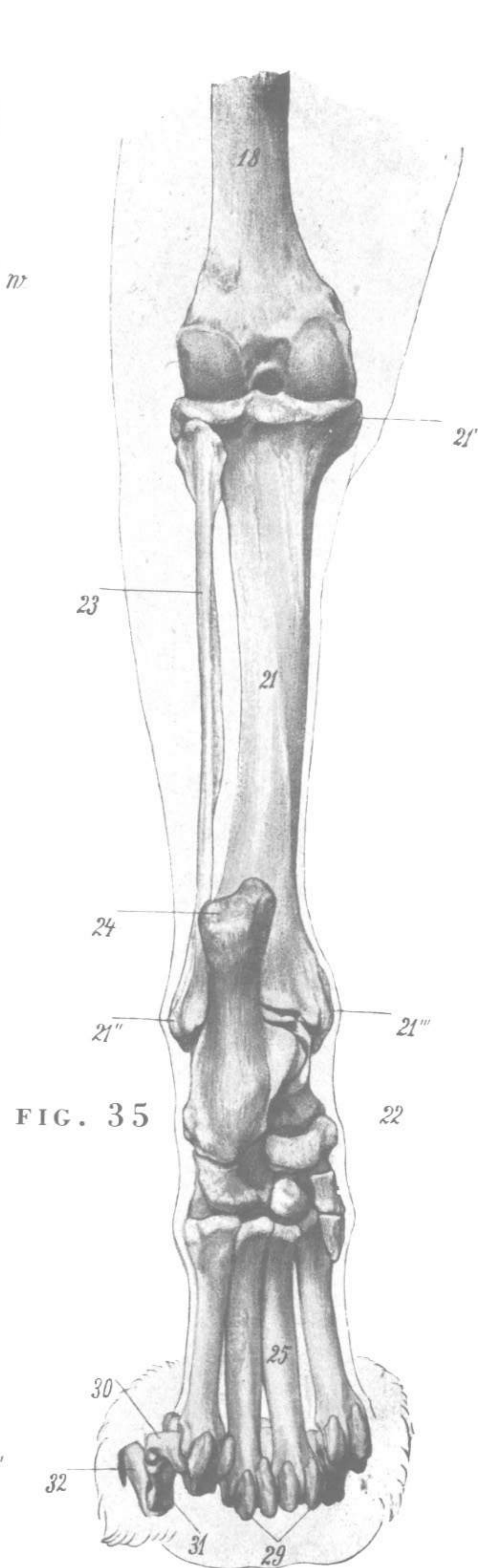
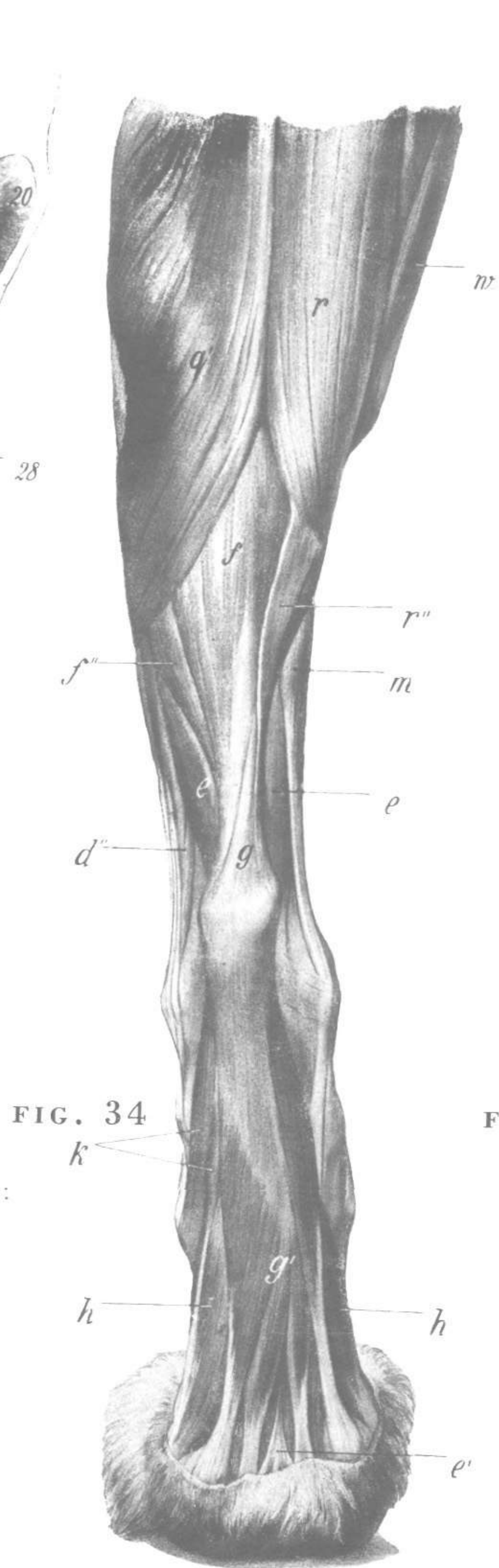
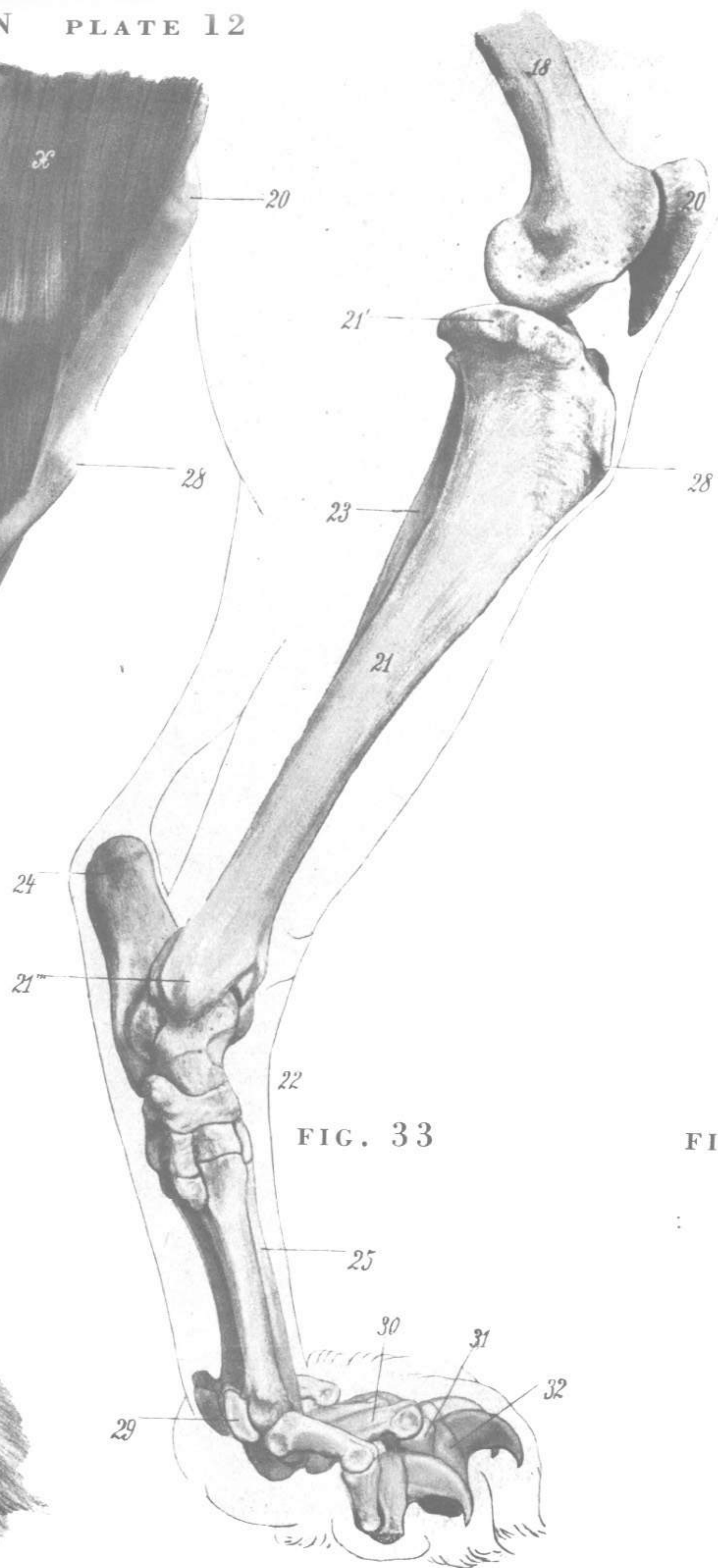
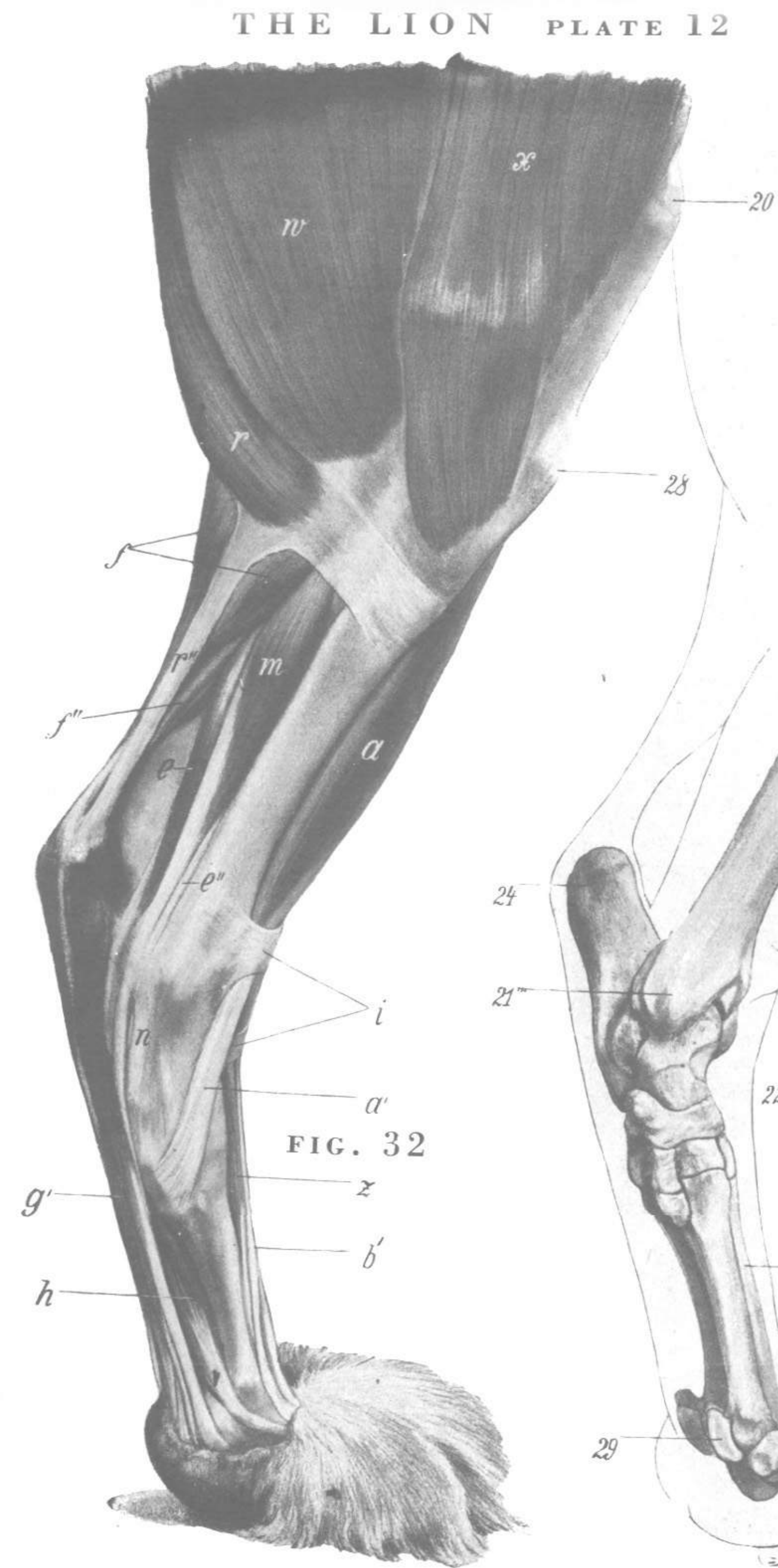
FIG. 27

THE LION - PLATES 11 12

FIGURES 28 29 30 31 32 33 34 35

- a, a'—*M. tibialis anterior*
 b, b'—*M. extensor digitorum longus*
 c—*M. peroneus longus*
 d'—*M. extensor digitorum pedis lateralis*
 d''—*M. peroneus brevis*
 e—*M. flexor hallucis longus*
 e'—*A tendinous ligament*
 e''—*Tendon of the M. tibialis posterior*
 f—*End part of the Mm. gastrocnemii*
 f'—*Tendo Achillis*
 f''—*M. soleus*
 g, g'—*Superficial flexor tendon*
 h—*Mm. interossei*
 i—*Annular ligaments*
 k—*Abductor of the 5th toe*
 m—*M. flexor digitorum pedis longus*
 n—*Lateral ligament of the ankle joint*
 o'—*Fascia lata*
 q, 'q'—*End of the M. biceps femoris*
 r—*End of the M. semitendinosus*
 r', r''—*Tendons at end of M. semitendinosus*
 w—*End of the M. gracilis*
 x—*End of the M. sartorius*
 z—*M. extensor digitorum pedis brevis*
 18—*End of the os femoris*
 20—*Patella*
 21—*Tibia*
 21'—*Internal condyle of the tibia*
 21''—*Lower end of the fibula*
 21'''—*Internal malleolus of tibia*
 22—*Tarsus*
 23—*Fibula*
 24—*Tuber calcanei*
 25—*Metatarsus*
 28—*Swelling of the tibia*
 29—*Sesamoid bones of the metatarsal digital joints*
 30—*Phalanx prima*
 31—*Phalanx secunda*
 32—*Phalanx tertia*





THE LION - PLATES 13 14 15

FIGURES 36 37 38 39 40 41 42 43 44 45 46

- b—*M. levator nasolabialis*
 c—*M. cleidomastoideus*
 d, d'—*M. sternomandibularis*
 e—End part of the *M. sternohyoideus*
 f—Part of the *M. caninus* s. *M. pyramidalis nasi*
 g—*M. zygomaticus*
 g'—*M. malaris*
 h—*M. buccinator*
 i—*M. quadratus* s. *depressor labii inferioris*
 k—*M. orbicularis oris*
 m—*M. masseter*
 n—Depressor of the auricle
 p—*M. scutularis*
 p'—Muscles of the ear
 q—Abductor of the auricle
 r—Levator of the auricle
 u, u', u''—*M. corrugator supercilii*
 v—End of the two-bellied muscle
 w—*M. myohyoideus*
 y—Cervical subcutaneous muscle
 z—*M. temporalis*
 z'—*M. occipitalis*
 *—Atlas
 l—Seat of the auricle
 2, 2'—Anterior edge of the auricle
 3—Posterior edge of the auricle
 4—Incisura intertragica
 9—*Arcus zygomaticus*
 11—*Processus coronoideus* of the lower jawbone
 12—Frontal process of the malar bone
 12'—Zygomatic process of the frontal bone
 13—*Os occipitale*
 13'—Crest and spine of the *os occipitale*
 14—*Os parietale*
 14'—Crest and spine of the *os parietale*
 15—Crest of *os parietale*
 16—*Os temporale*
 17—*Meatus acusticus externus*
 18—Temporo-maxillary joint
 19—Orbita
 20—*Os zygomaticum*
 21—*Os lacrimale*
 22—*Os nasale*
 23—*Os incisivum*
 24—Upper incisor teeth
 24'—Lower incisor teeth
 25—Upper canine tooth
 26—Maxilla
 27—Facial crest
 28—Unpaired part of the lower jawbone
 28'—Paired part of the lower jawbone
 29—Lower canine tooth
 30—Branch of the lower jaw
 30'—*Processus angularis*
 31—Condyle process of the lower jaw
 32—1st cervical vertebra (*Atlas*)
 33—2nd cervical vertebra
 34—Lateral cartilage of the nose
 34'—Nose cartilage
 35—Cartilagenous epiphysis
 36—Lymph gland of the oesophagus
 38—*V. jugularis*
 39—*V. facialis*
 44—*Glandula parotis*
 50—*Glandula submaxillaris*
 59—Prominence corresponding to the pomum
 Adami in the human
 63—Laryngeal muscles
 64—End of the *M. sternothyroideus*
 65—Thyrohyoid muscles

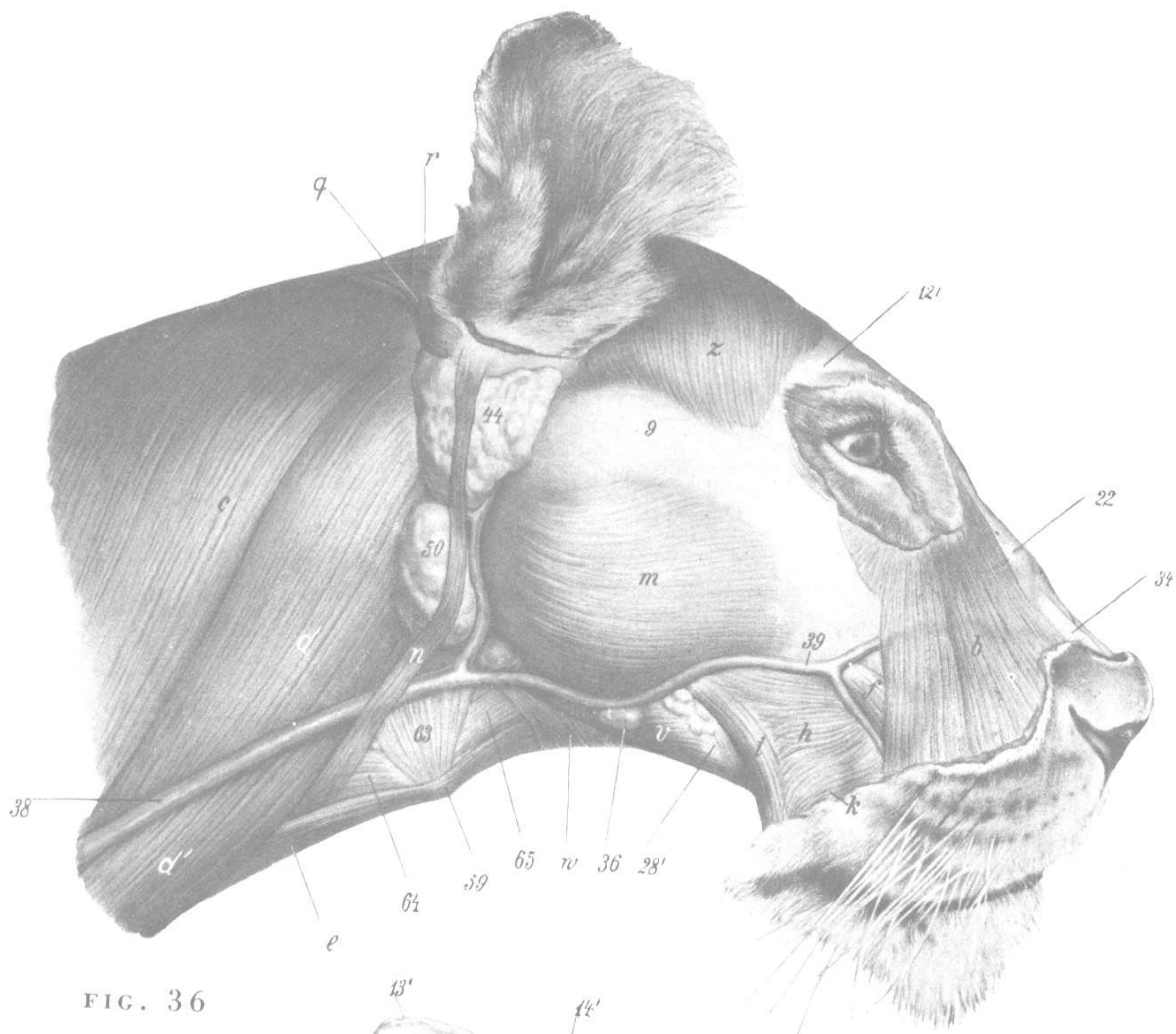


FIG. 36

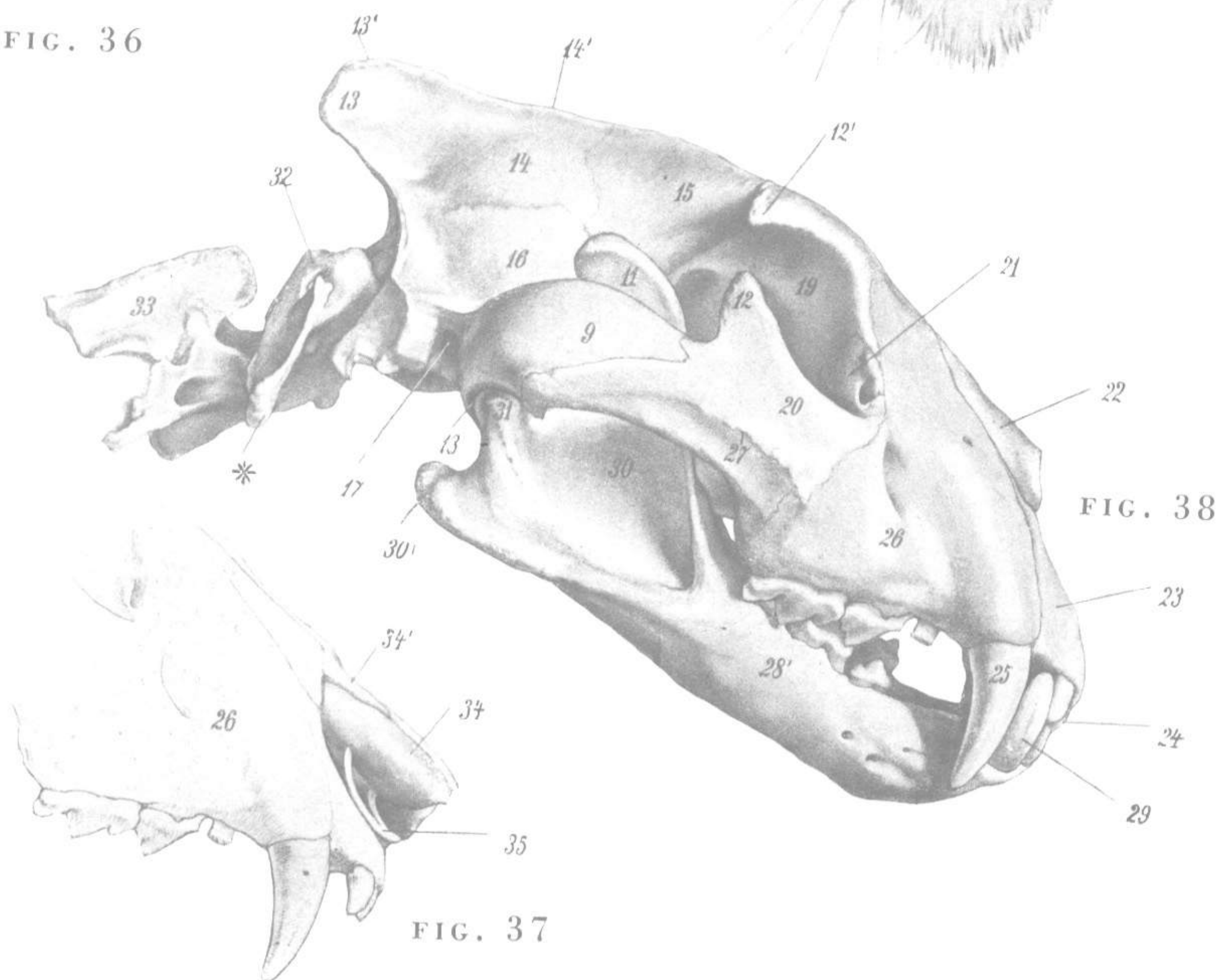


FIG. 38

FIG. 37




FIG. 39

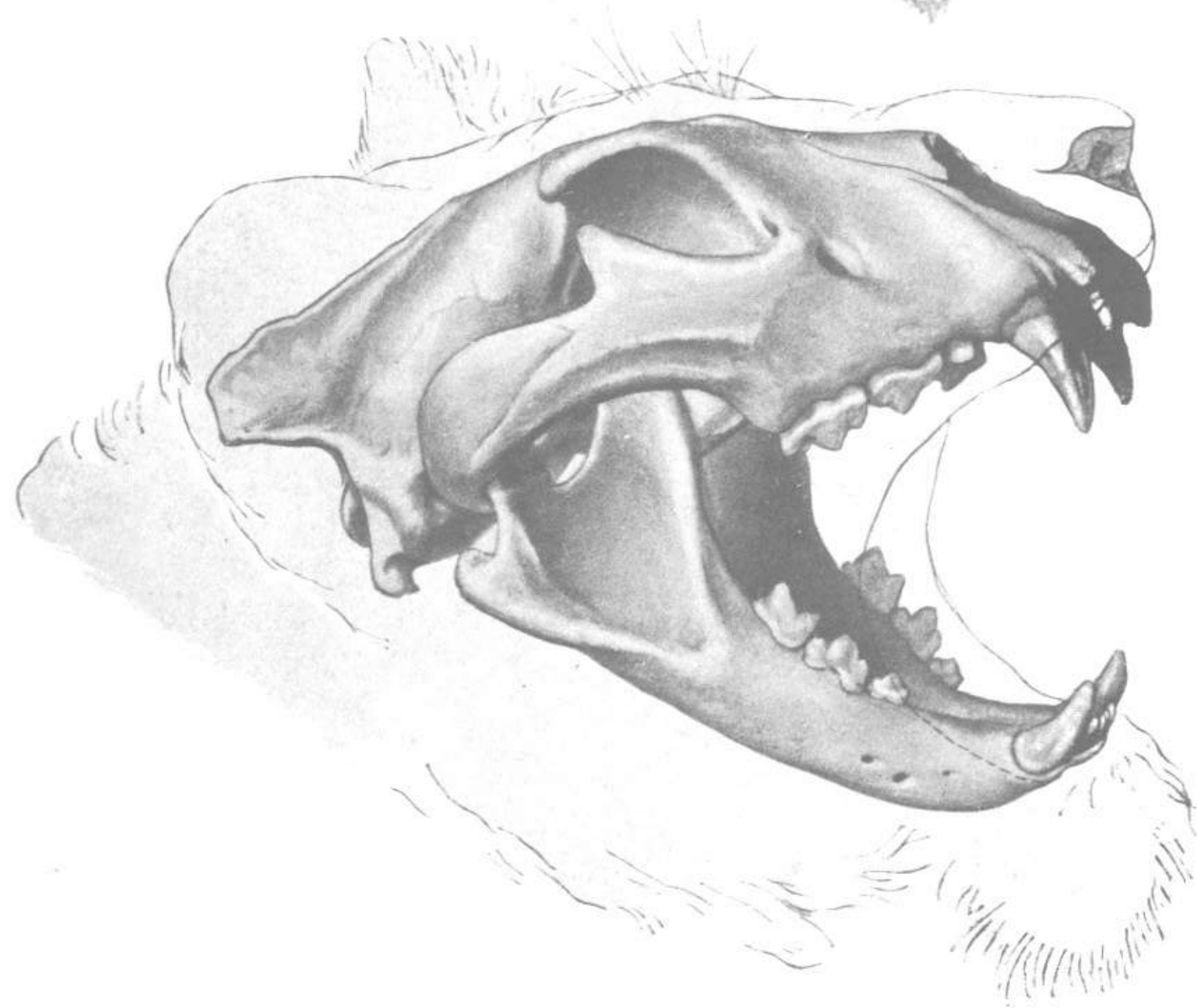


FIG. 41

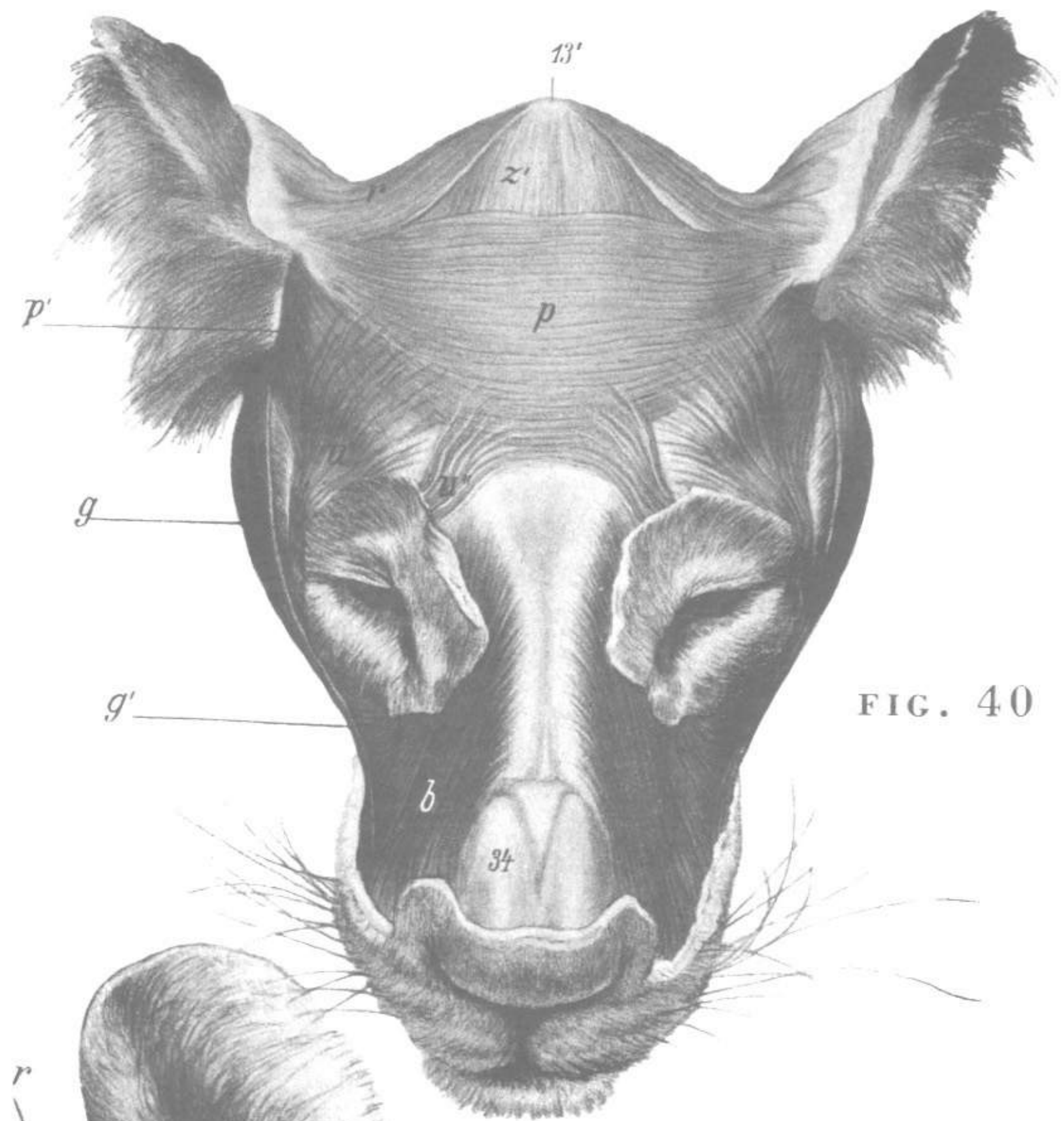


FIG. 40

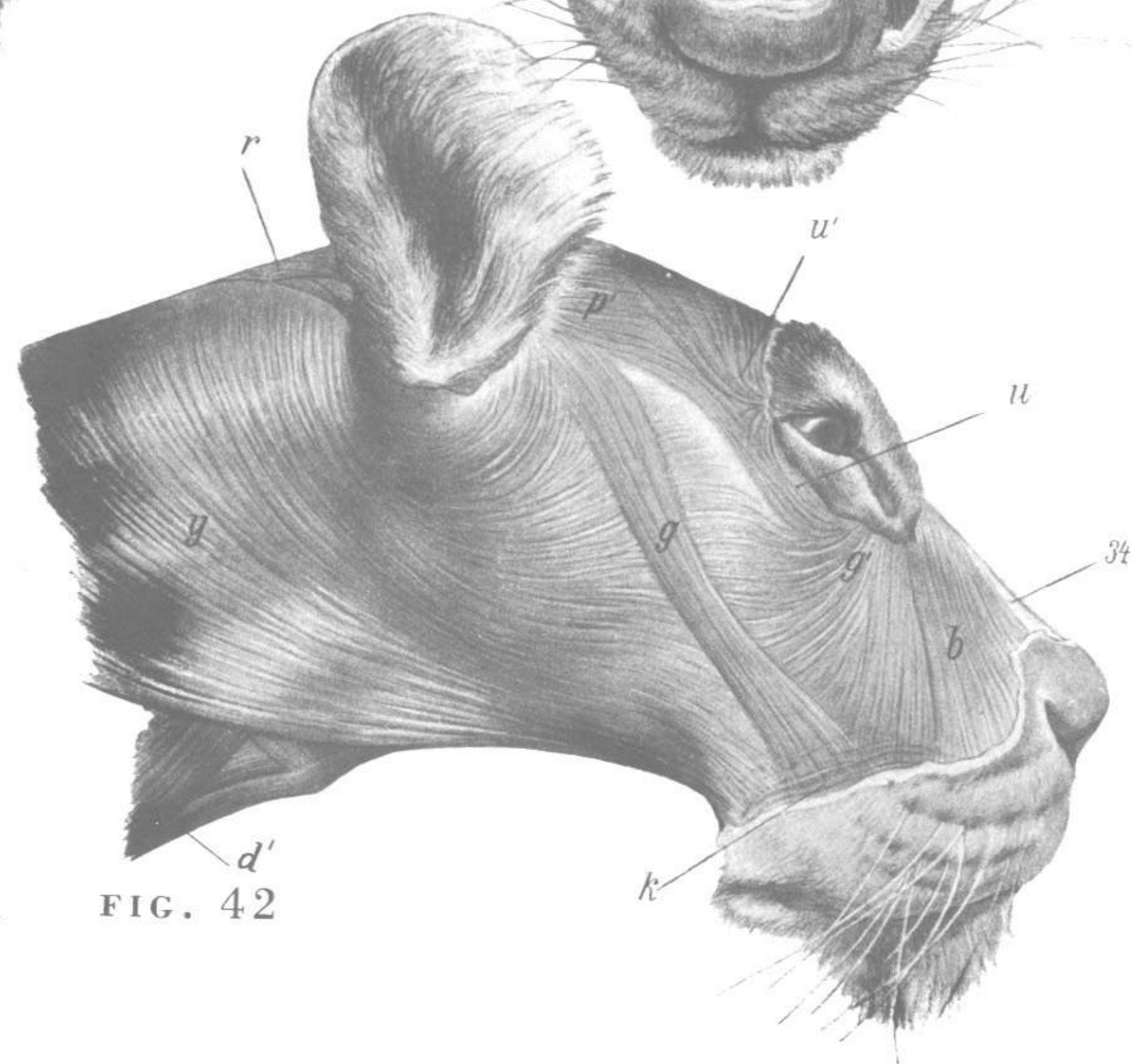
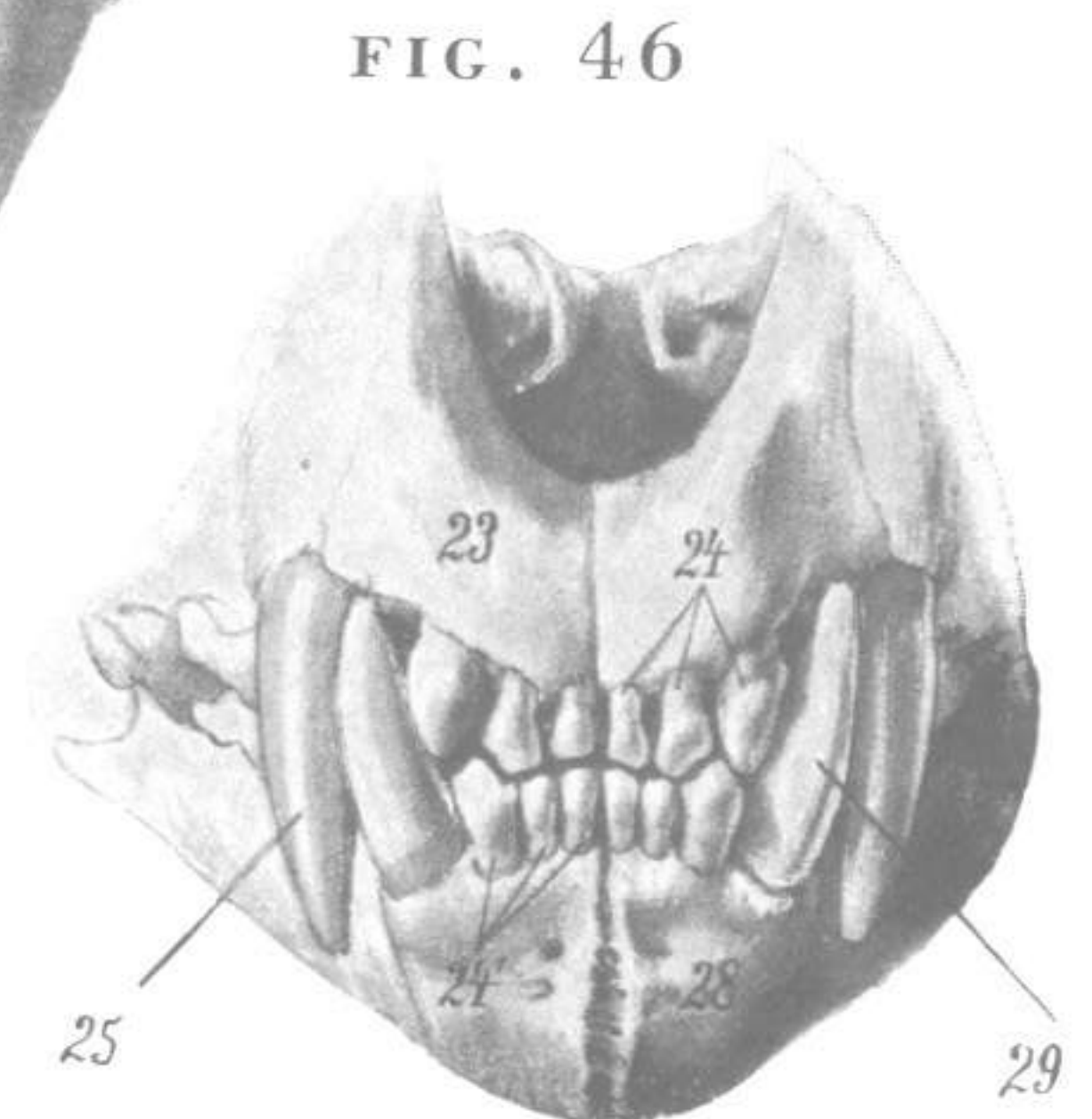
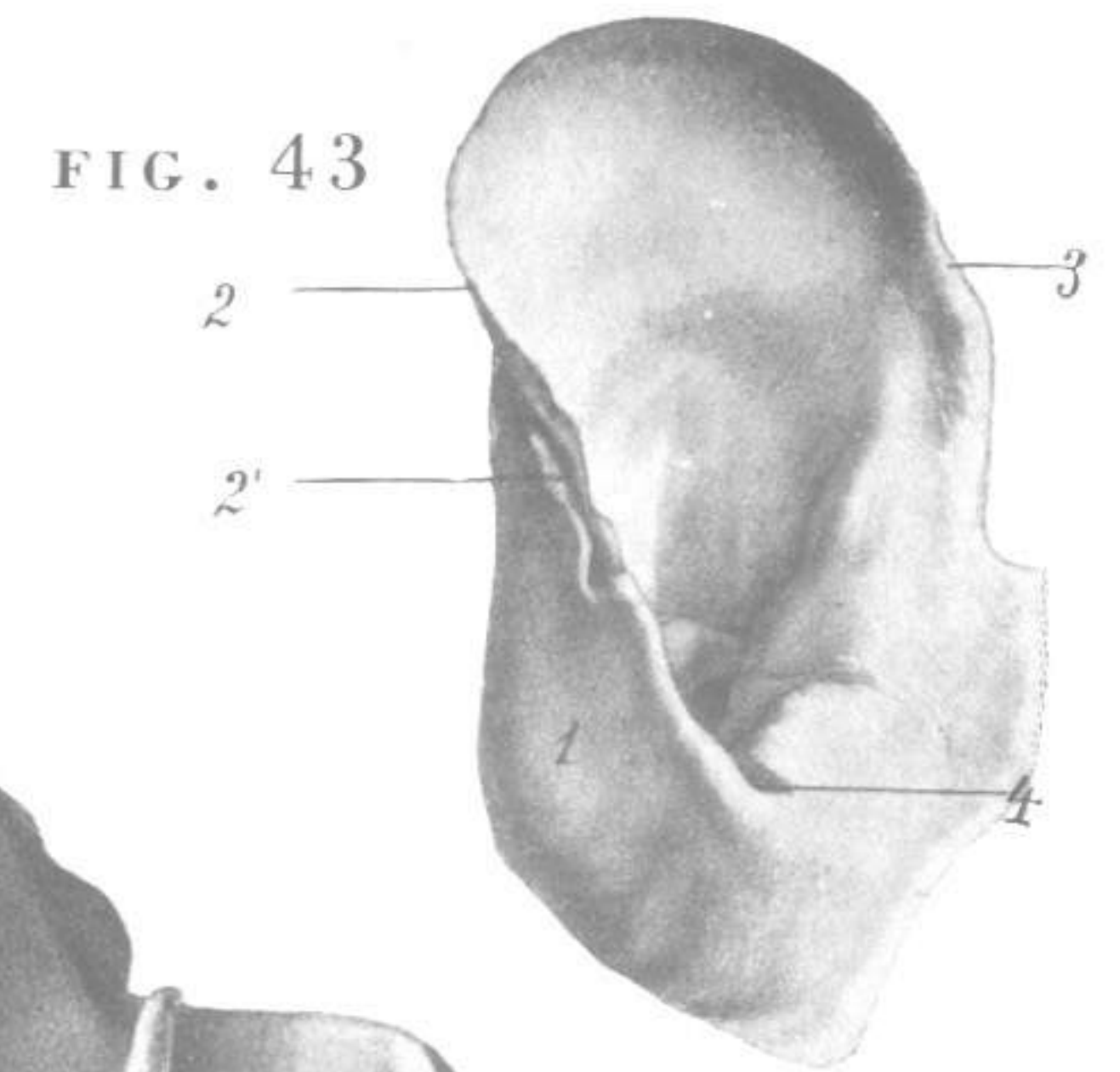
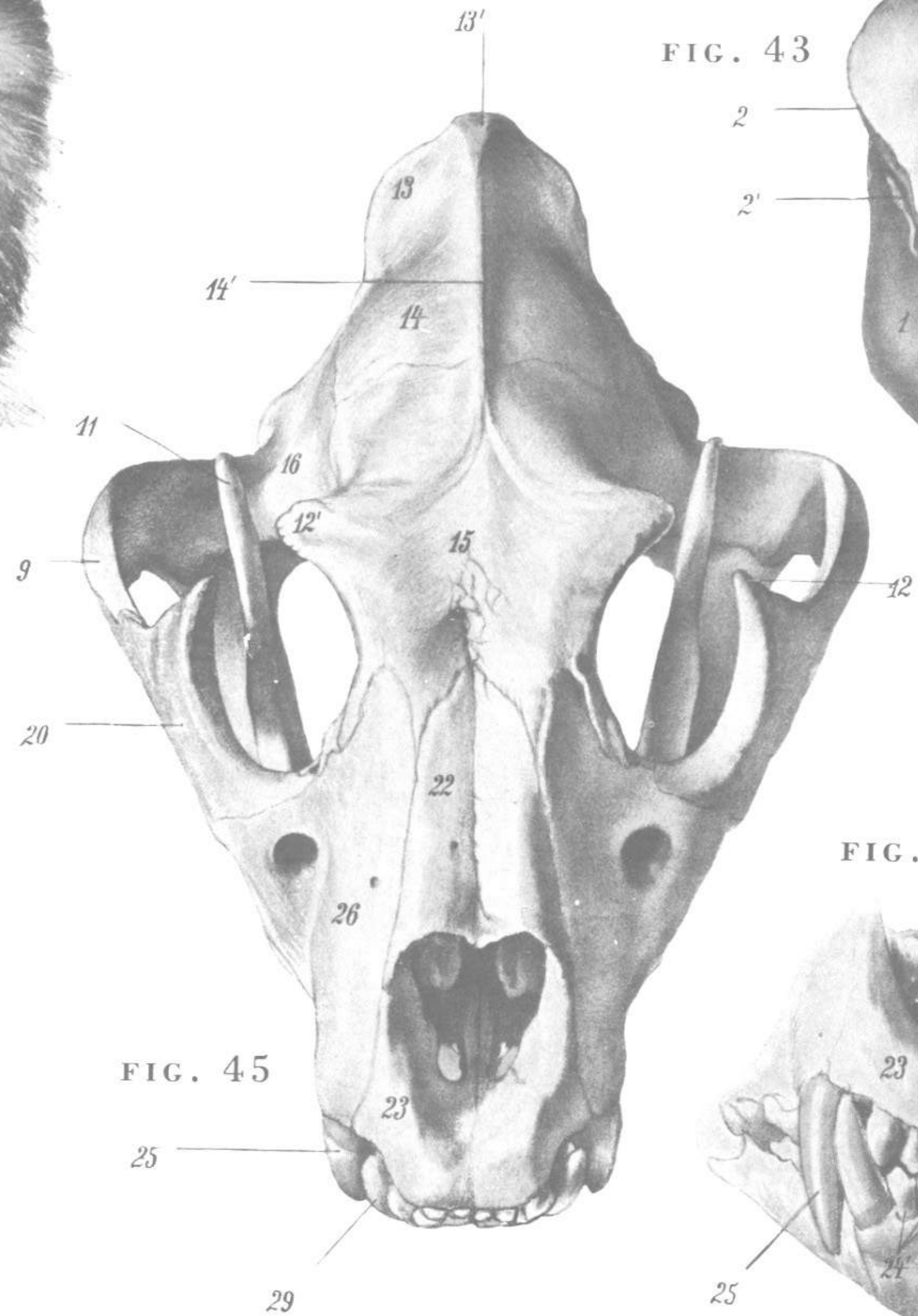
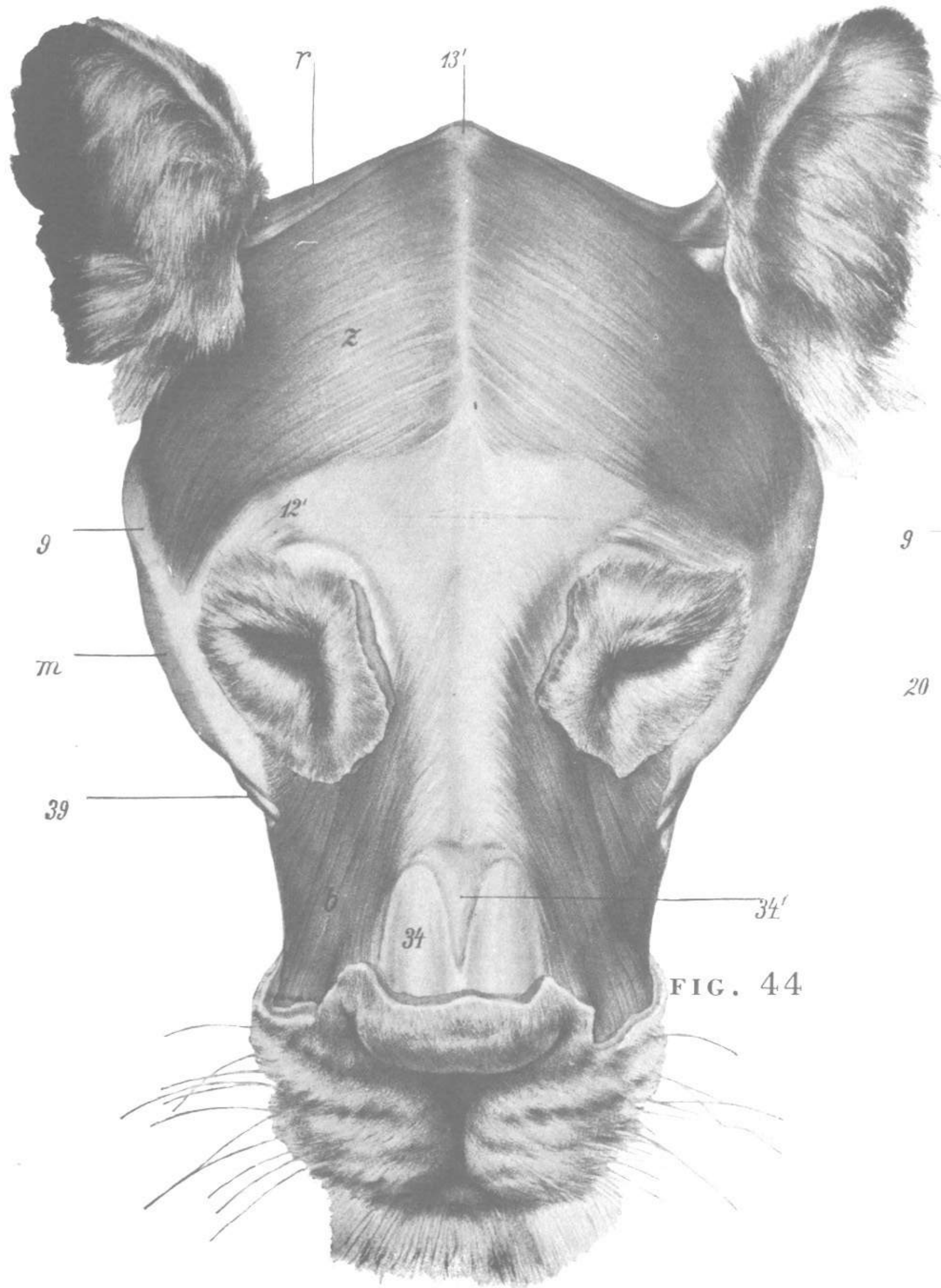


FIG. 42

THE LION PLATE 15



THE LION - PLATE 16


FIGURE 47

a—Groove of the lips
b—Gum
c—Mucous membrane of the cavity
d—Tip of the tongue

e—Gap between teeth
f—Mucous membrane of the lip
g—Upper left canine tooth (*dens caninus*)
g'—Lower left canine tooth

h—Upper left incisor tooth (*dentes incisivi*)
h'—Lower left incisor teeth
i—2nd lower molar tooth

FIG. 47



The Cow and Bull

THE COW AND BULL - PLATES 1 2 3 4

FIGURES 1 2 3 67 68 69 70 71

a—*M. trapezius*
 b—*Shoulder-transverse-process muscle*
 c, c'—*M. brachiocephalicus*
 d—*M. sternomandibularis*
 d'—*M. sternomastoideus*
 e, e'—*M. deltoideus*
 f, f'—*M. triceps brachii*
 g—*M. pectoralis major*
 h, h'—*M. pectoralis minor*
 i—*Thoracic portion of M. serratus anterior*
 i'—*Cervical portion of M. serratus magnus*
 k—*M. latissimus dorsi*
 l—*M. obliquus abdominis externus*
 l'—*Aponeurosis*
 m—*M. serratus posterior*
 m'—*Lumbo-dorsal fascia*
 n—*A small part of origin of the M. obliquus abdom. internus*
 o—*M. tensor fasciae latae*
 o'—*Fascia lata of thigh*
 p—*M. glutaeus medius*
 q, q'—*M. biceps femoris*
 r—*M. semitendinosus*
 s, t—*Short and long levators of the tail*
 u—*Abductor of the tail*
 v'—*M. biceps brachii*
 w—*M. splenius*
 x—*M. rhomboideus*
 y—*End of M. longissimus capitis*
 z—*M. supraspinatus*

z'—*M. infraspinatus*
 z''—*Broad tendon over the humerus*
 1H—*1st cervical vertebra (Atlas)*
 7H—*7th cervical vertebra*
 K—*Sacrum*
 6K—*6th costal cartilage*
 1L—*1st lumbar vertebra*
 6L—*6th lumbar vertebra*
 1R—*1st thoracic (dorsal) vertebra*
 6R—*6th rib*
 12R—*12th thoracic (dorsal) vertebra*
 13R—*13th rib*
 1S—*1st caudal vertebra*
 *—*Alar border of the atlas*
 1—*Scapula*
 1'—*Border of the cartilago scapulae*
 2—*Spina scapulae*
 3—*Acromion*
 4—*Humerus*
 4'—*Epicondyle*
 5—*Tuberculum majus*
 6—*Rotator*
 7—*Ulna*
 8—*Olecranon*
 9—*Radius*
 10—*Carpus*
 11—*Os pisiforme*
 12—*Metacarpus*
 13—*Phalanges manus*
 14—*Sternum*

14'—*Manubrium sterni*
 14''—*Cartilago xiphoidea*
 15—*Ossa pelvis*
 16—*Tuber coxae*
 16'—*Tuber sacrale*
 17—*Tuber ischiadicum*
 18—*Os femoris*
 19—*Trochanter major*
 20—*Patella*
 21—*Tibia*
 21'—*External condyle of the tibia*
 22—*Tarsus*
 23—*Os malleolare*
 24—*Tuber calcanei*
 25—*Metatarsus*
 26—*Phalanges pedis*
 27—*Muscles of the ear*
 28—*M. quadriceps femoris*
 28'—*M. rectus femoris*
 29—*M. semimembranosus*
 30—*Mm. gastrocnemii*
 31—*Broad pelvic ligament*
 32—*Plane of the cross section of the neck shown in Figures 70 (cow) and 71 (bull) on Plate 4*
 33—*Transverse processes of the cervical vertebrae*
 34—*V. jugularis*
 35, 36, 37—*Large veins clearly protruding through the outer skin*

THE COW AND BULL PLATE I



FIG. 1

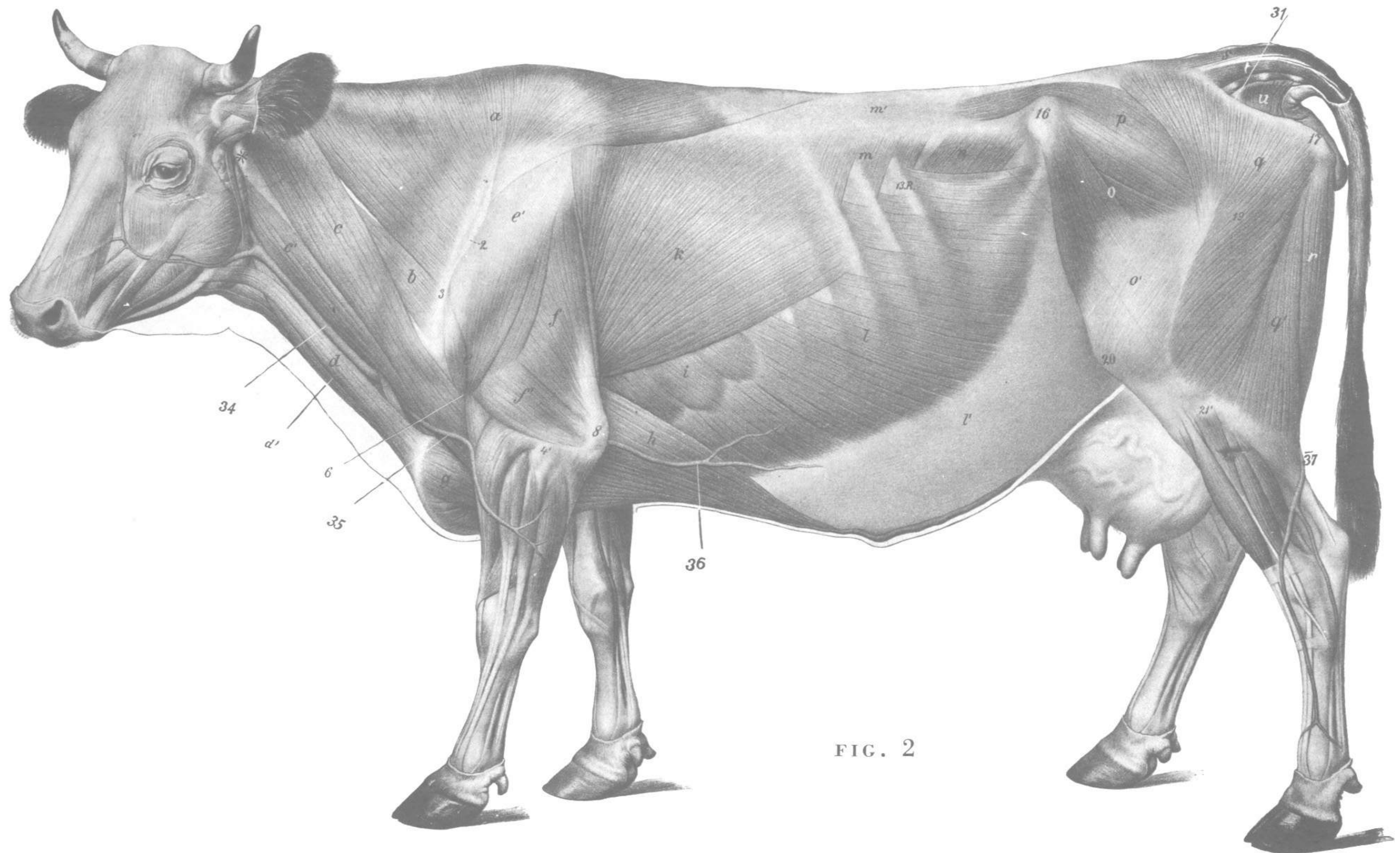


FIG. 2

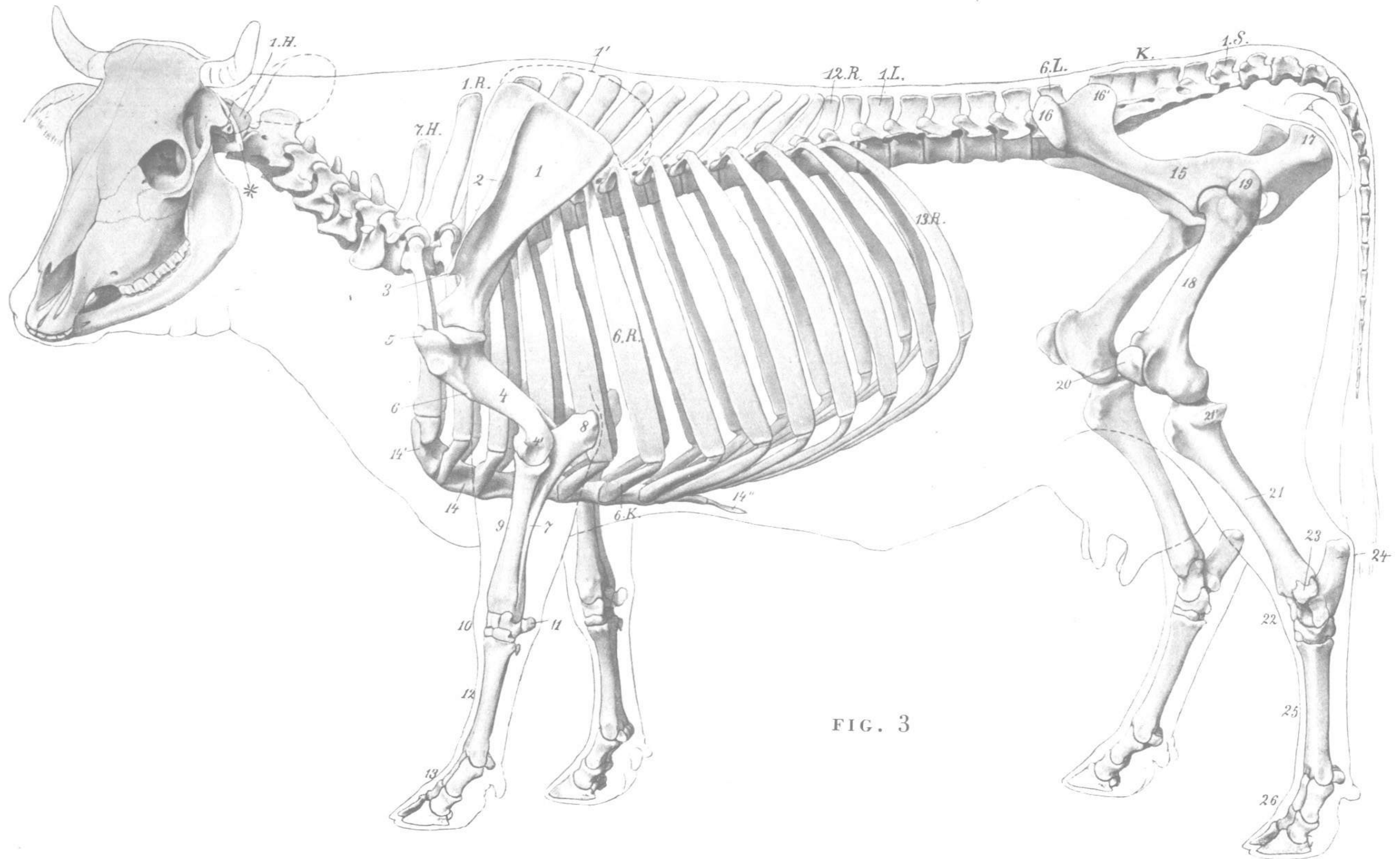


FIG. 3

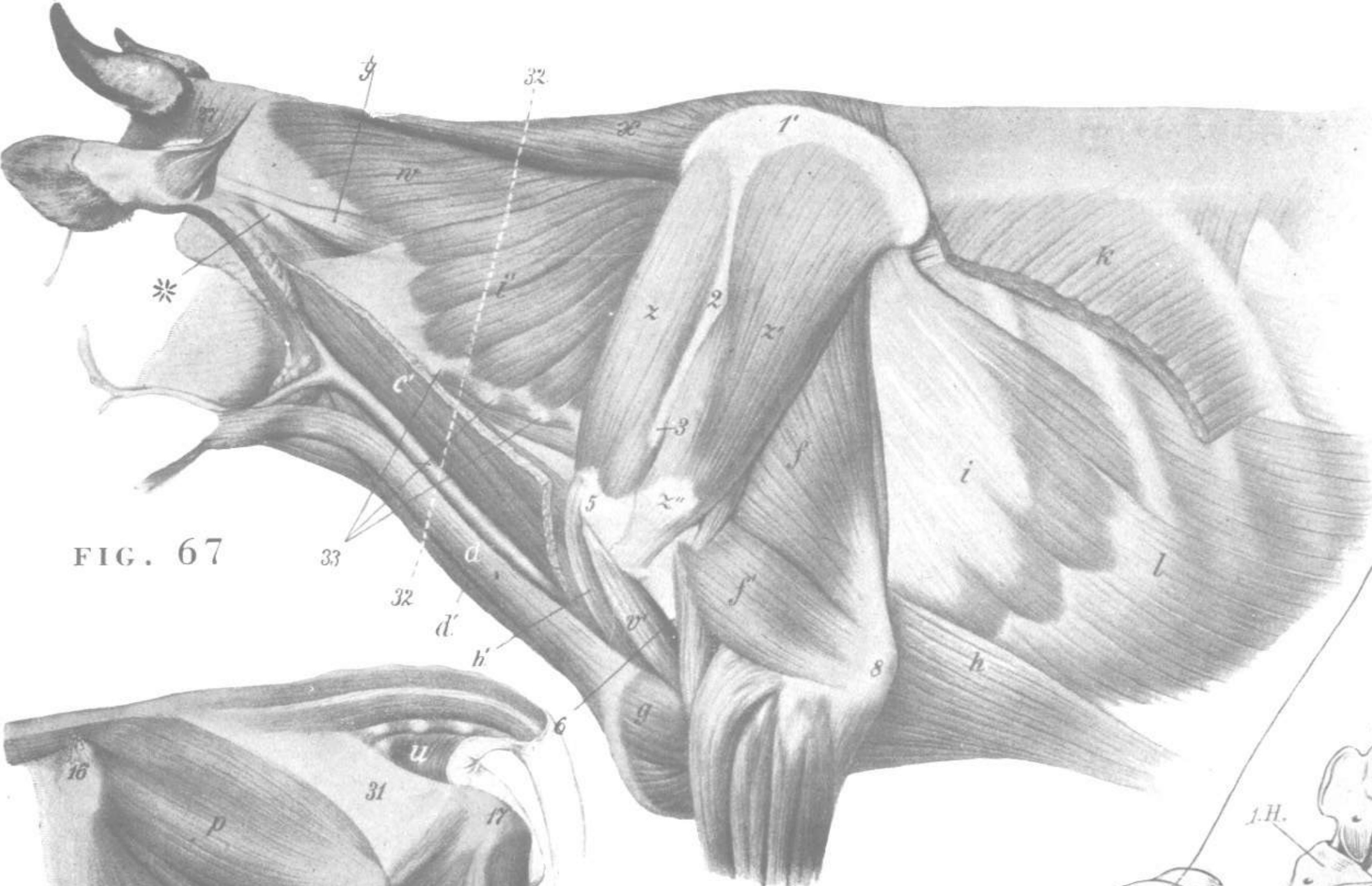

FIG. 67

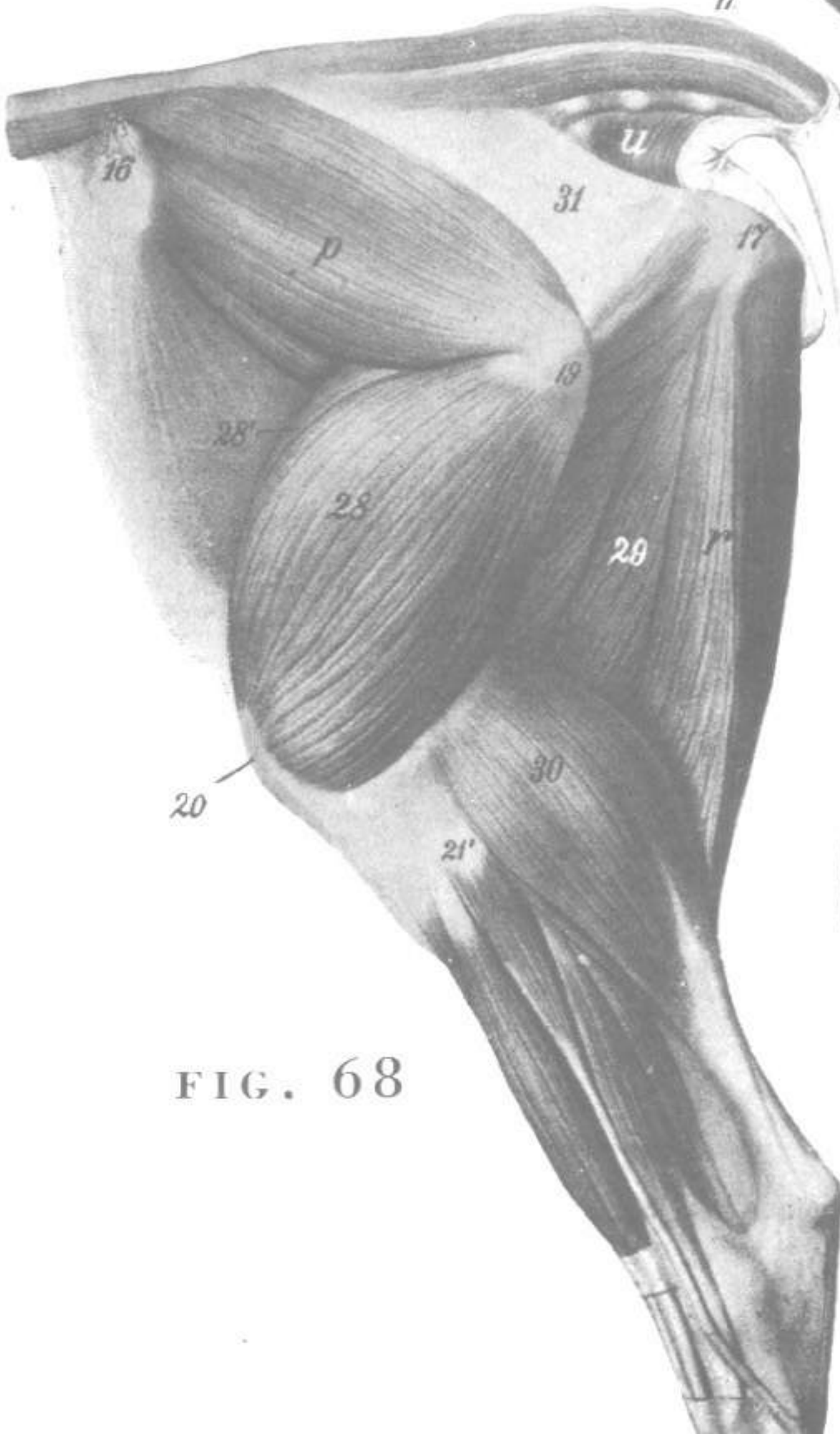


FIG. 68

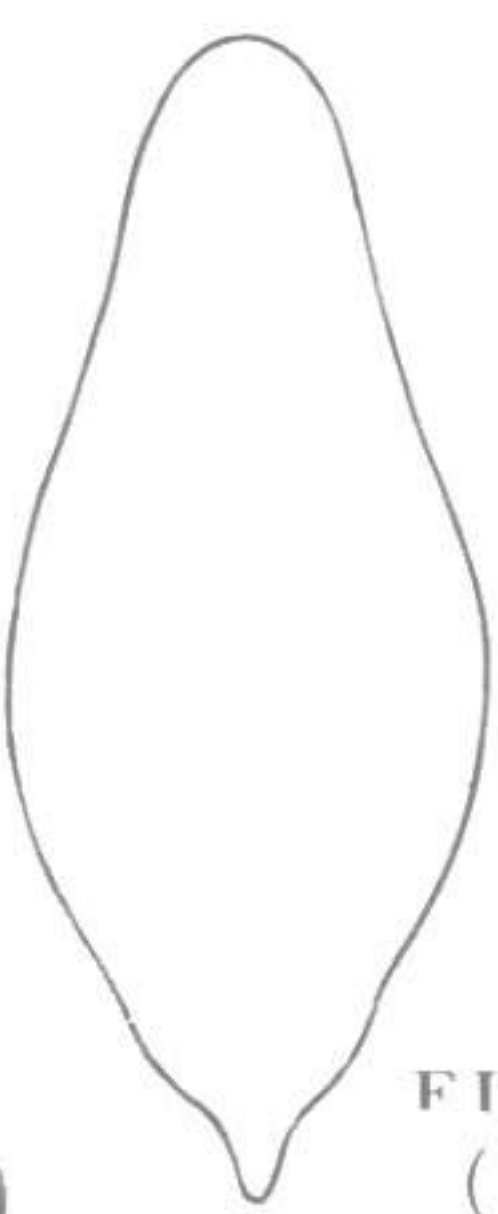


FIG. 70
(COW)

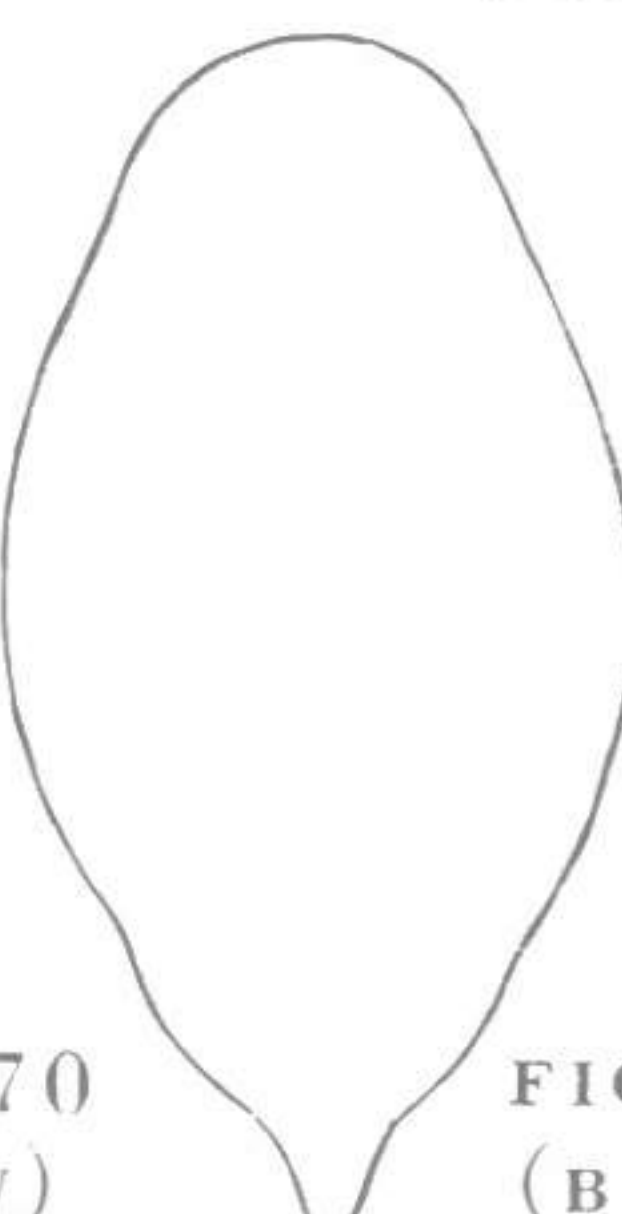


FIG. 71
(BULL)

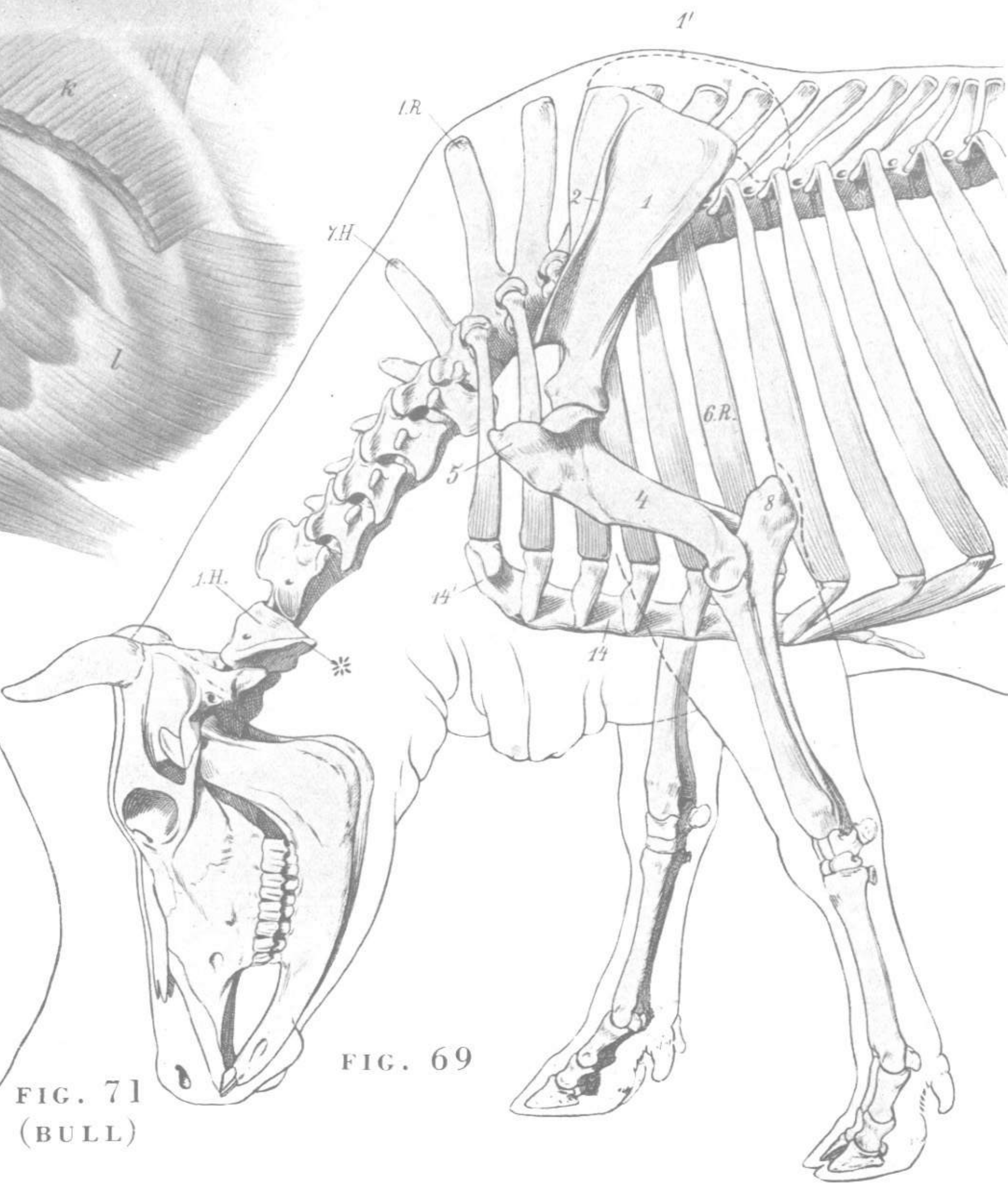

FIG. 69

THE COW AND BULL . PLATES 5 6

FIGURES 4 5 6 7 8 9

a—*M. trapezius*
 b—*Shoulder-transverse-process muscle*
 c, c'—*M. brachiocephalicus, c cervical, c'*
 mastoidal part
 d—*M. sternomandibularis*
 d'—*M. sternomastoideus*
 e—*End of the M. sternohyoideus*
 g—*M. pectoralis major*
 i—*V. jugularis*
 i'—*Cutaneous vein*
 k—*Larynx*
 p—*M. glutaeus medius*
 q, q'—*M. biceps femoris*
 r—*M. semitendinosus*
 s—*Levator of the tail*

u—*Abductor of the tail*
 v—*M. semimembranosus*
 w—*M. gracilis*
 x—*Posterior-upper margin of the broad pelvic*
 ligament
 1—*Scapula*
 2—*Spina scapulae*
 3—*Acromion*
 4—*Humerus*
 5—*Tuberculum majus of the humerus*
 6—*Rotator of the humerus*
 9—*Radius*
 14, 14'—*Sternum & manubrium sterni*
 1R—*1st rib*

7H—*7th cervical vertebra*
 *—*Ala border of the 1st cervical vertebra (Atlas*
 border)
 16—*Tuber coxae*
 17—*Tuber ischiadicum*
 18—*Os femoris*
 19—*Trochanter major of the os femoris*
 19'—*Trochanter minor of the os femoris*
 21—*Tibia*
 22—*Tarsus*
 24—*Tuber calcanei*
 25—*Metatarsus*
 26—*Phalanges pedis*
 37—*Large cutaneous vein on the tibia*

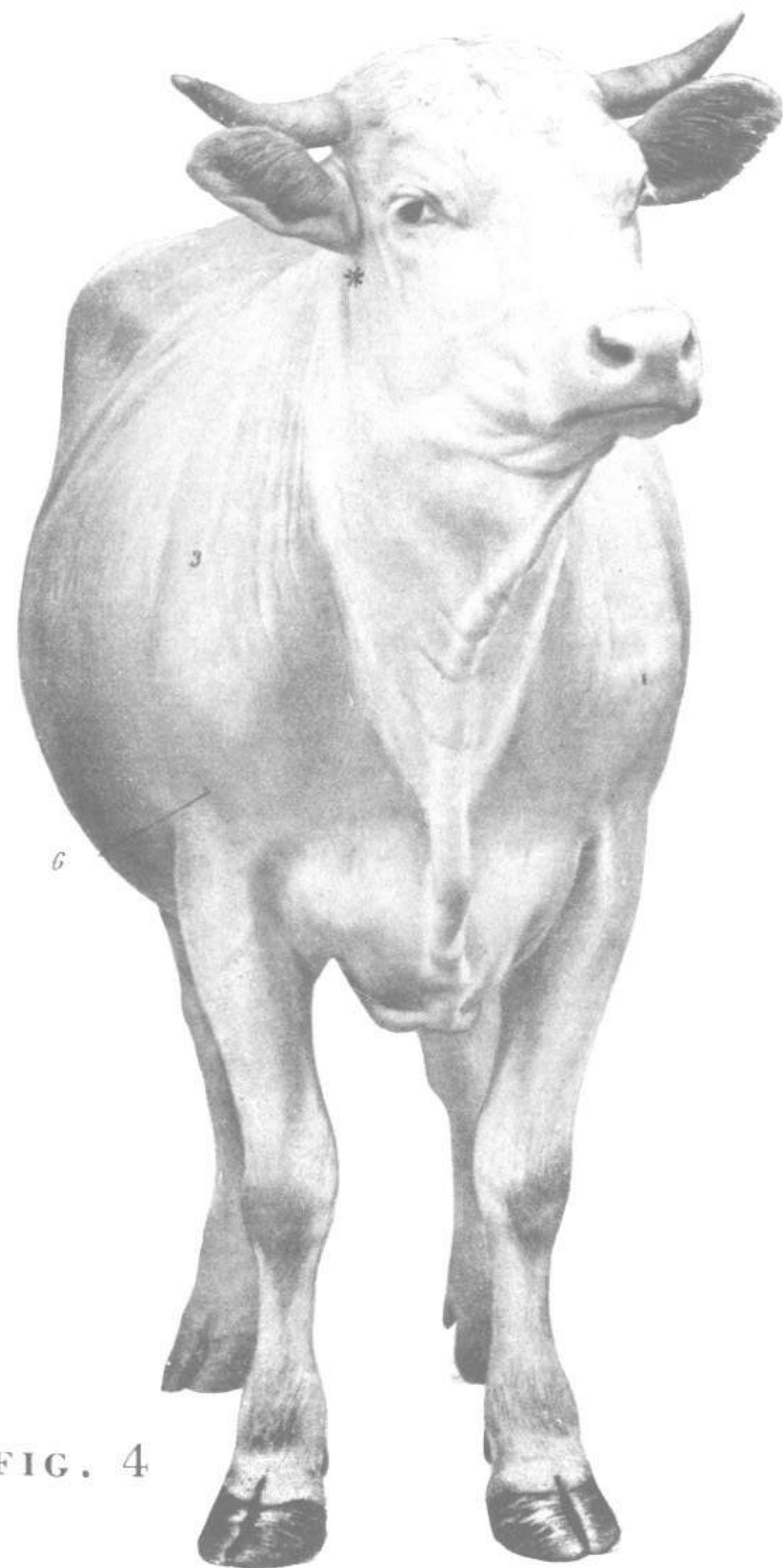


FIG. 4

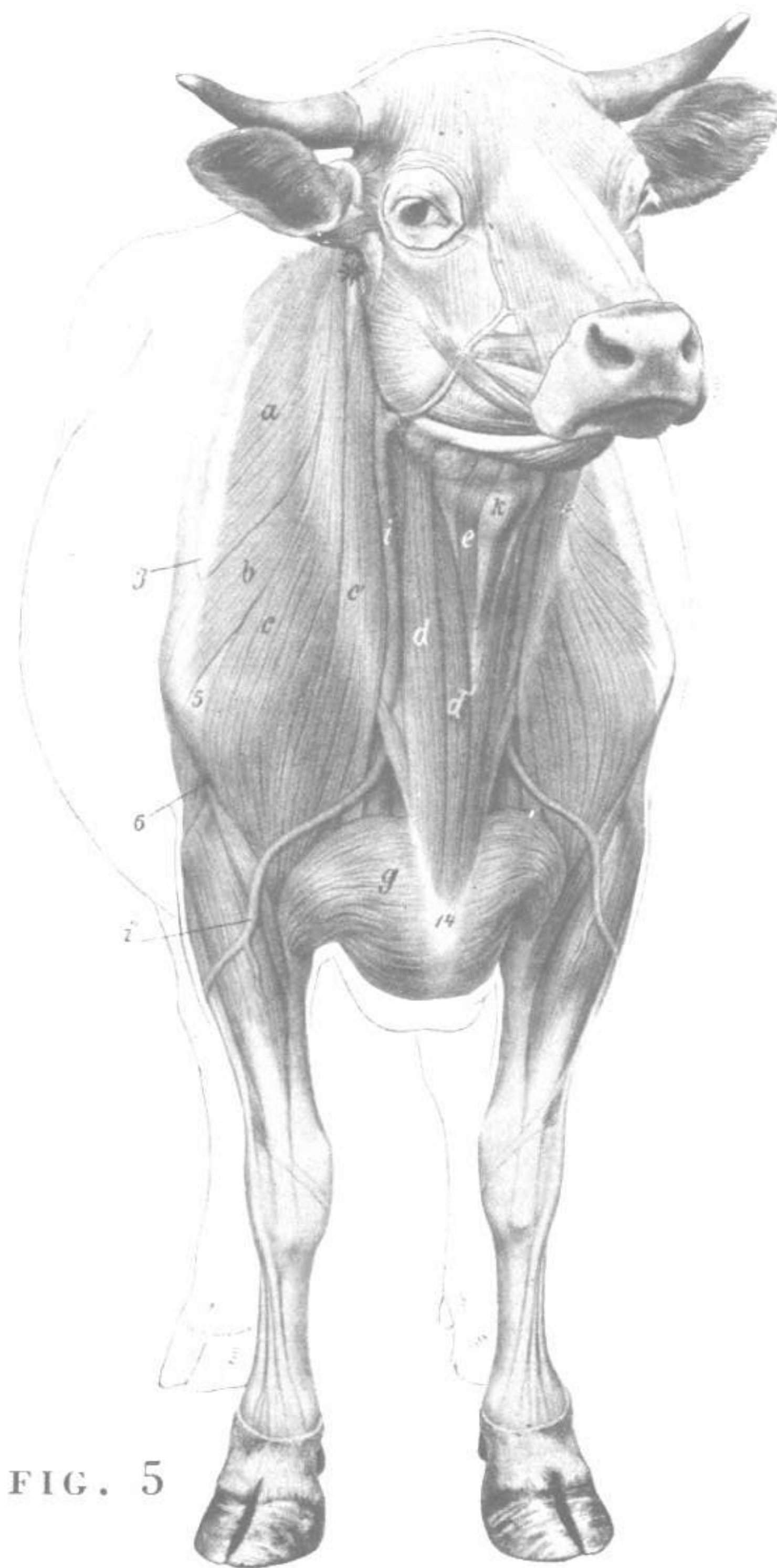

FIG. 5

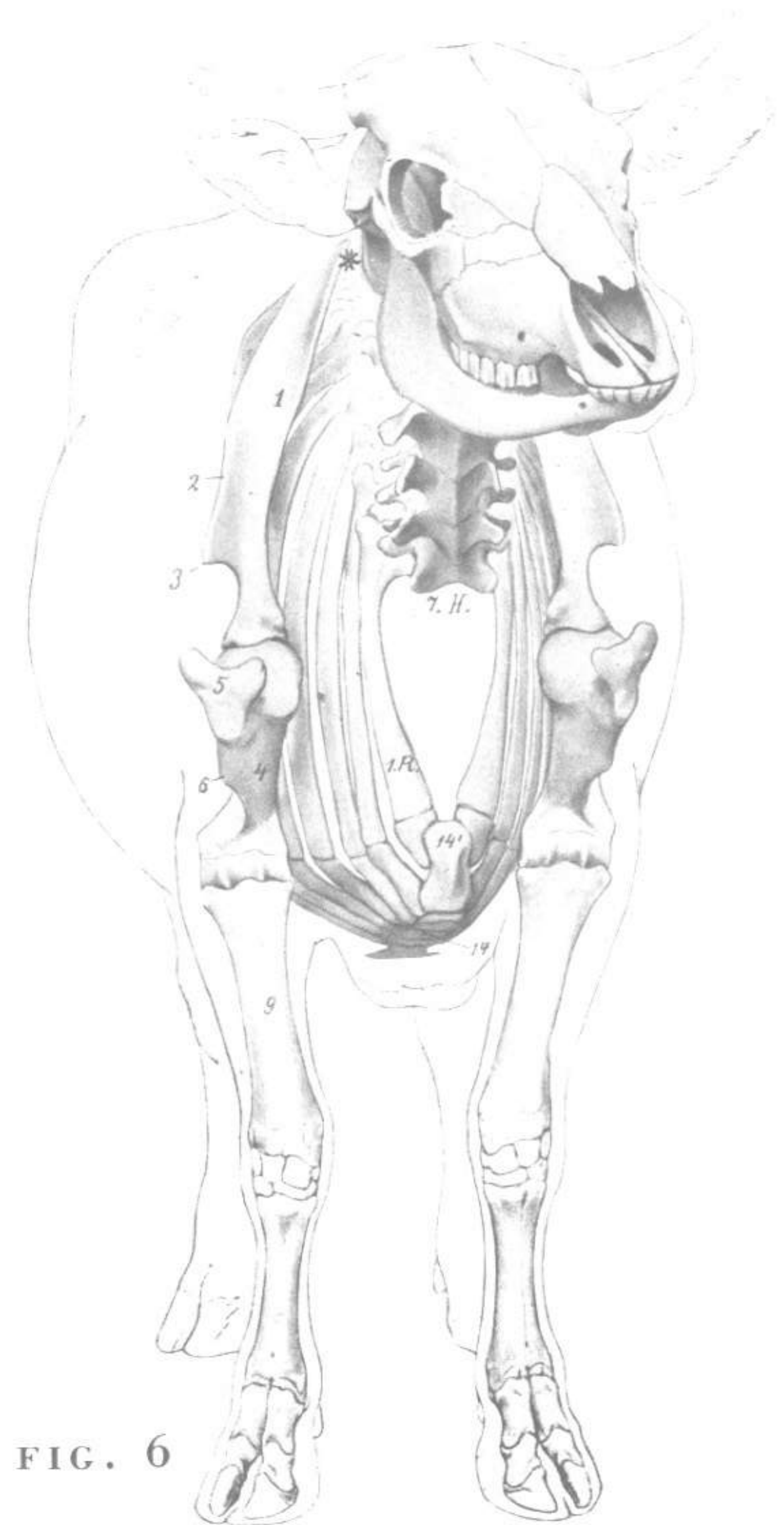


FIG. 6

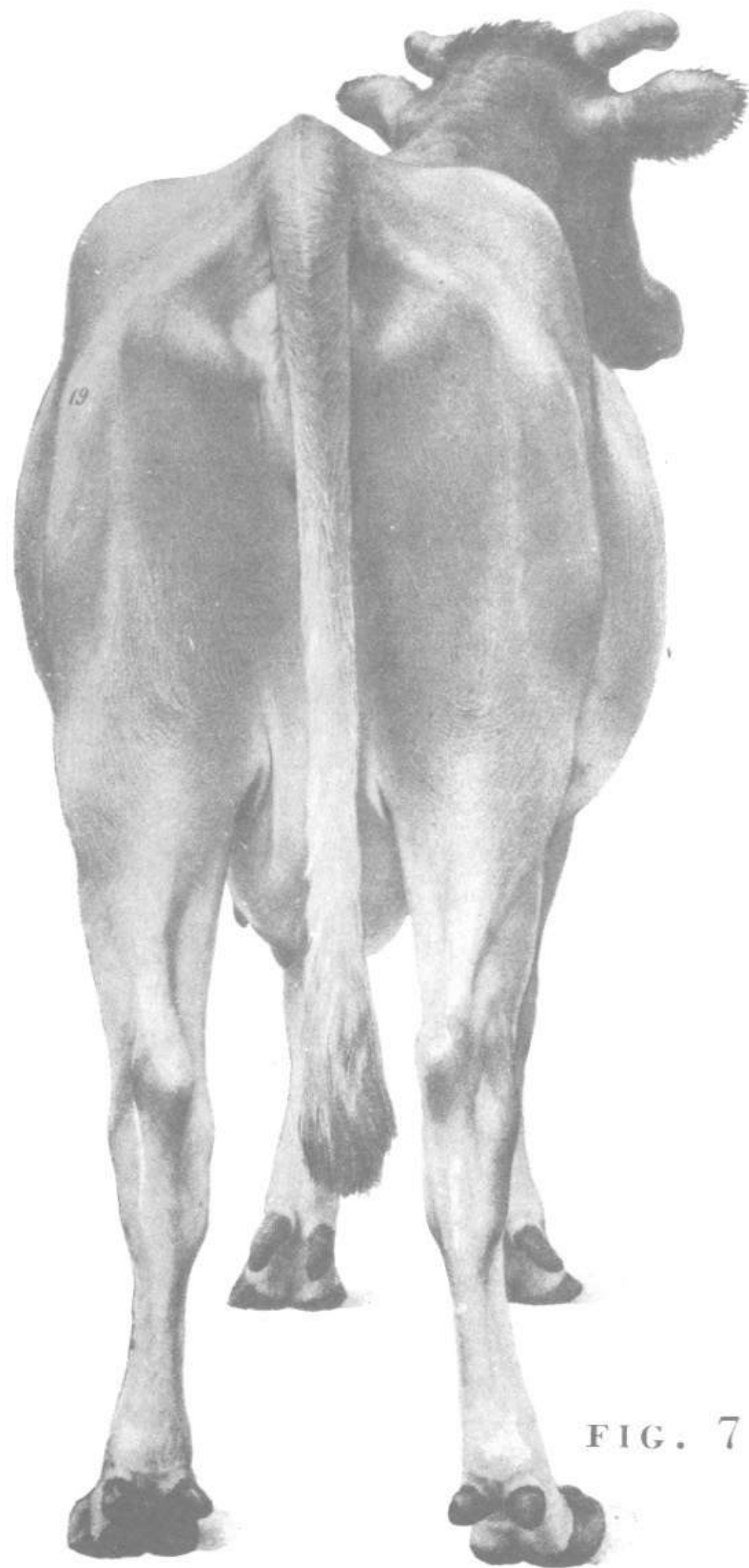


FIG. 7

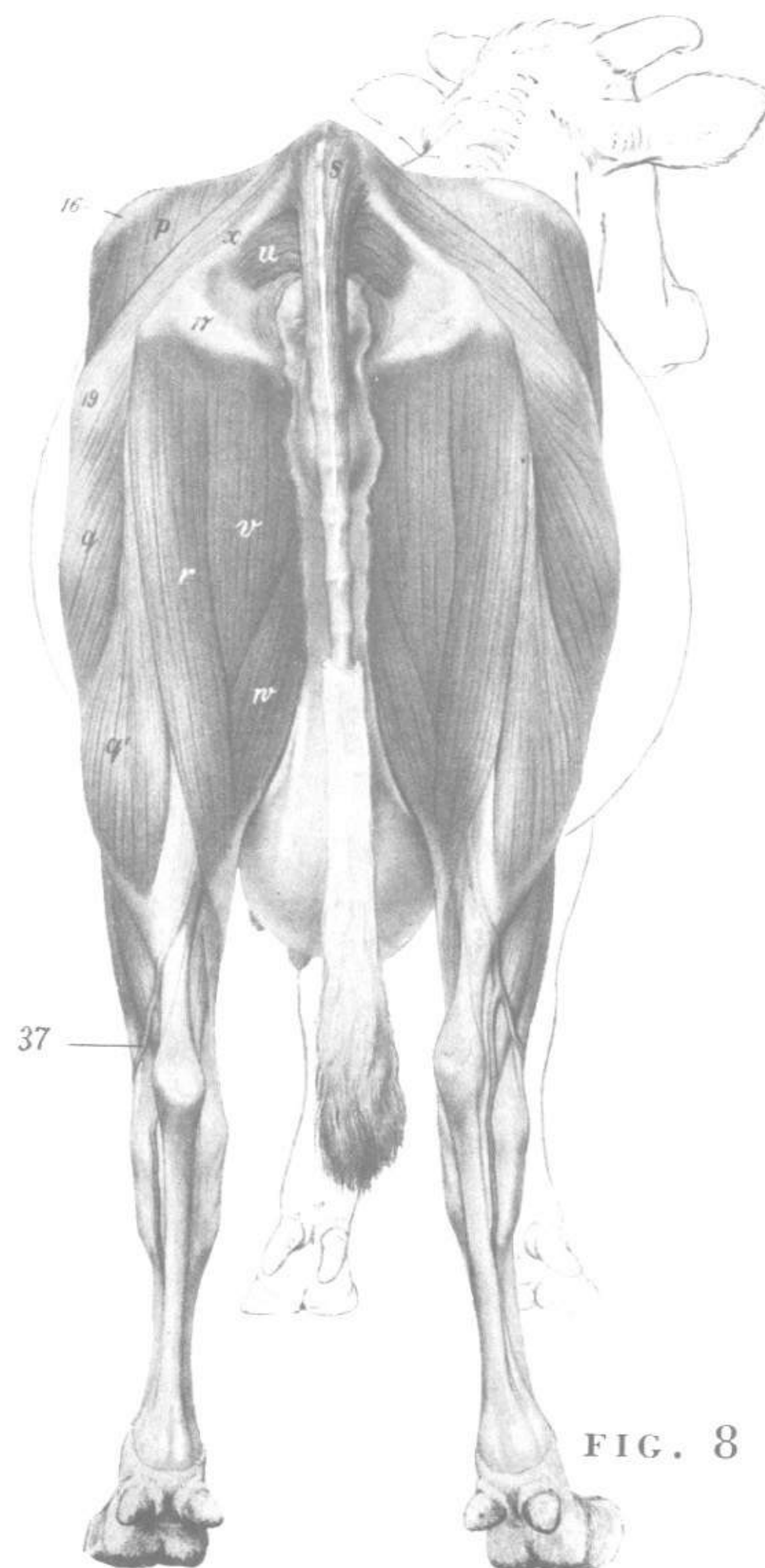

FIG. 8

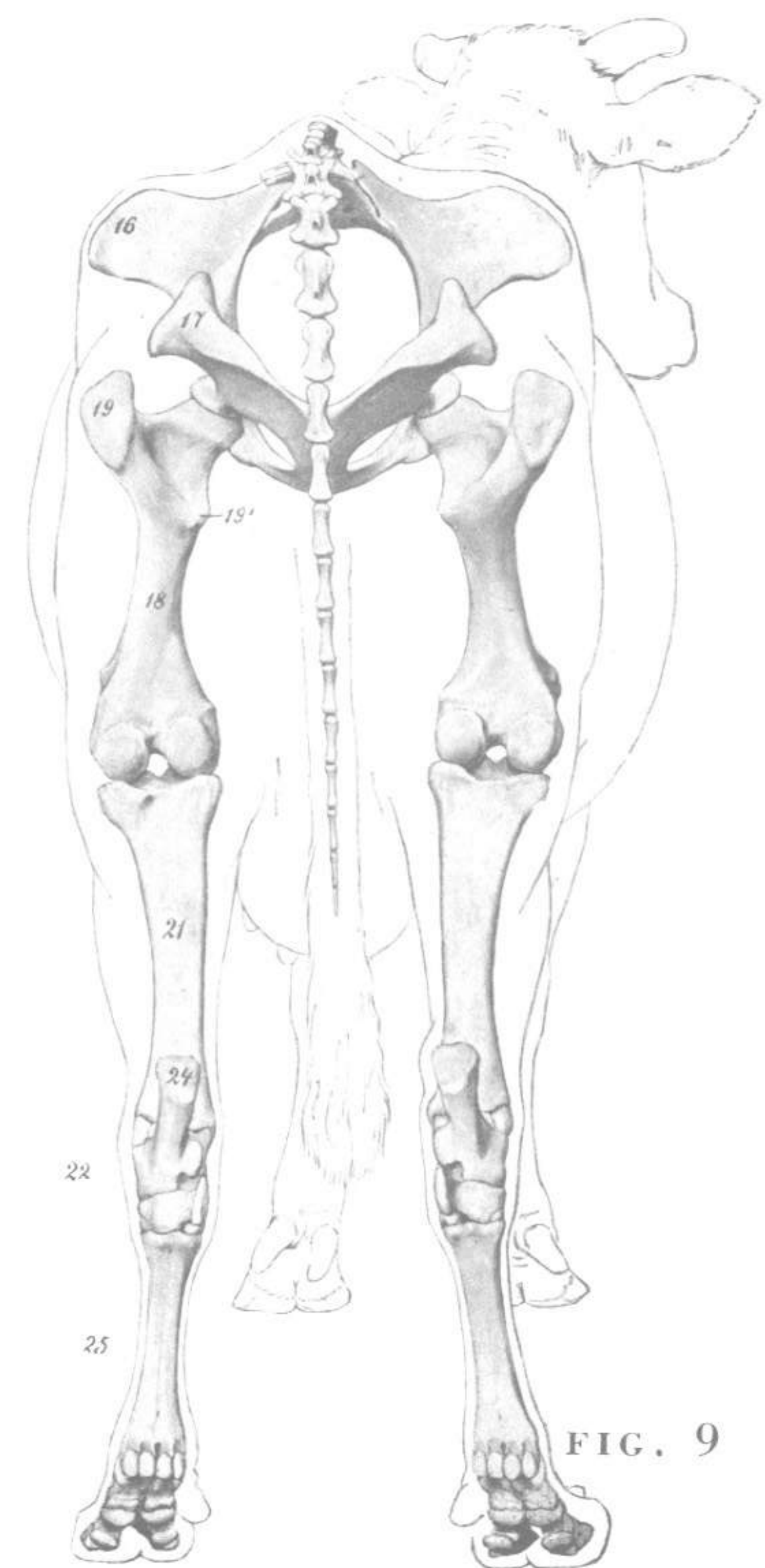


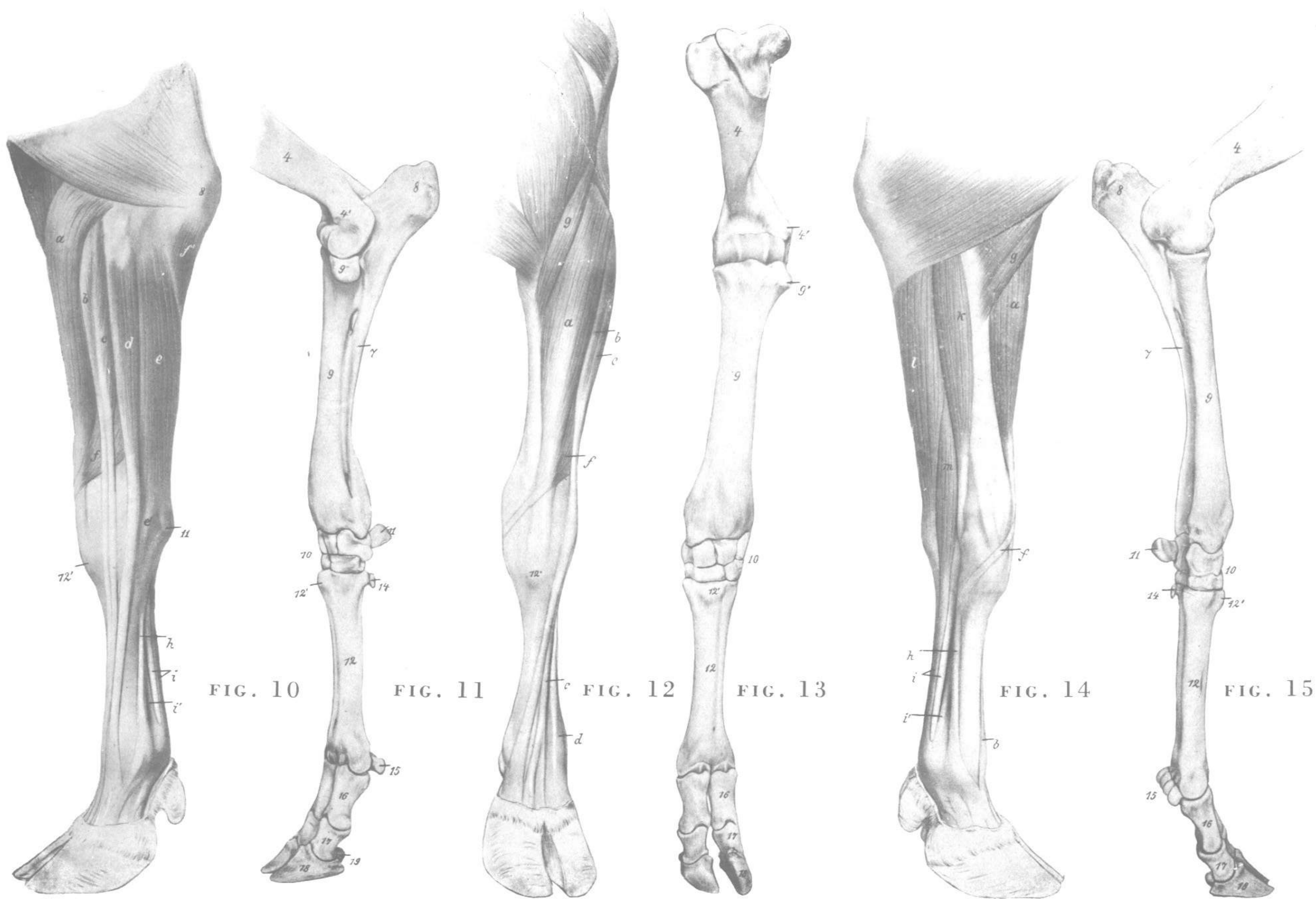
FIG. 9

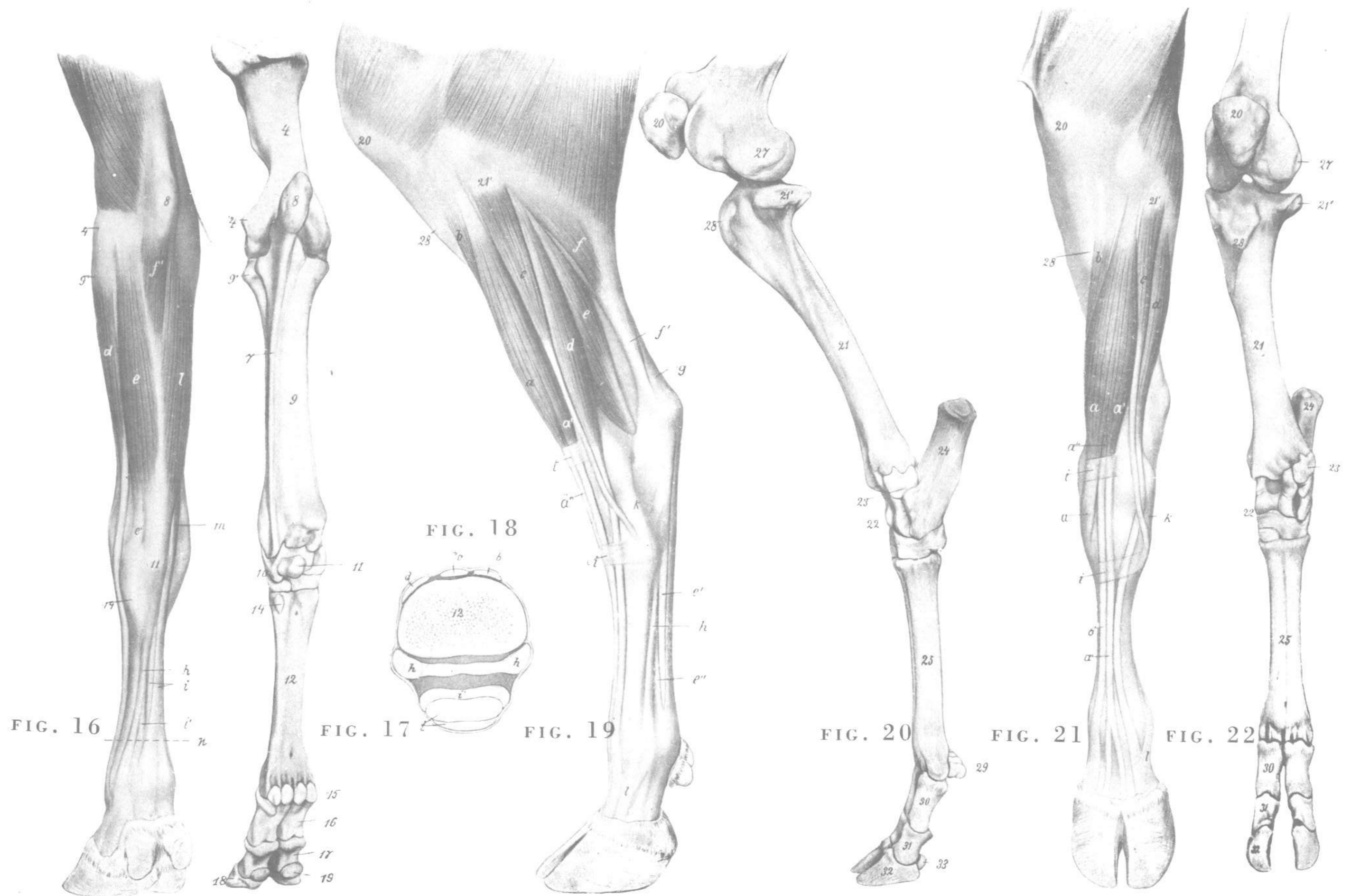
THE COW AND BULL - PLATES 7 8

FIGURES 10 11 12 13 14 15 16 17 18

- | | | |
|---|--|---|
| a— <i>M. extensor carpi radialis</i> | i'— <i>Assisting flexor tendon</i> | 9'— <i>External tuberosity of the radius</i> |
| b— <i>M. extensor digiti tertii proprius</i> | k— <i>M. flexor carpi radialis</i> | 10— <i>Bones of the carpus</i> |
| c— <i>M. extensor digitorum communis</i> | l— <i>Humeral head of the M. flexor carpi ulnaris</i> | 11— <i>Os pisiforme</i> |
| d— <i>M. extensor digiti quarti proprius</i> | m— <i>M. flexor digitorum sublimis</i> | 12— <i>Skeleton of the metacarpus</i> |
| e— <i>M. extensor carpi ulnaris</i> | n— <i>Plane of the cross section of the metacarpus</i> | 12'— <i>Swelling of the primary metatarsal bone</i> |
| e'— <i>Tendon on leg</i> | shown in Fig. 18 on Plate 8 | 14— <i>Rudimentary external small metacarpal bone</i> |
| f— <i>M. abductor pollicis longus</i> | 4— <i>Humerus</i> | 15— <i>Sesamoid bone of the 1st digital joint</i> |
| f'— <i>Ulnar head of the flexor carpi ulnaris</i> | 4'— <i>Extensor condyle of the humerus</i> | 16— <i>Phalanx prima</i> |
| g— <i>M. brachialis internus</i> | 7— <i>Ulna</i> | 17— <i>Phalanx secunda</i> |
| h— <i>M. interosseus medius</i> | 8— <i>Olecranon</i> | 18— <i>Phalanx tertia</i> |
| i— <i>Flexor tendons</i> | 9— <i>Radius</i> | 19— <i>Sesamoid bones of the 3rd digital joint</i> |

THE COW AND BULL PLATE 7





THE COW AND BULL - PLATES 8 9

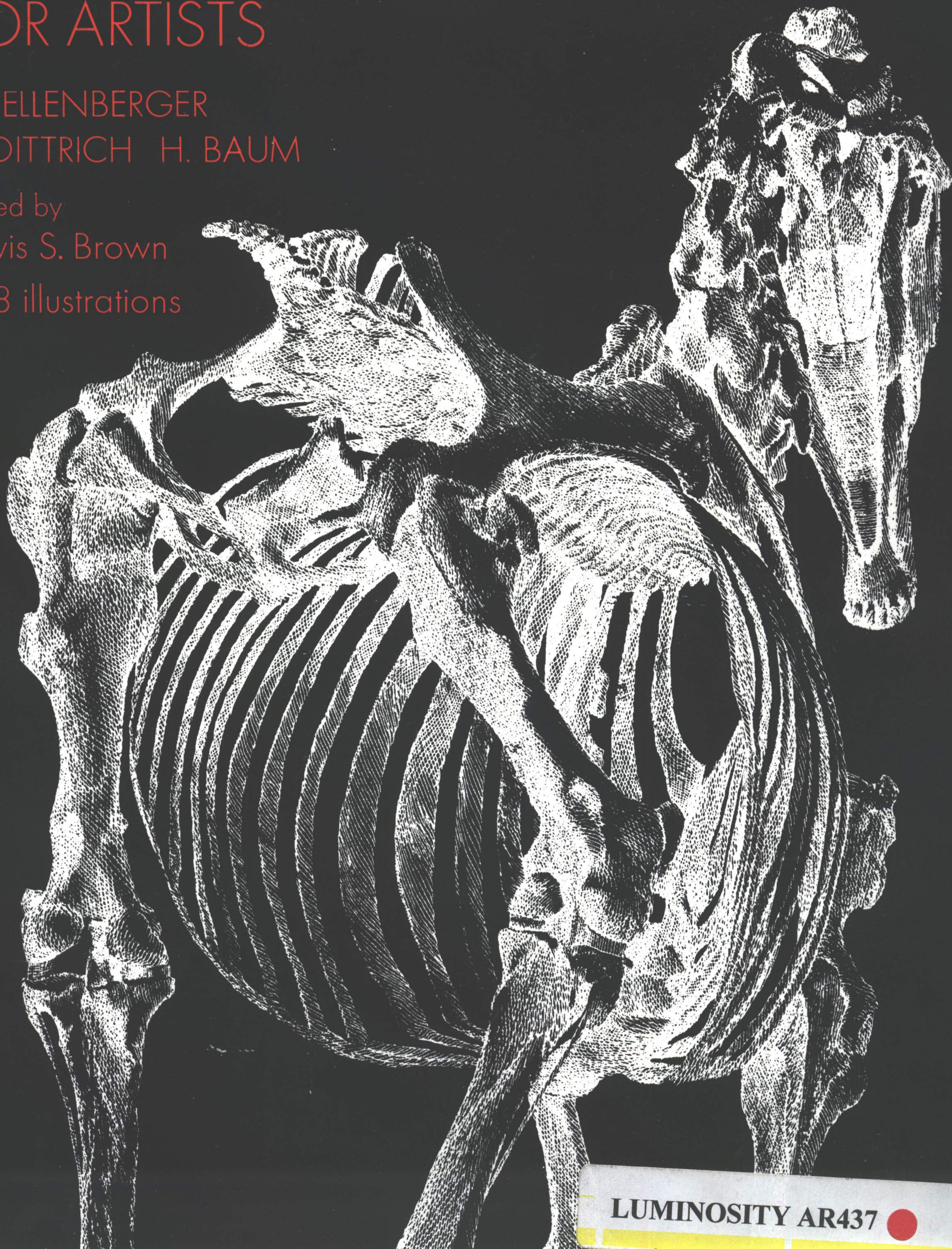FIGURES 19 20 21 22 23 24 25 26 27 28 29

- | | | |
|--|--|--|
| a, a', a''— <i>M. extensor digitorum pedis longus</i> | l—Muscular attachment of tendon from <i>M. interosseus medius</i> to extensor tendon | 27—External condyle of the os femoris |
| b, b'— <i>M. tibialis anterior</i> | m— <i>M. flexor digitorum pedis longus</i> | 28—Crista tibiae |
| c— <i>M. peronaeus longus</i> | n—A ligament of the tarsus | 29—Sesamoid bones of the 1st digital joint |
| d— <i>M. extensor digiti quarti proprius</i> | o— <i>M. politeus</i> | 30—Phalanx prima |
| e, e'— <i>M. flexor digitorum pedis profundus</i> | 20—Patella | 31—Phalanx secunda |
| e''—Strengthening tendons for the flexor tendons | 21—Tibia | 32—Phalanx tertia |
| f, f'— <i>Mm. gastrocnemii</i> | 21'—External condyle of the tibia | 33—Lower sesamoid bone |
| g—Superficial flexor tendon | 22—Tarsus | 34—Front view of hoof |
| h— <i>M. interosseus medius</i> | 23—Os malleolare | 35—Bottom view of hoof showing primary and secondary claws |
| i—Annular ligaments | 24—Tuber calcanei | 36—Rear view of hoof showing primary and secondary claws |
| k—External lateral ligament of the tarsal articulation | 25—Metatarsus | |

AN ATLAS OF ANIMAL ANATOMY FOR ARTISTS

W. ELLENBERGER
H. DITTRICH H. BAUM

Edited by
Lewis S. Brown
288 illustrations



LUMINOSITY AR437

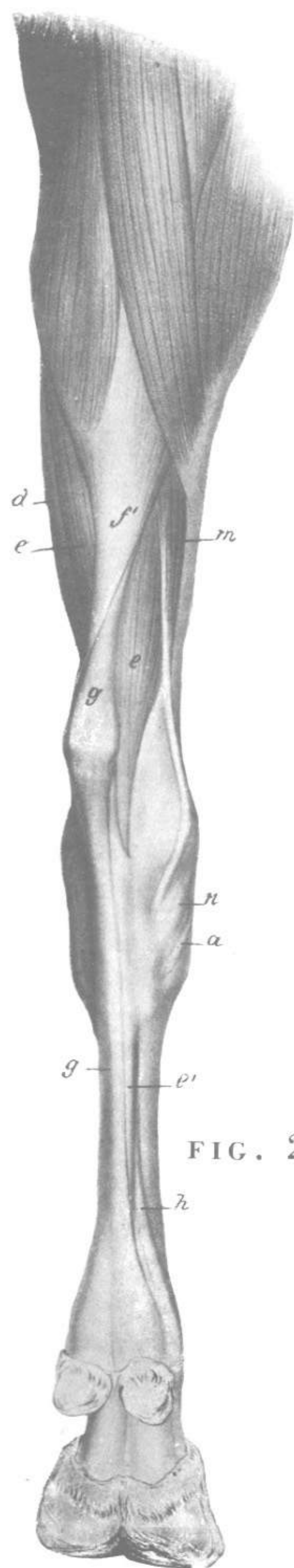


FIG. 23

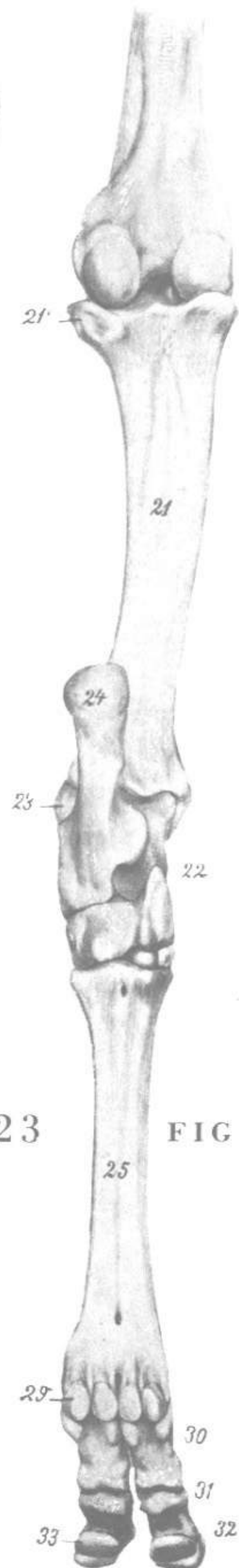


FIG. 24

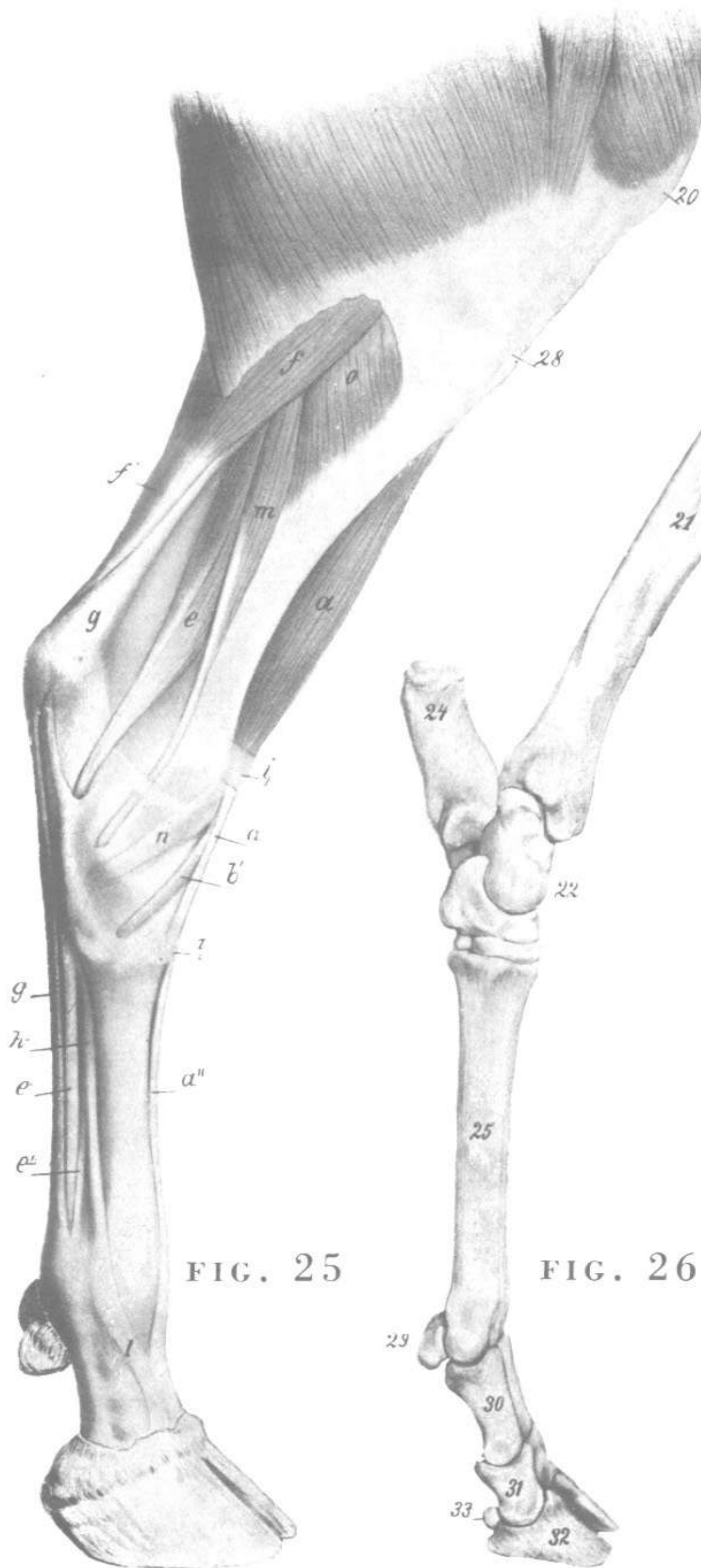


FIG. 25

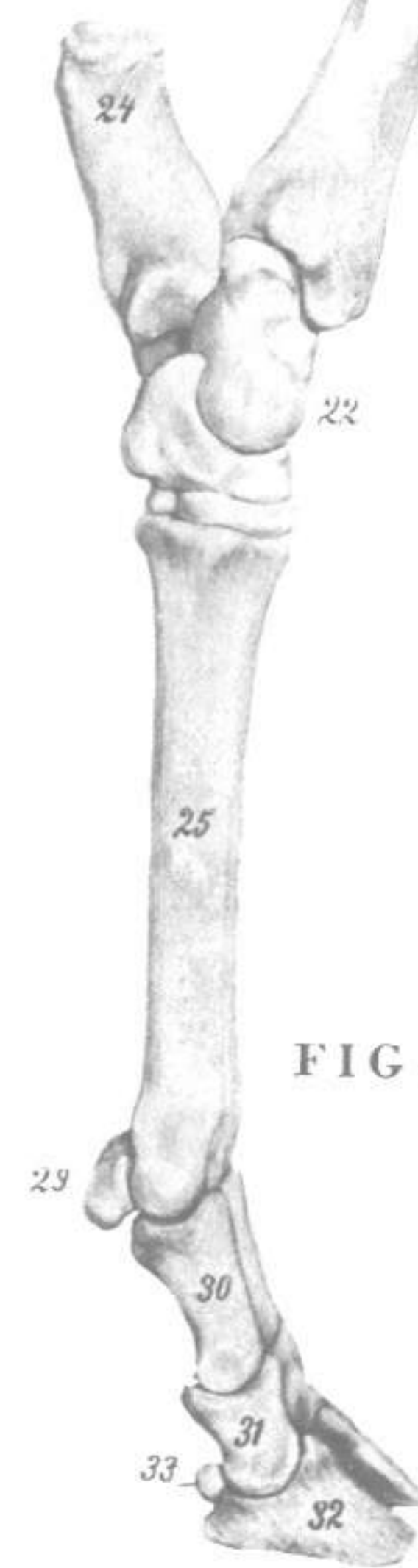


FIG. 26

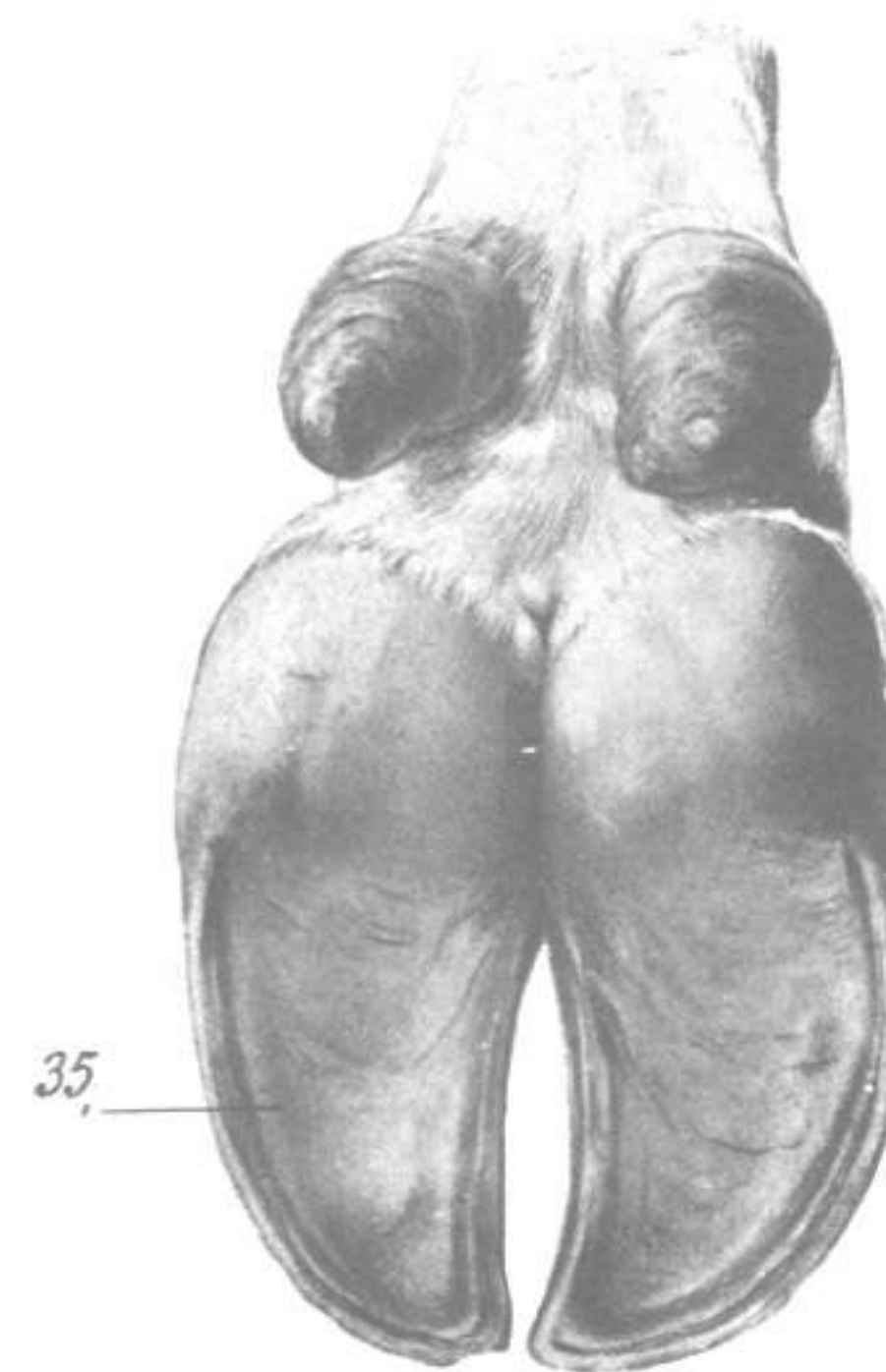


FIG. 28

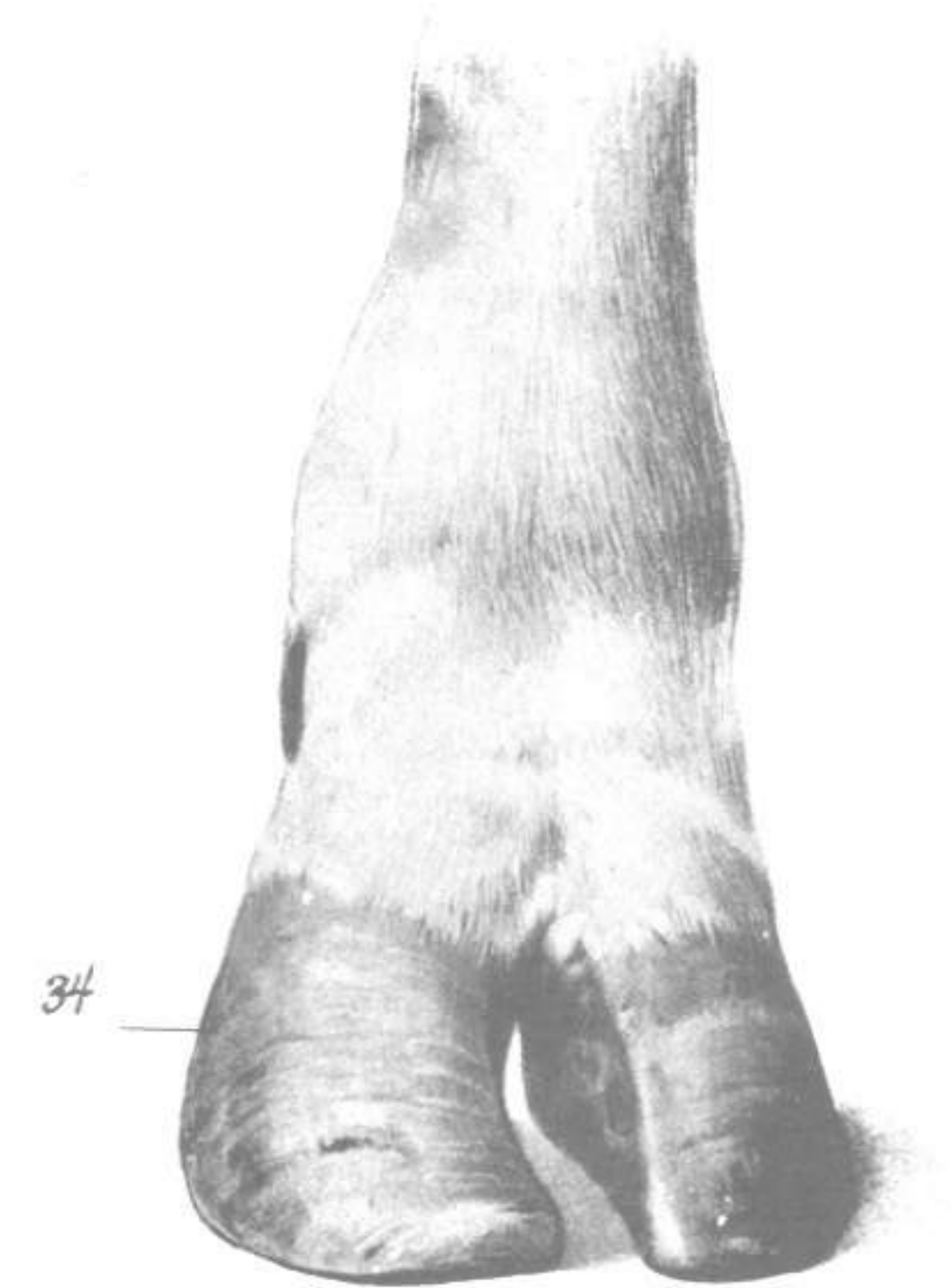


FIG. 27

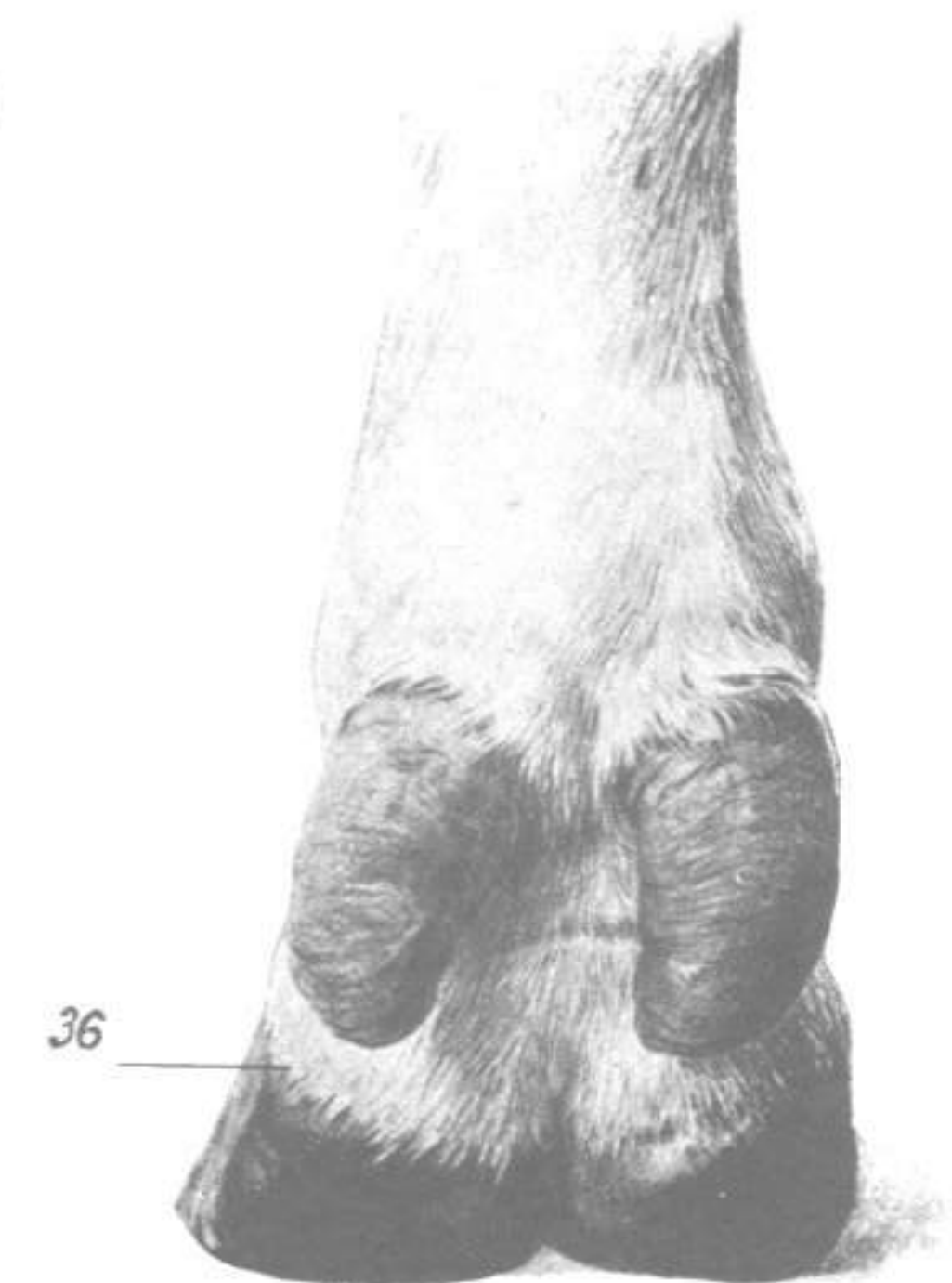


FIG. 29

THE COW AND BULL - PLATES 10 11 12

FIGURES 30 31 32 33 34 35 40 41 42 44 45 46 47 48 49 50 51 52

- a, a'—*M. levator labii superioris proprius*
 b—*M. levator nosolabialis*
 c, c'—Cervical part and mastoidal part of the *M. cleidomastoideus*
 d—*M. sternomandibularis*
 d'—*M. sternomastoideus*
 e—End of the *M. sternohyoideus*
 e'—A thin muscular fasciculus
 f—*M. caninus s. pyramidalis nasi*
 g—*M. zygomaticus major*
 g'—*M. zygomaticus minor s. M. malaris*
 h—*M. buccinator*
 i—*M. depressor s. quadratus labii inferioris*
 k—*M. orbicularis oris*
 m—*M. masseter*
 n—Depressor of the ear
 o'—Inferior adductor of the auricle
 o''—Superior adductor of the auricle
 o'''—Short levator of the auricle
 p, p'—*M. scutularis*
 q—Long abductor of the auricle
 u—*M. frontalis*
 w—*M. mylohyoideus*
 z—*M. orbicularis oculi*
 l—Auricula
 2—External or posterior edge of the auricle
 3—Internal or anterior edge of the auricle
 8—Scutulum
 9—*Arcus zygomaticus*
 11—*Proc. coronoideus* of the lower jawbone
 12—Orbital arch
 13, 13', 13'', 13'''—*Os occipitale*
 14—*Os parietale*
 15—*Os frontale*
 16—*Os temporale*
 17—*Meatus acusticus externus*
 18—Temporo-maxillary joint
 19—Orbita
 20—*Os zygomaticum*
 21—*Os lacrimale*
 22—*Os nasale*
 23—*Os incisivum*
 24'—Lower incisor teeth
 24''—Edge of lower incisor tooth of a five-year old animal; this is worn away in a ten-year old animal
 26—Maxilla
 27—Facial condyle
 28—Incisor (unpaired) part of the lower jawbone
 28'—Molar (paired) part of the lower jawbone
 30—Branch of the lower jaw
 30'—Angle of the lower jaw
 31—Condylod process of the lower jaw
 32—1st cervical vertebra
 34—Upper lateral cartilage
 37—*V. maxillaris externa*
 38—*V. jugularis*
 39—*V. facialis*
 44—*Glandula parotis*
 45—Chin
 48—Angle of the mouth
 49—Muzzle
 50, 50'—*Glandula submaxillaris*
 51—Upper eyelid
 51'—Lower eyelid
 52—3rd eyelid containing *cartilago nictitans*
 53—*Caruncula lacrimalis*
 54—*Lacus lacrimalis*
 55, 55'—Eyeball
 56—Pupil
 57—Black-brown pigmented marginal band
 58—Medial eyelid band
 59—Larynx
 60—Tip of the tongue
 61—Large papillae on the mucous membrane of the lips
 62—Part of the oral-cavity floor lying under the tip of the tongue
 63—Plane of the cross section of the head shown in Fig. 40 on Plate 10
 64—Plane of the cross section of the head shown in Fig. 41 on Plate 10
 65—Plane of the cross section of the head shown in Fig. 42 on Plate 10

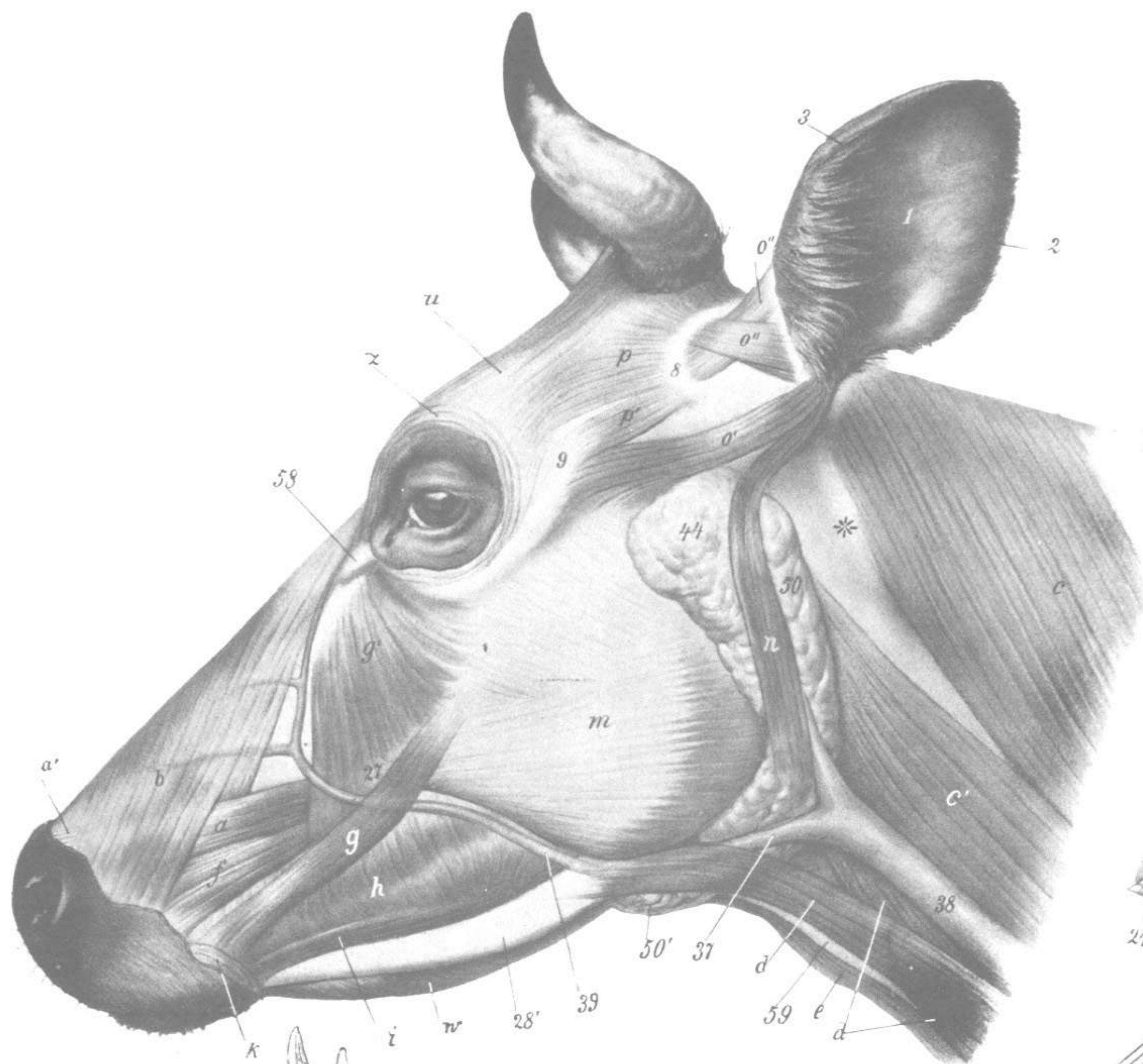


FIG. 30

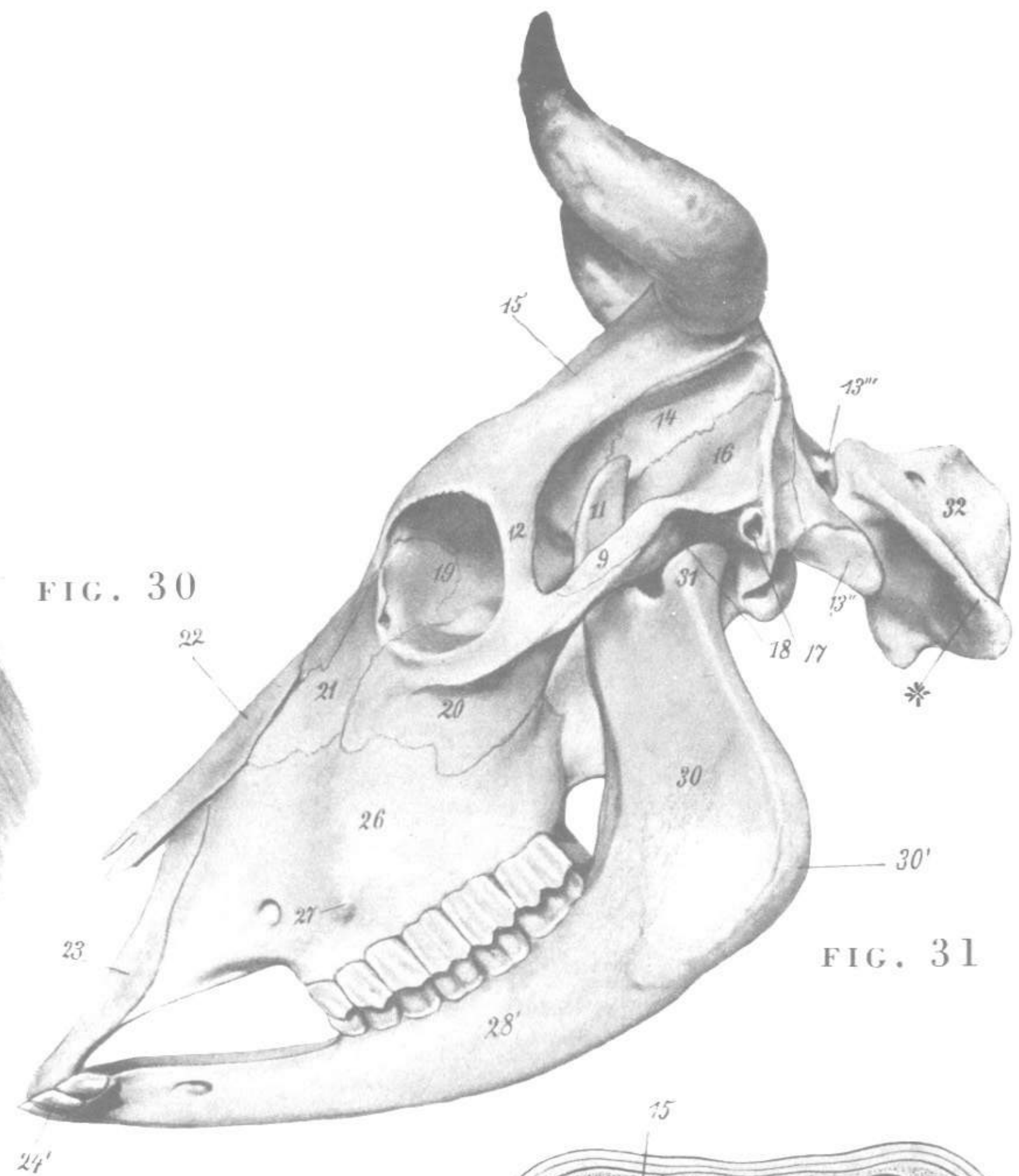


FIG. 31

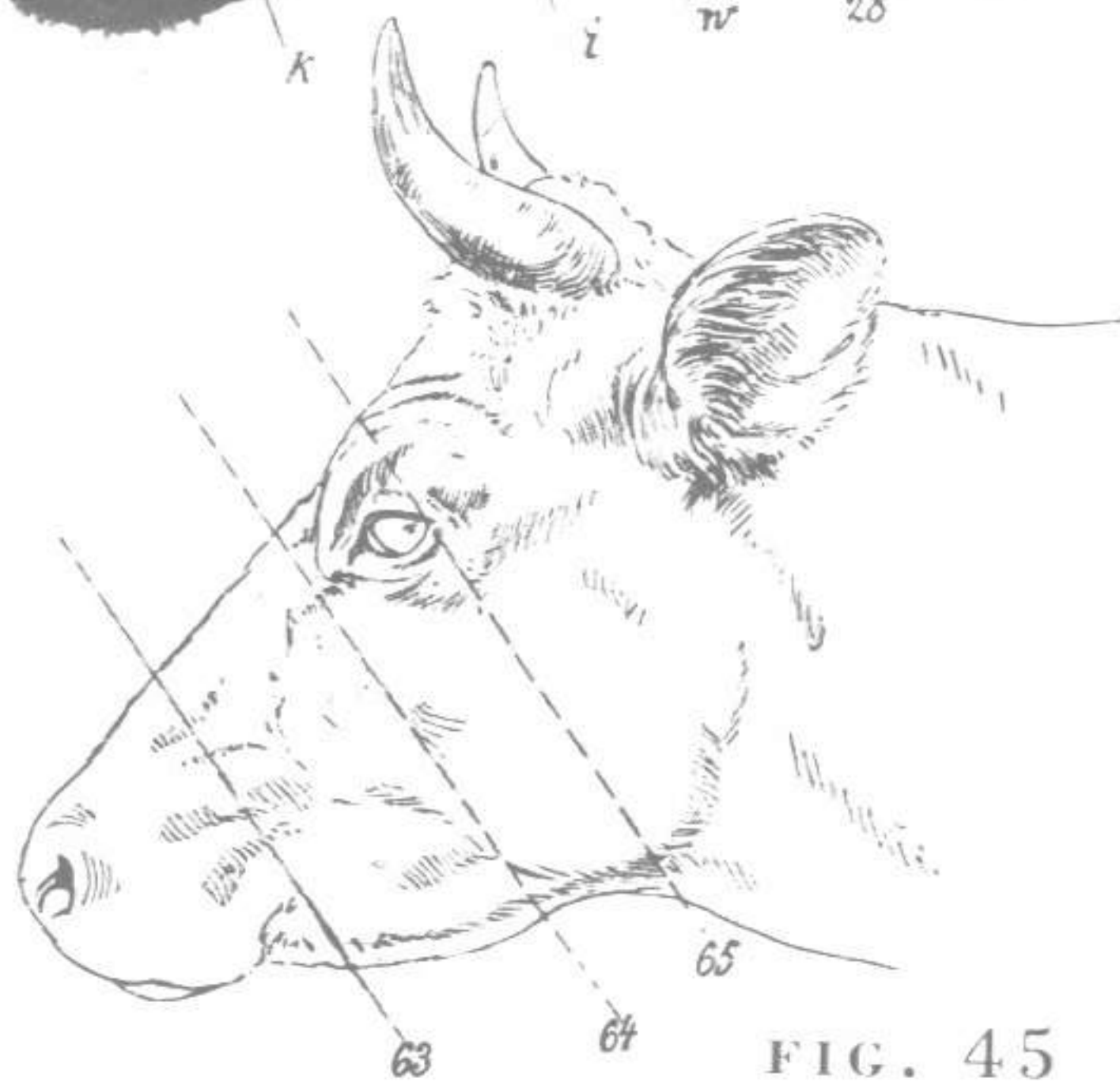


FIG. 45

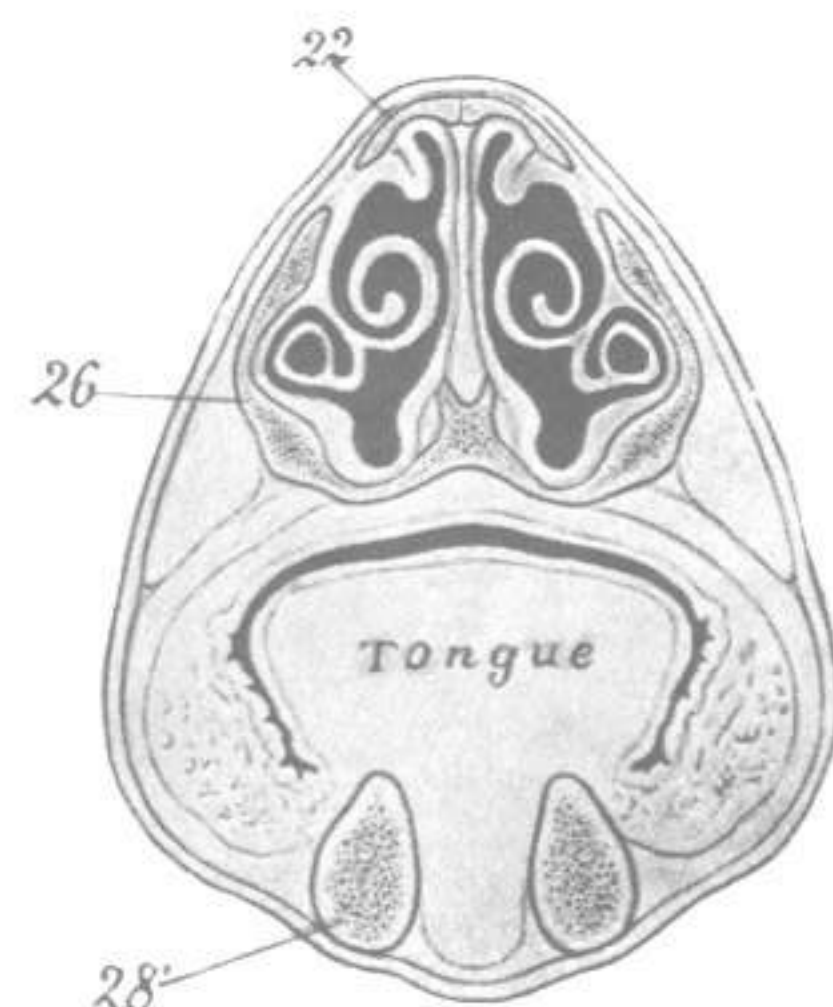


FIG. 40

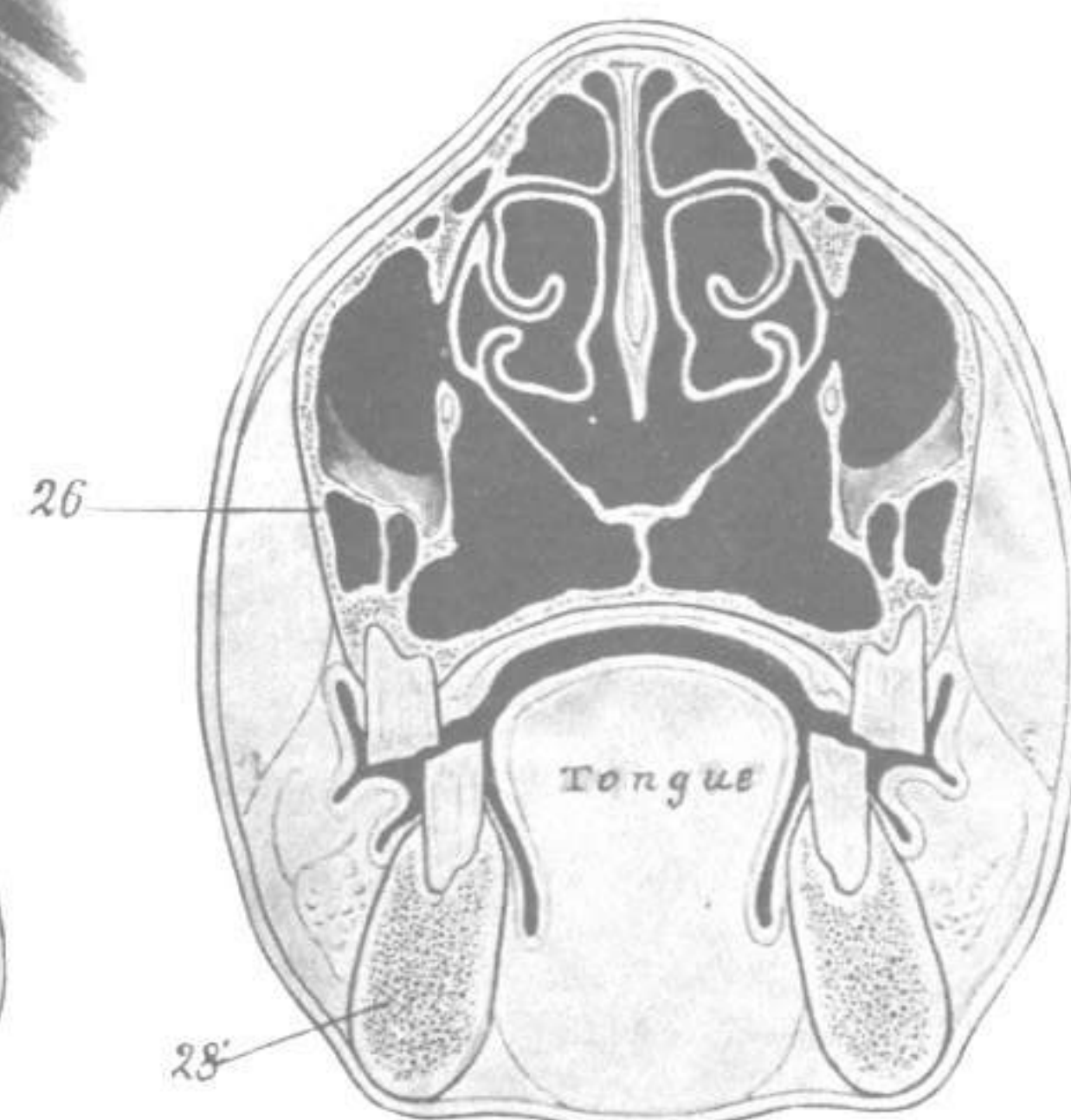


FIG. 41

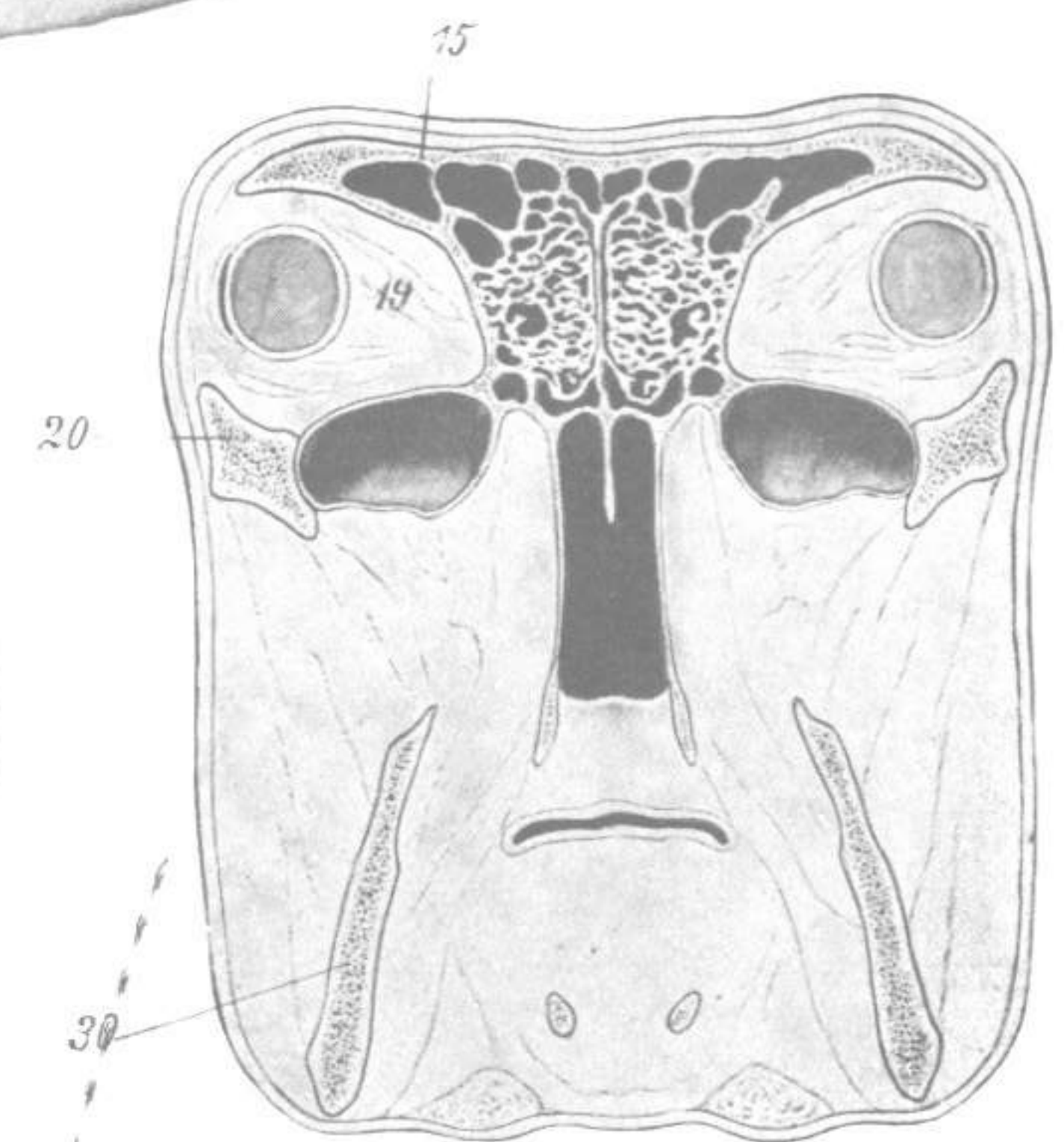
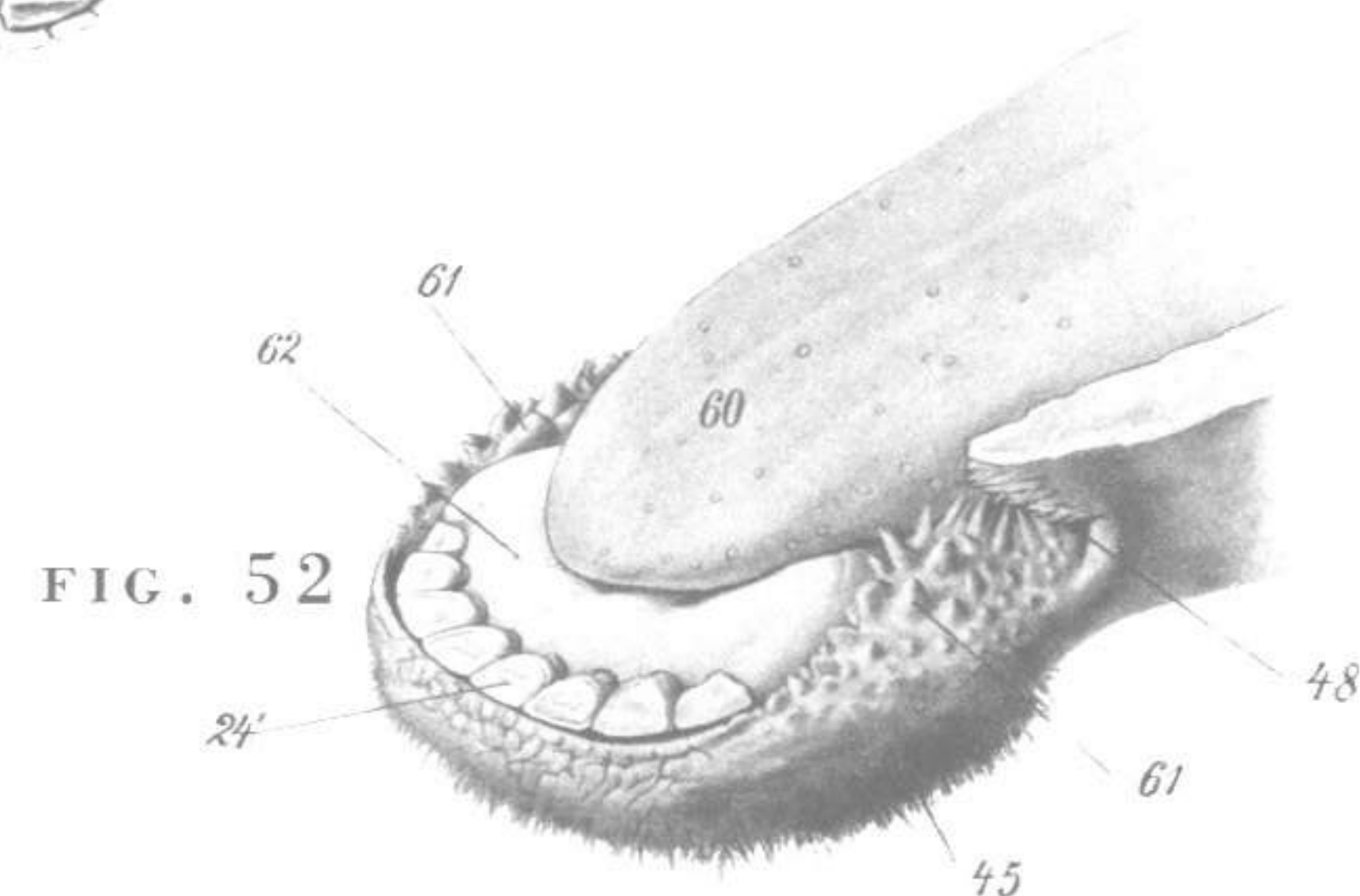
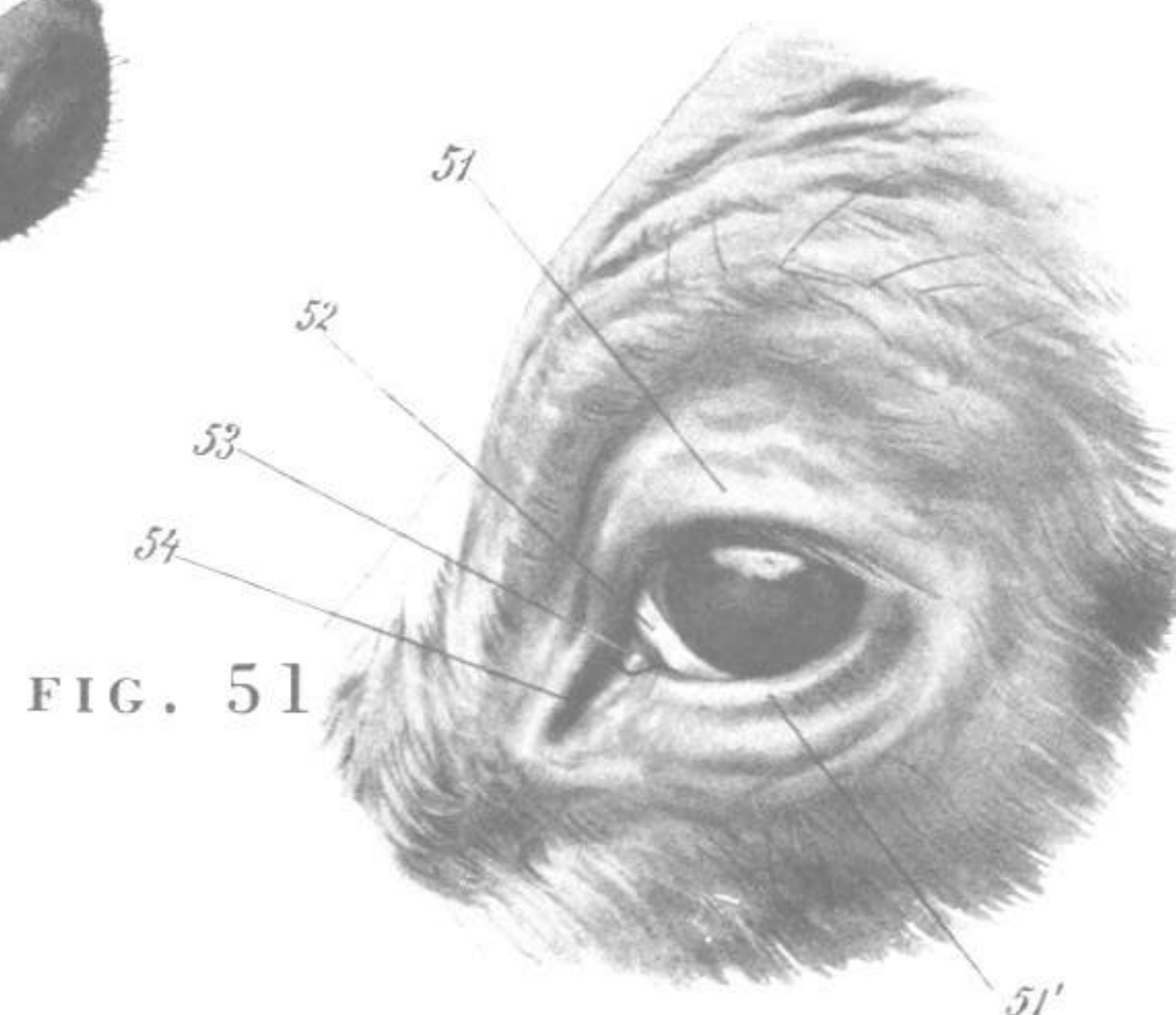
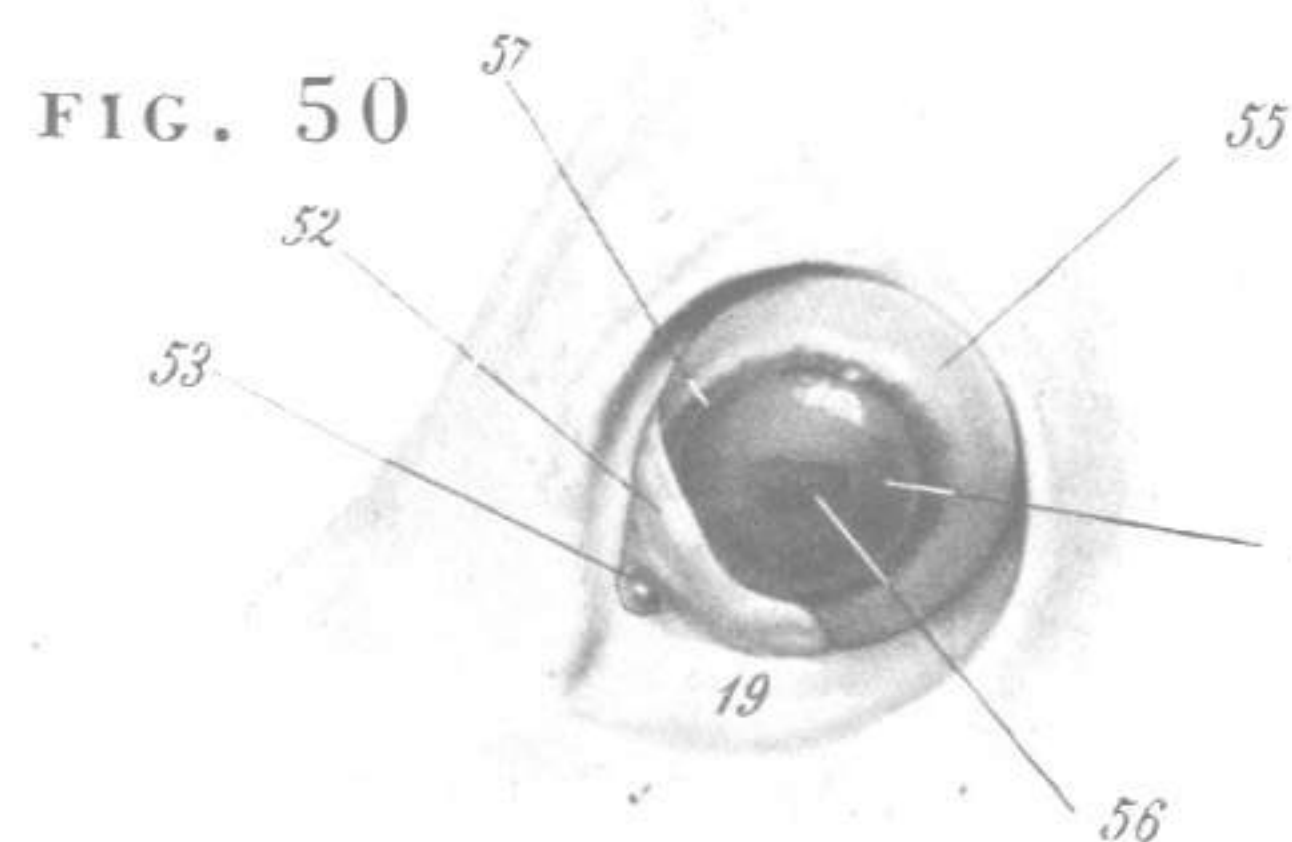
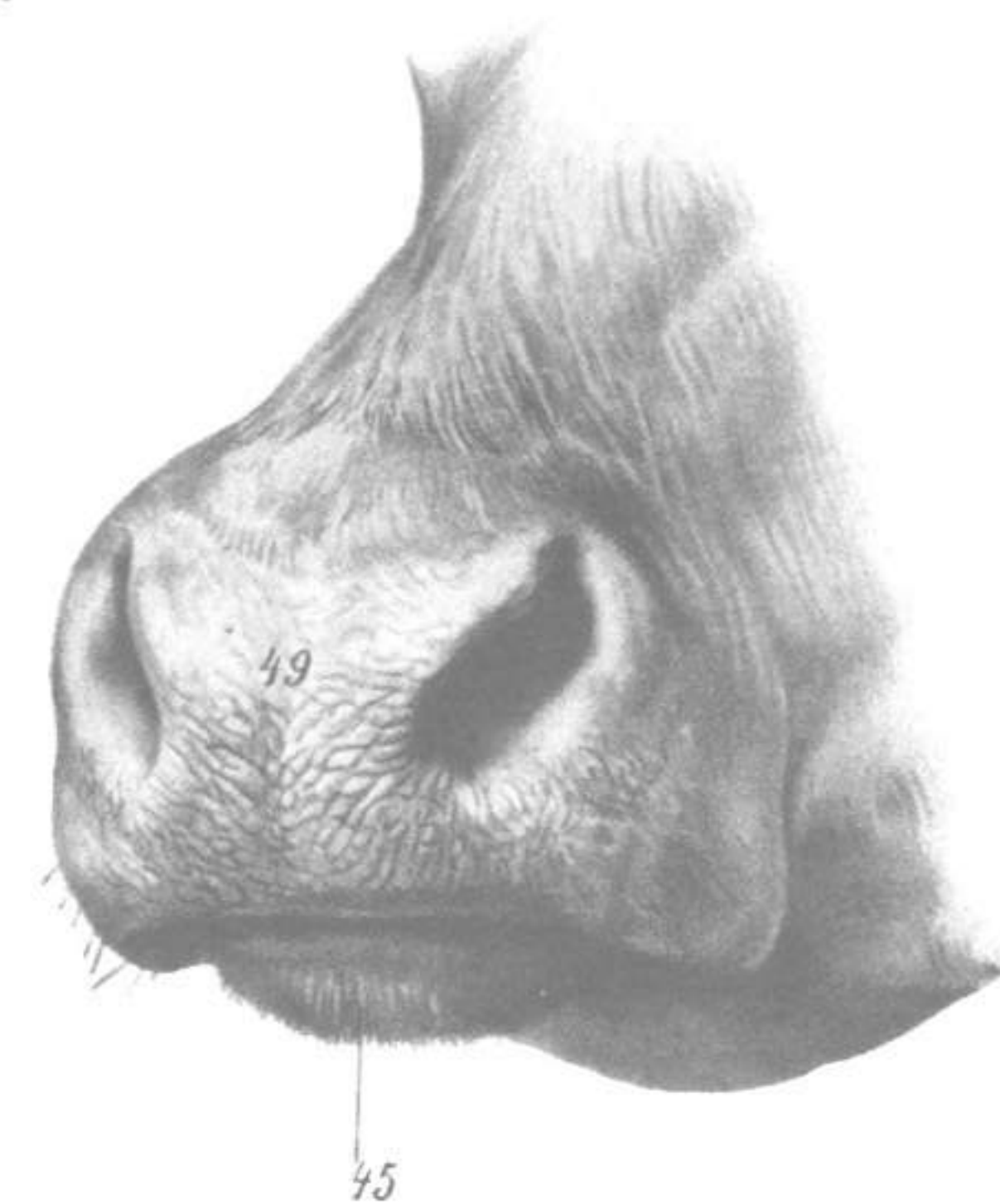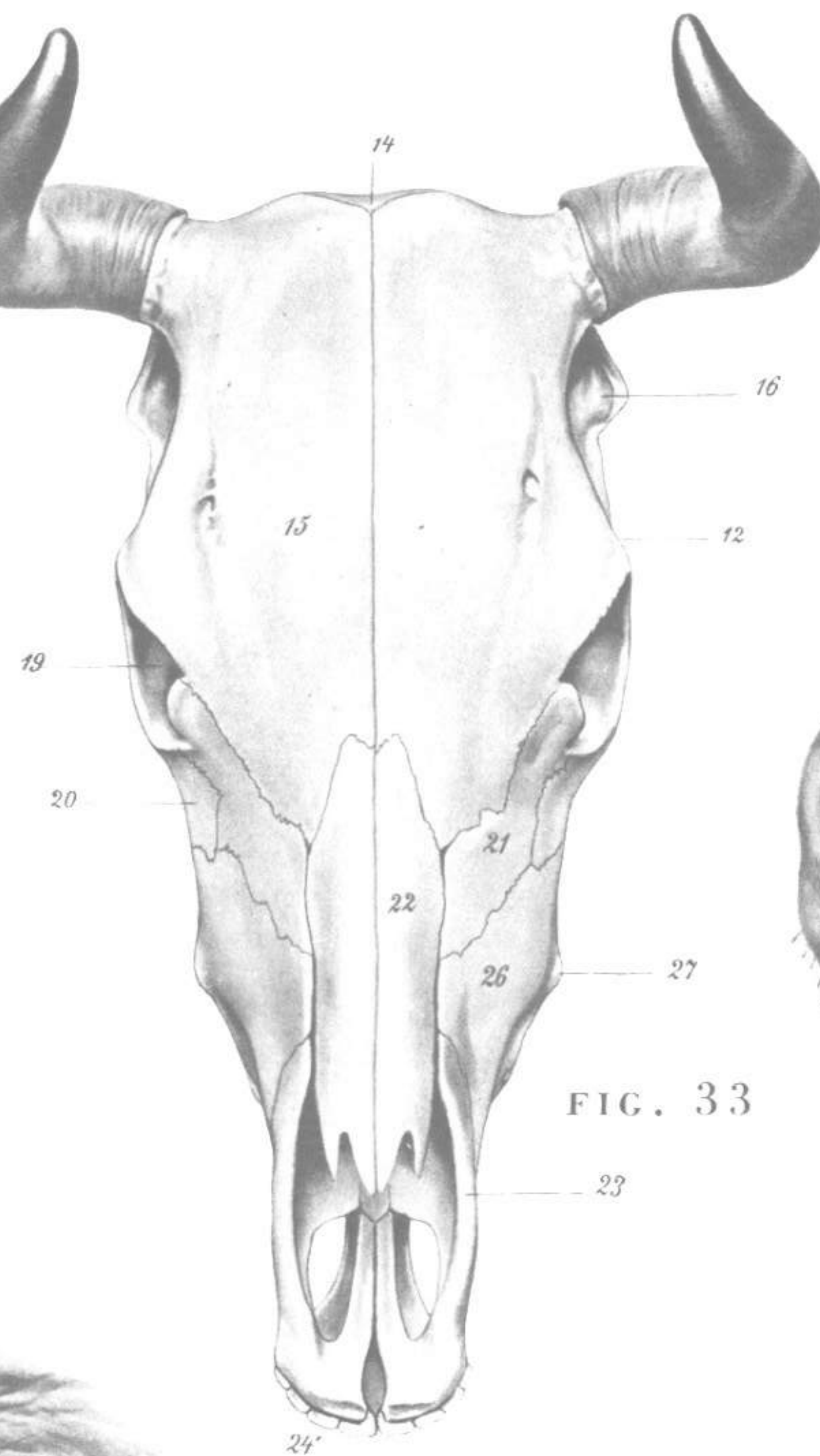
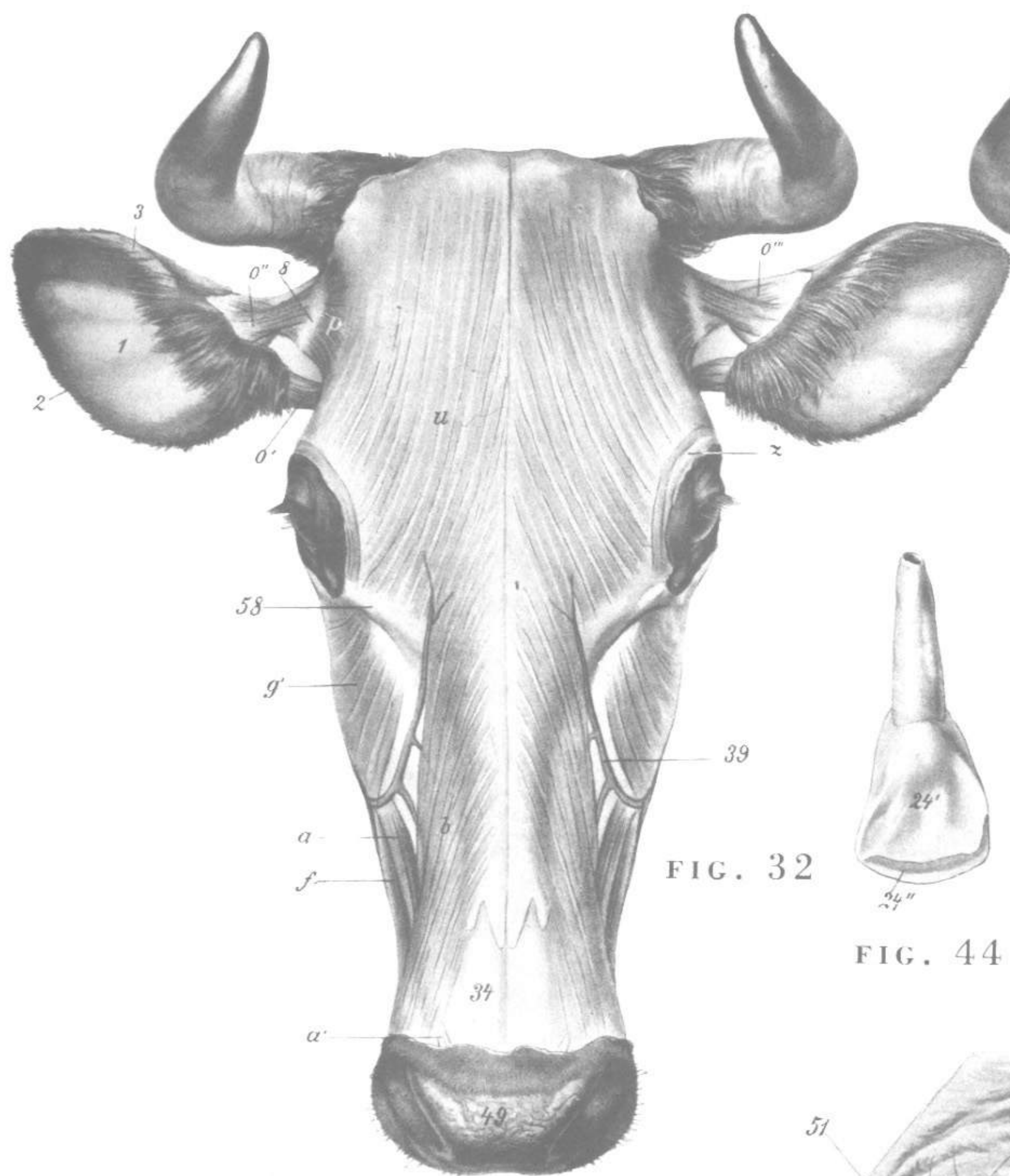
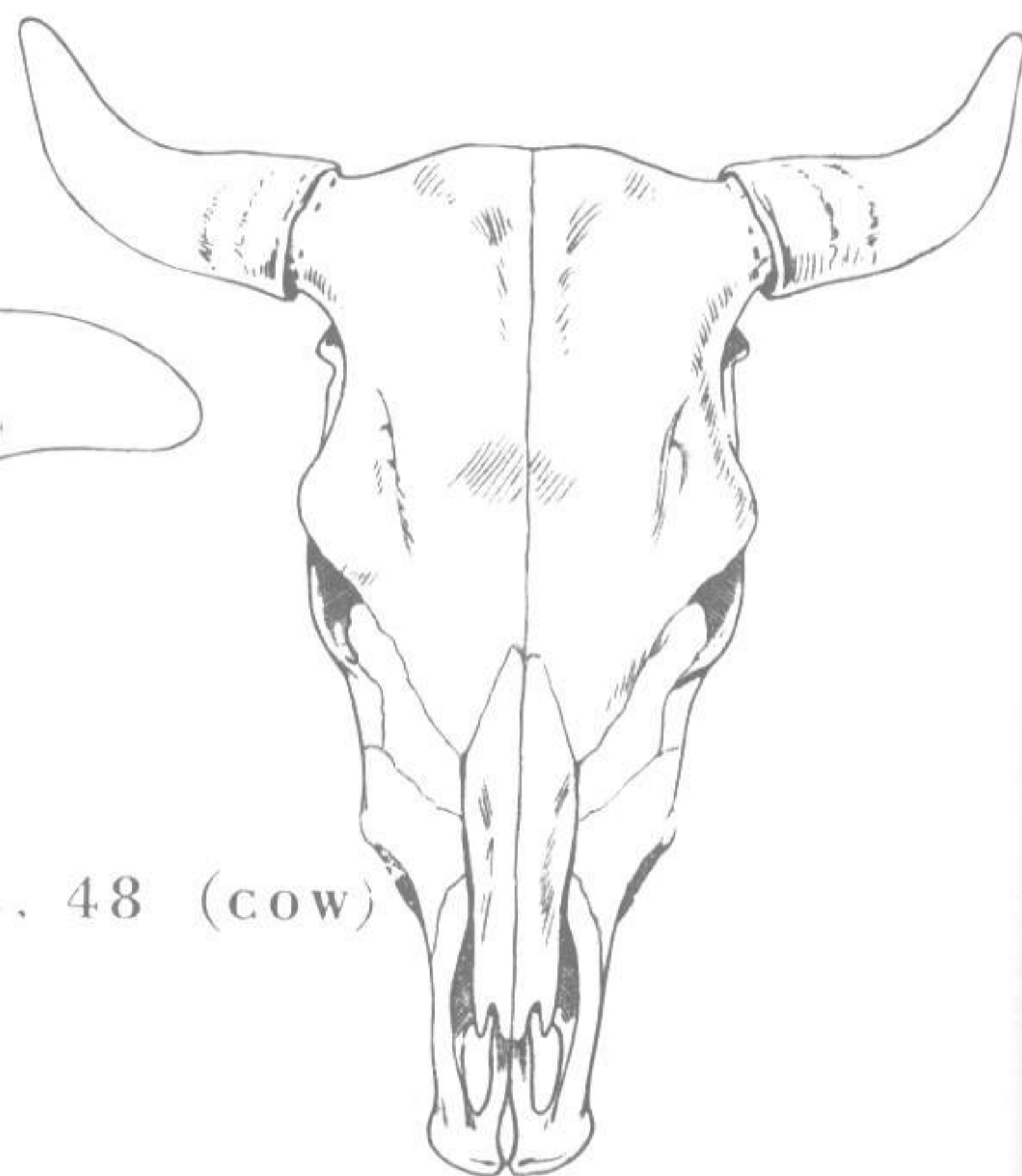

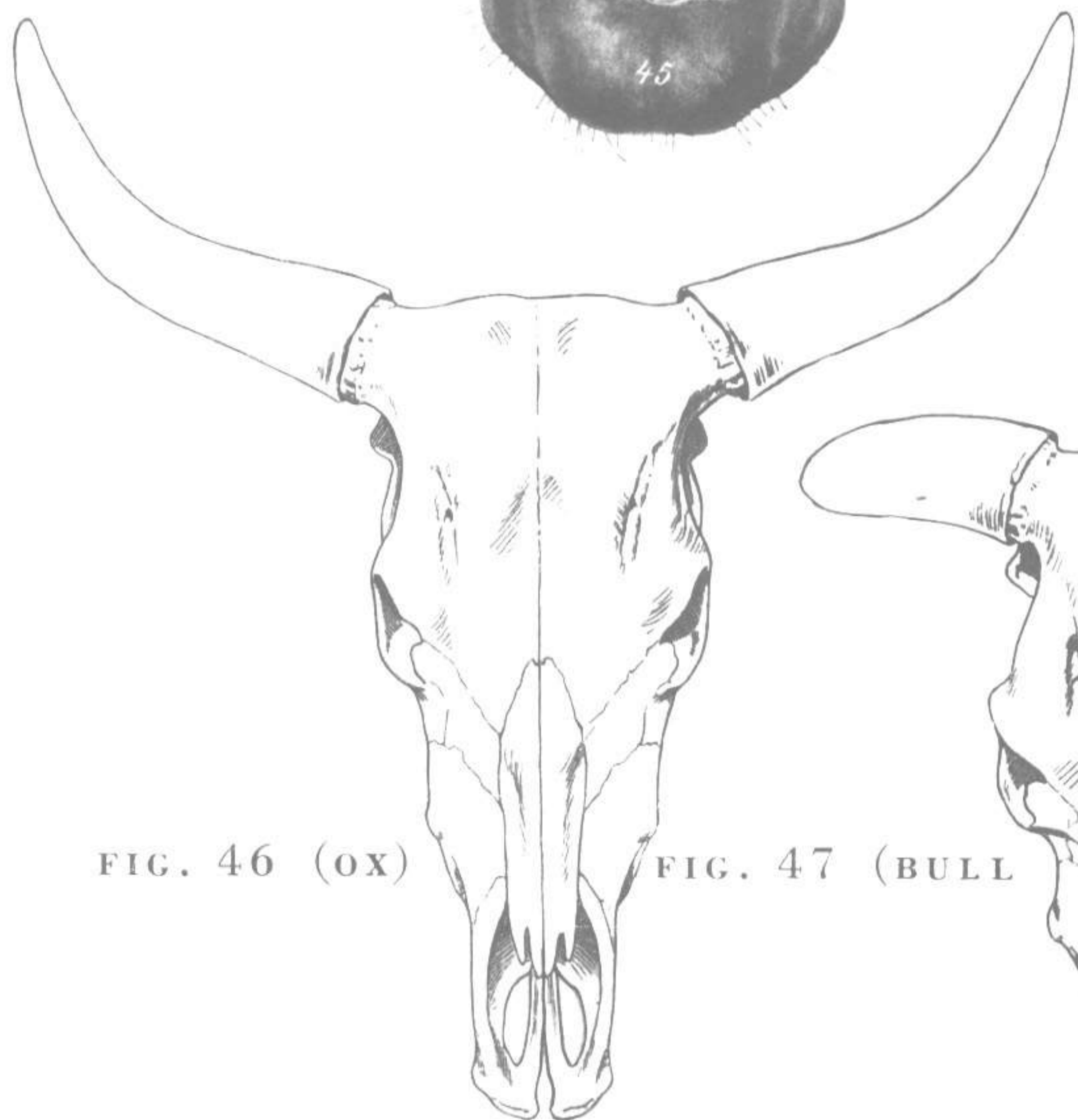
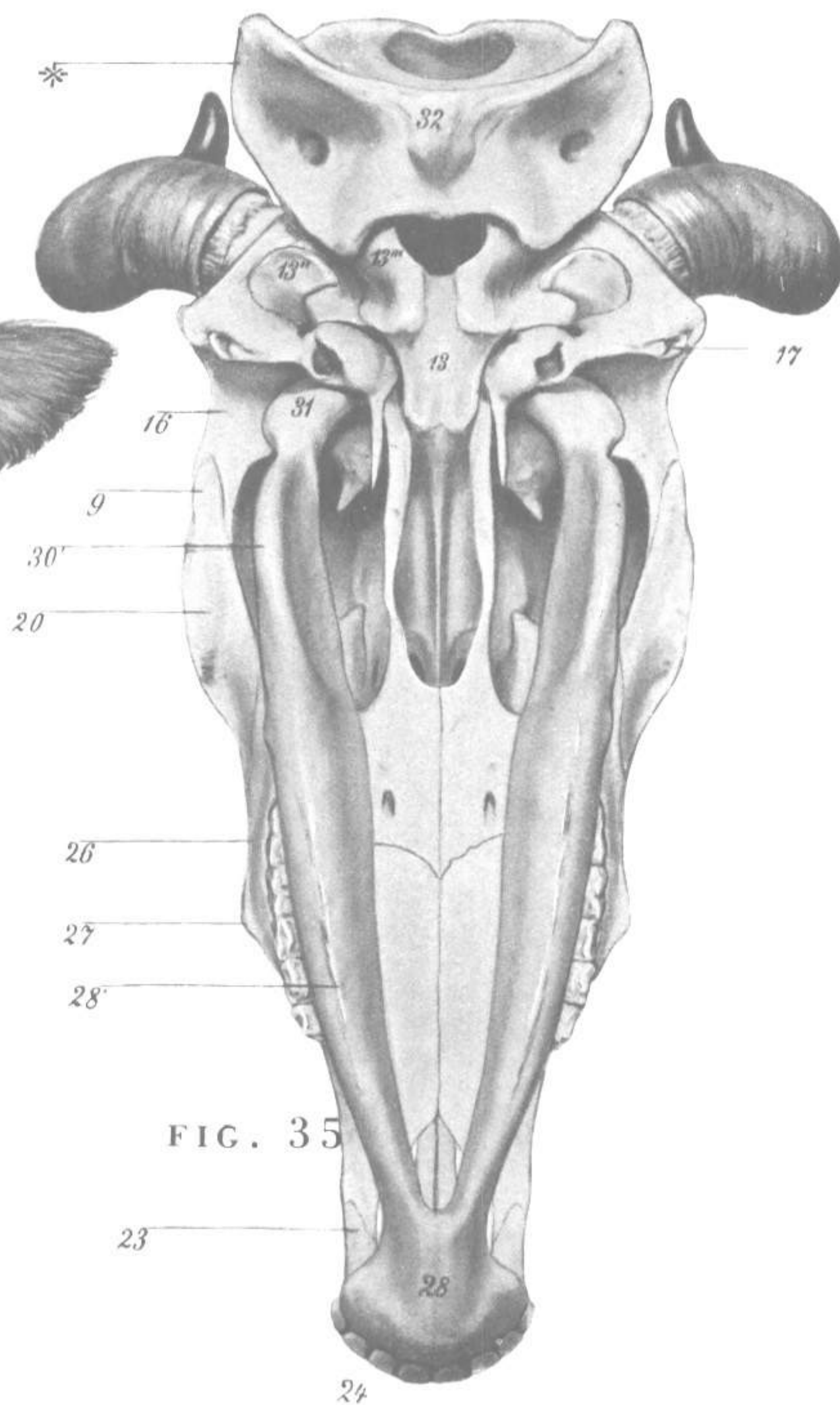
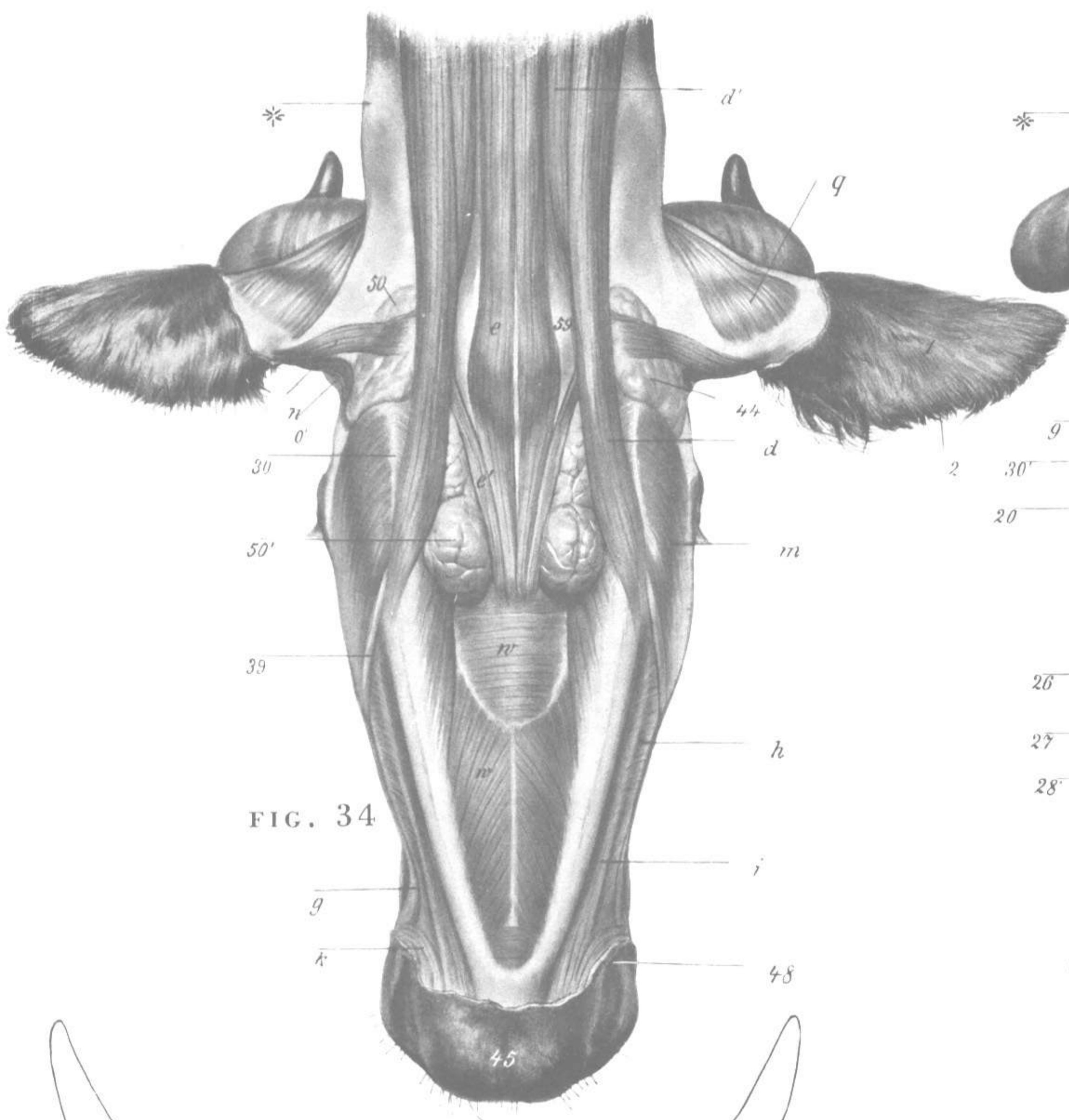


FIG. 42

THE COW AND BULL PLATE 11



THE COW AND BULL PLATE 12



THE COW AND BULL - PLATES 13 14

FIGURES 55 56 57 58 59 60 61 62

- a—*M. trapezius*
 b—Shoulder-transverse process muscle
 c—*M. cleido-mastoideus*
 e, e'—*M. deltoideus*
 k—*M. latissimus dorsi*
 l—*M. obliquus abdominis externus*
 m—*M. serratus posterior*
 m'—Lumbo-dorsal fascia
 o—*M. tensor fasciae latae*
 p—*M. gluteus medius*
 q—*M. biceps femoris*
 s, t—Long and short levators of the tail
 u—Abductor of the tail
 v—Muscles of the ear
 w—Free edge of the pelvic ligament
 1H—1st cervical vertebra
 7H—7th cervical vertebra
 1L—1st lumbar vertebra
 6L—6th lumbar vertebra
 K—Sacrum
 1R—1st thoracic vertebra
 6R—6th rib
 12R—12th thoracic vertebra
 13R—13th rib
 1S—1st caudal vertebra
 *—Ala border of atlas
- 1—Scapula
 1'—Border of the scapular cartilage
 2—Spina scapulae
 3—Acromion
 4—Humerus
 5—Tuberculum majus of humerus
 8—Olecranon
 15—Ilium
 16—Tuber coxae
 16'—Tuber sacrale
 17—Tuber ischiadicum
 18—Femur
 19—Trochanter major of the femur
 24—Tuber calcanei
 27—Os occipitale
 28—Os parietale
 28'—Cerebral crest
 29—Os frontale
 30—Transverse processes of the lumbar vertebrae
 31—The two iliac condyles of the pelvis of the bull
 32—The two articular cavities of the pelvis of the bull
 33—The two tubera ischii of the pelvis of the bull
 (compare with pelvis of the cow in Fig. 57 on Plate 14)
- 34—Plane of the cross section of the front leg shown in Fig. 58 on Plate 14
 35—Plane of the cross section of the hind leg shown in Fig. 59 on Plate 14
 36—Radius and ulna
 37—*M. extensor carpi radialis*
 38—*M. extensor digiti tertii proprius*
 39—*M. extensor digitorum communis*
 40—*M. extensor digiti quarti proprius*
 41—*M. extensor carpi ulnaris*
 42—*M. flexor carpi ulnaris*
 43—*M. flexor carpi radialis*
 44, 44'—*M. flexor digitorum sublimis et profundus*
 45—*V. cephalica antibrachii*
 46—Tibia
 47—*M. extensor digitorum longus* and *M. tibialis anterior*
 48—*M. peroneus longus*
 49—*M. extensor digiti quarti pedis proprius*
 50, 50'—*M. flexor digitorum pedis profundus*
 51—*M. flexor digitorum longus*
 52—Tendo Achillis
 53—Superficial flexor tendon
 54—Cutaneous vein
 55—Outer skin

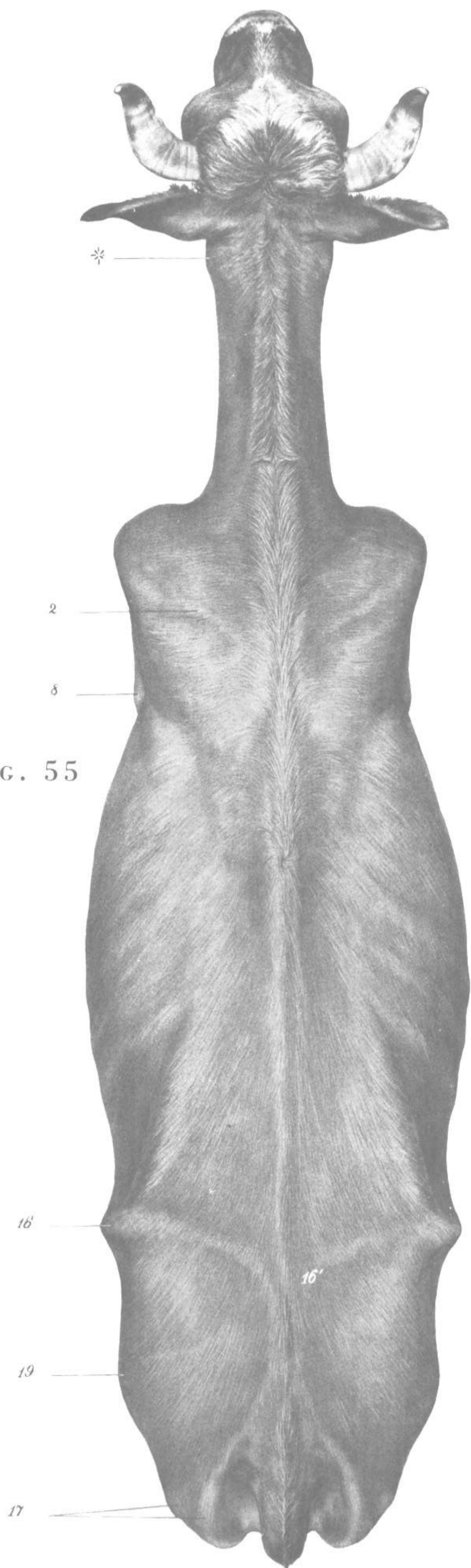


FIG. 55




FIG. 56

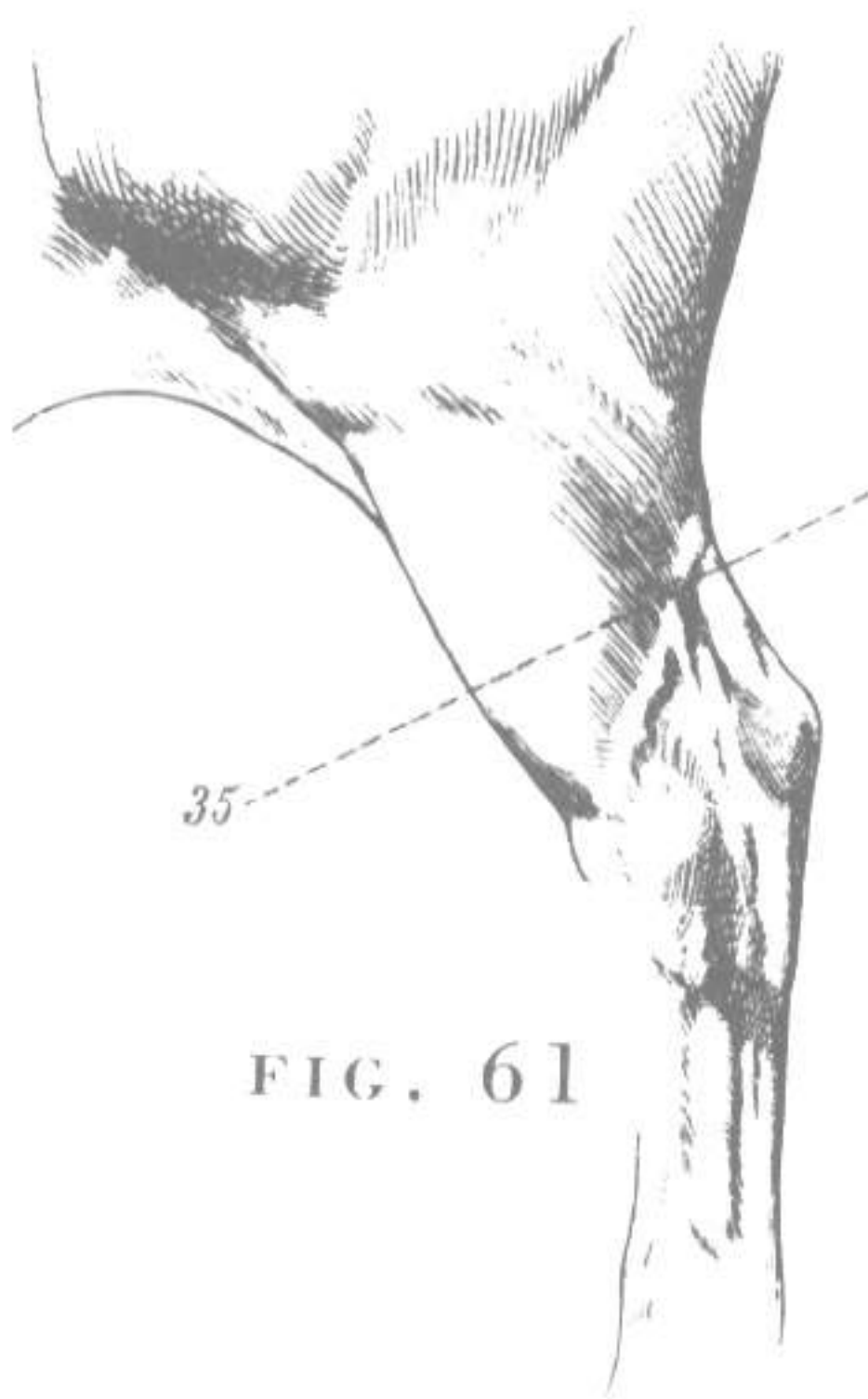
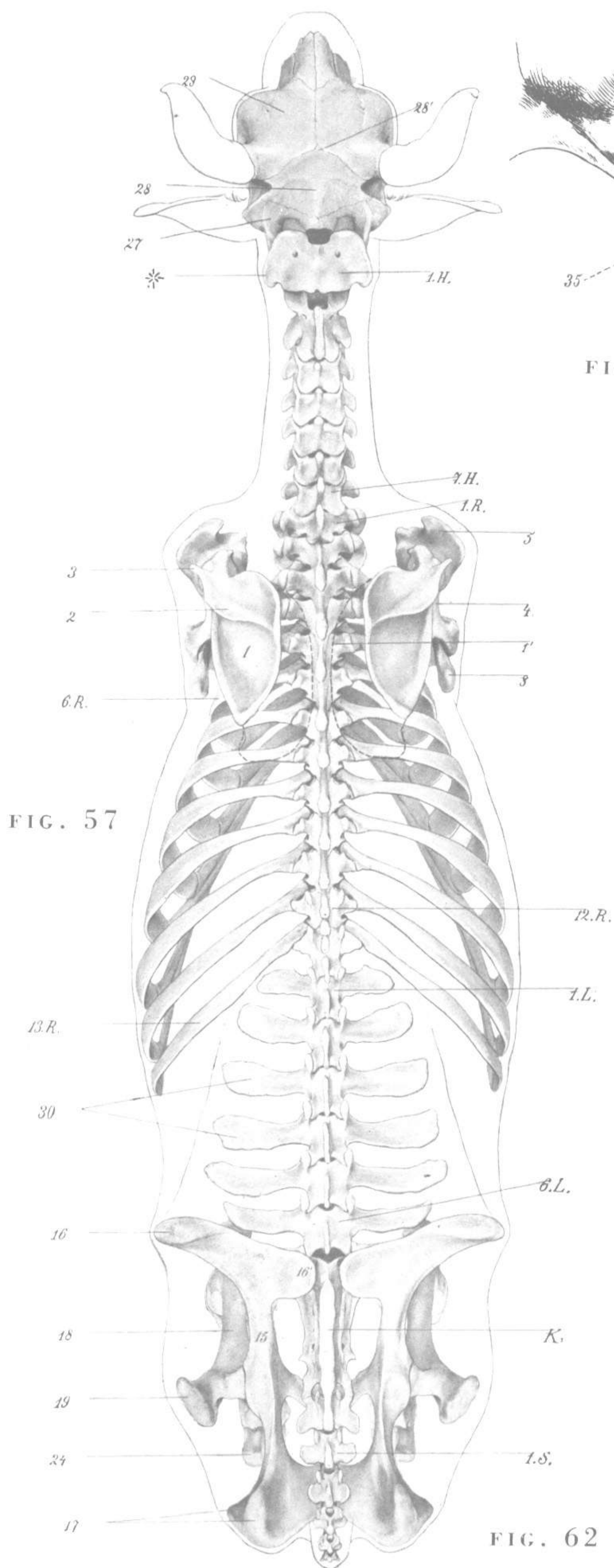


FIG. 61

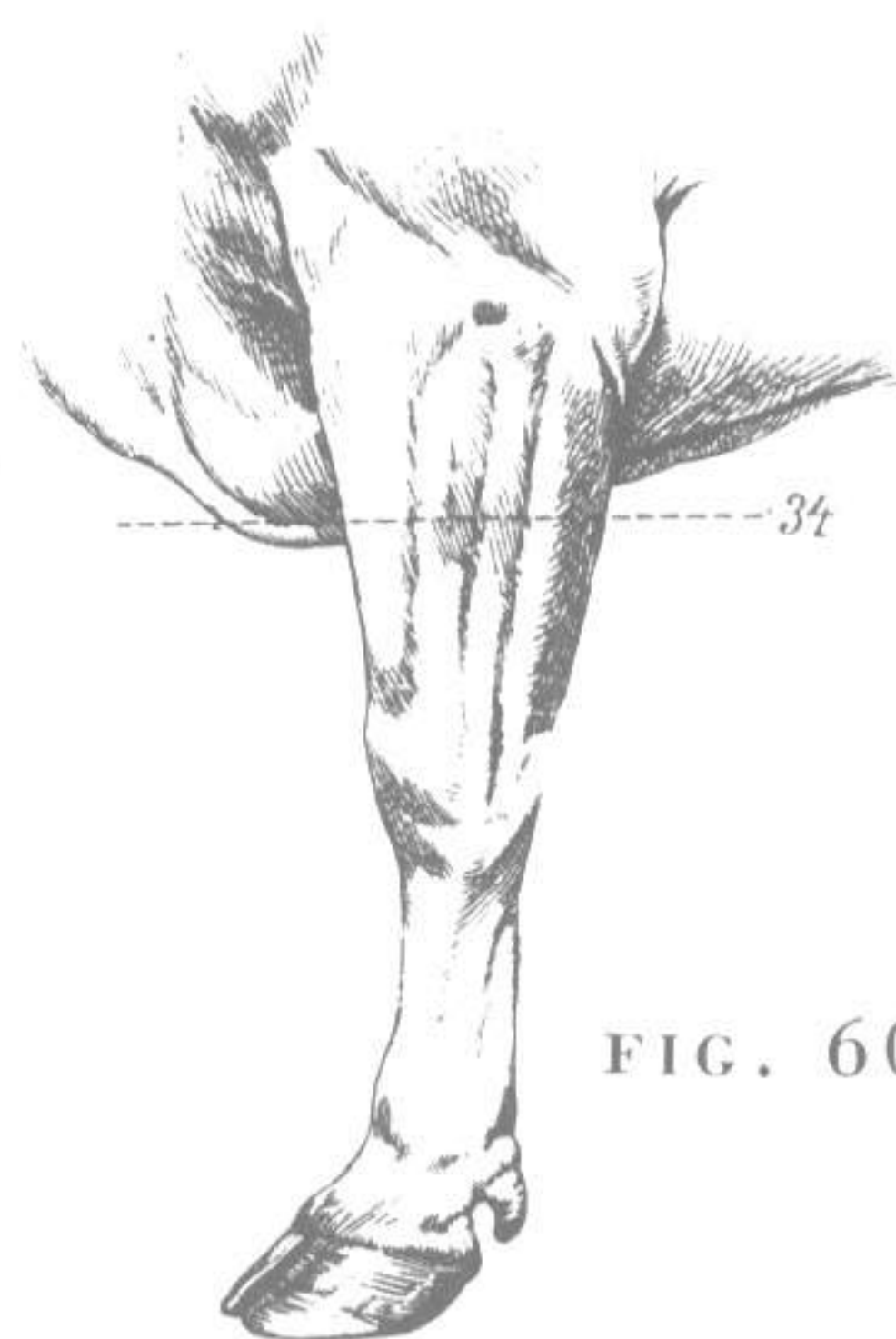


FIG. 60

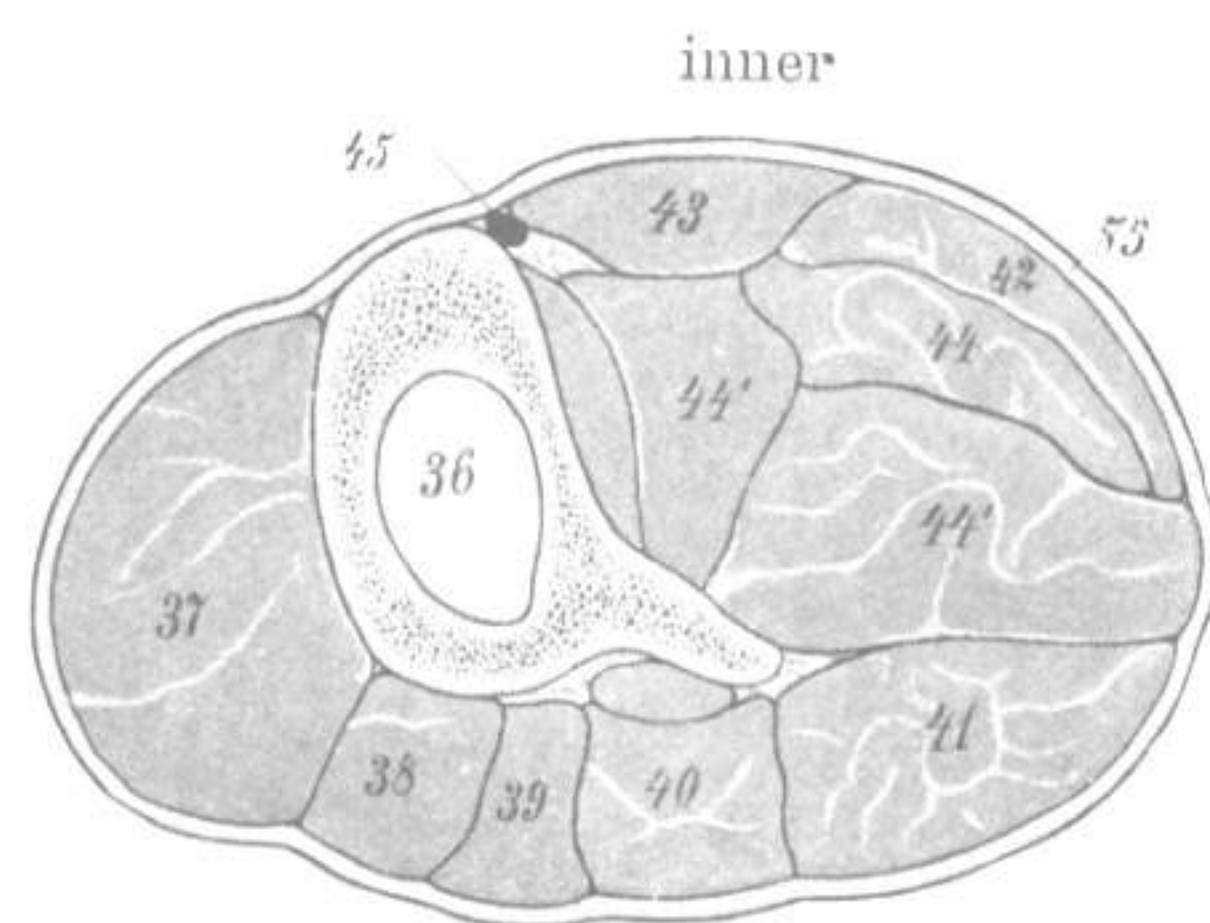


FIG. 58

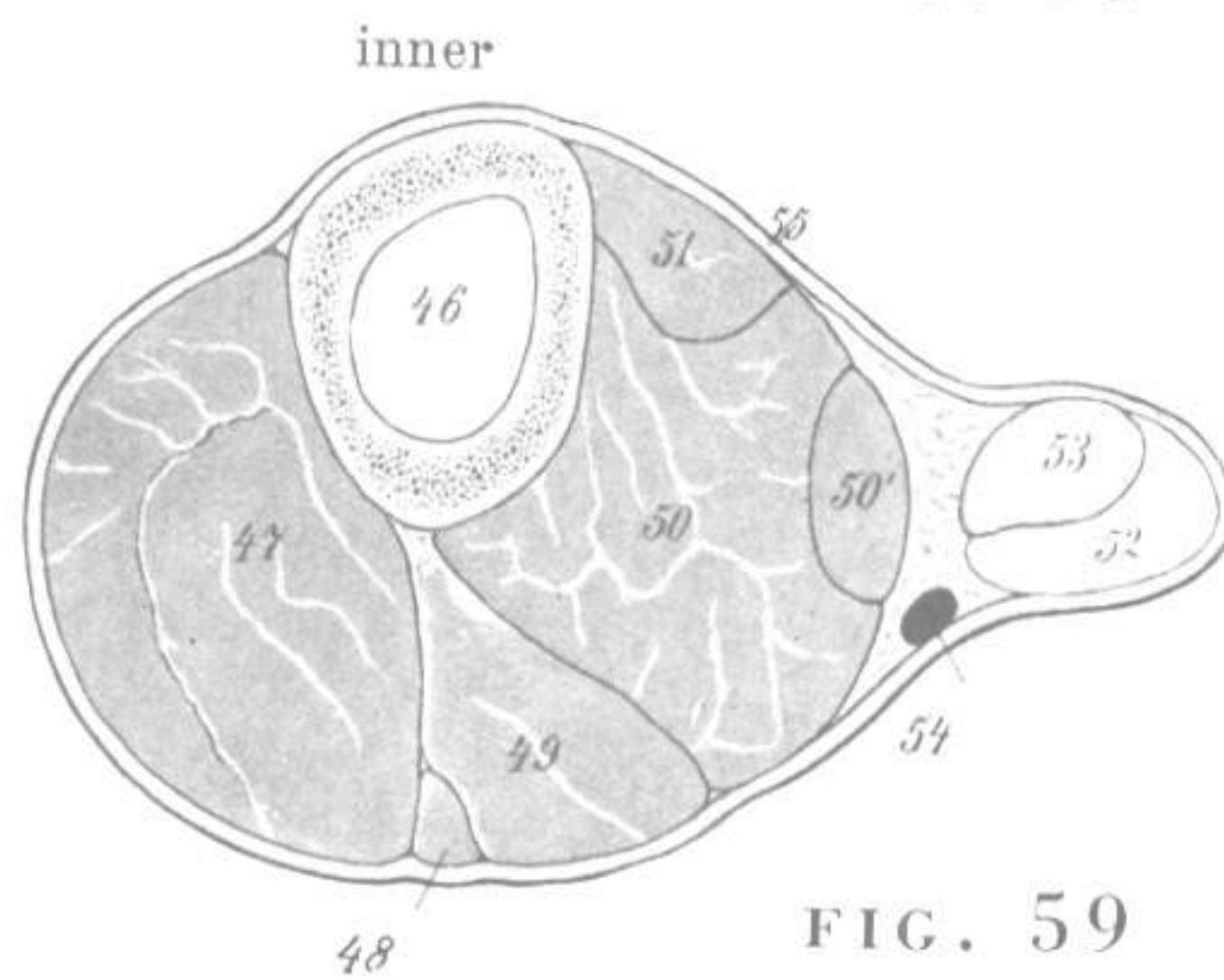


FIG. 59

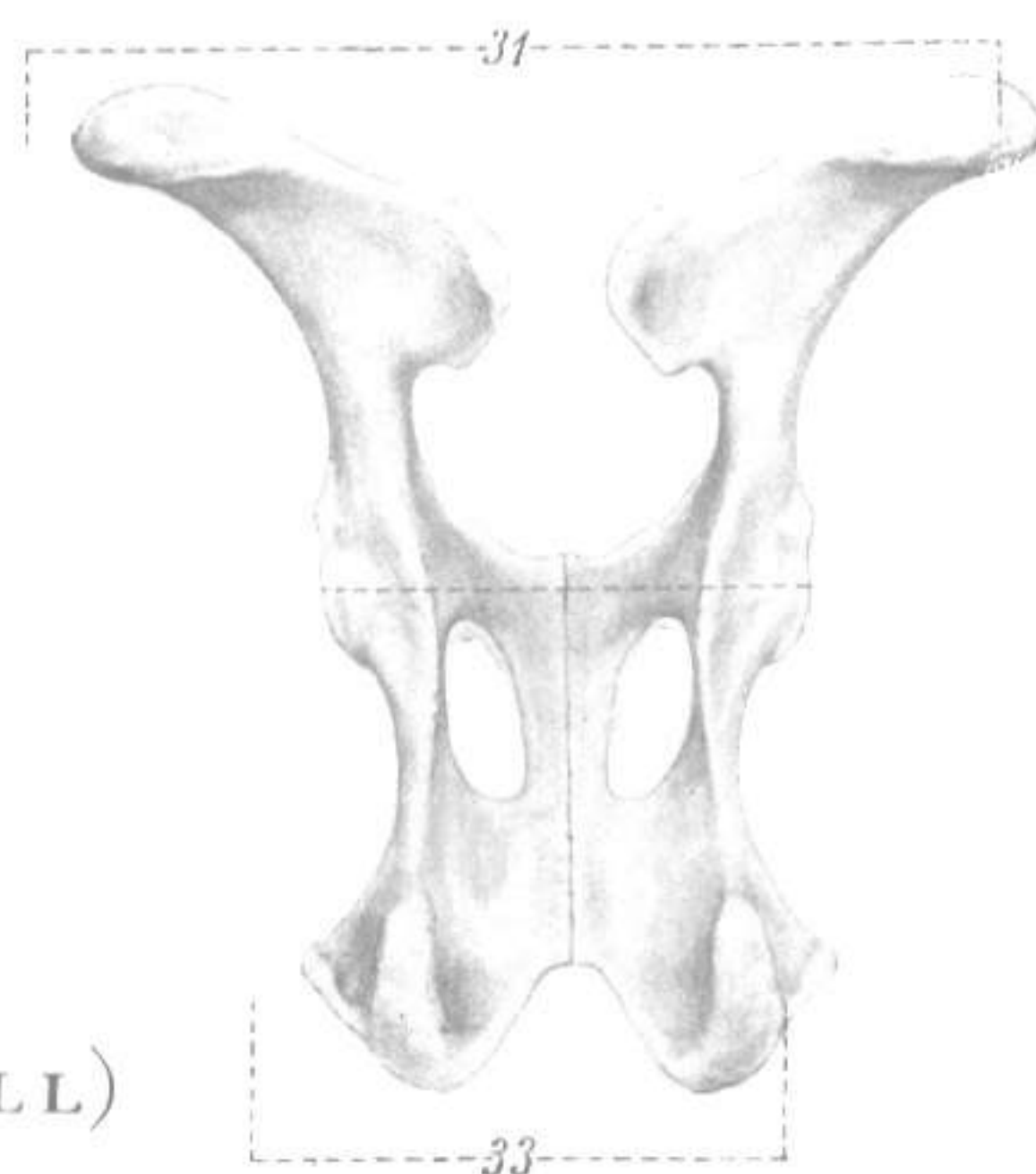

FIG. 62 (BULL)

THE COW AND BULL - PLATES 15 16

FIGURES 63 64 65 66 53 54

a—Hair whorl

b—Free end of the 6th thoracic vertebra

c, c'—Cross-sectioned 8th and 7th rib

d—Cross-sectional costal cartilage

e—Cross-sectional sternum

f—Cross-sectioned outer skin

g—Cross-sectioned muscles

h—Thyroid cartilage

i—Anterior resp. interior edge of auricle

i'—Posterior resp. exterior edge of auricle

k—Folds of skin on the inner surface of the auricle

l—Cartilagenous external auditory canal

m—Plane of the cross section of the body shown
in Fig. 64 on Plate 15

1, 2, 3, 4, 5, 6—Schematic diagram of the gait of
the cow (dark footprints represent the
feet bearing the weight at the moment)

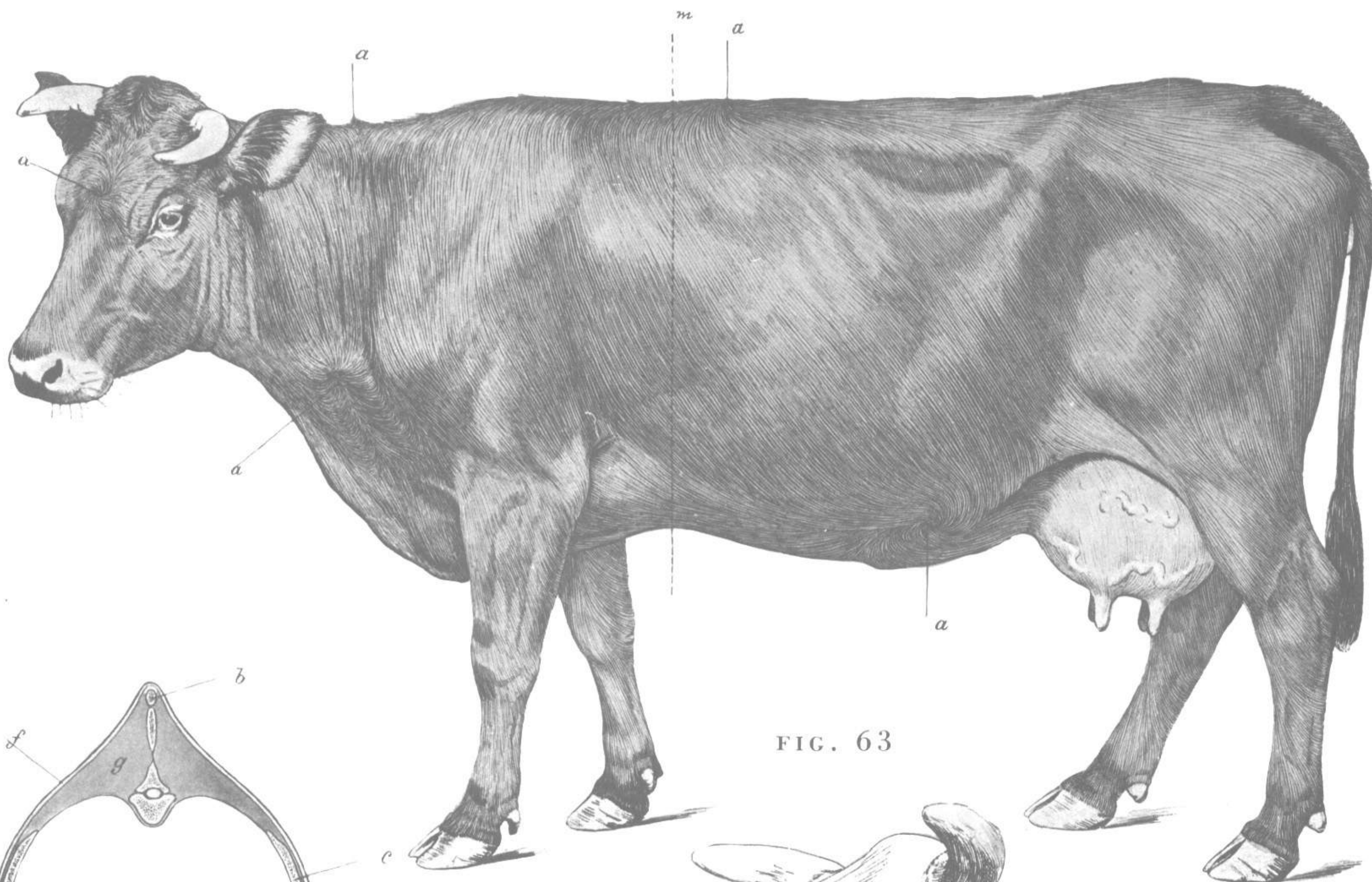


FIG. 63

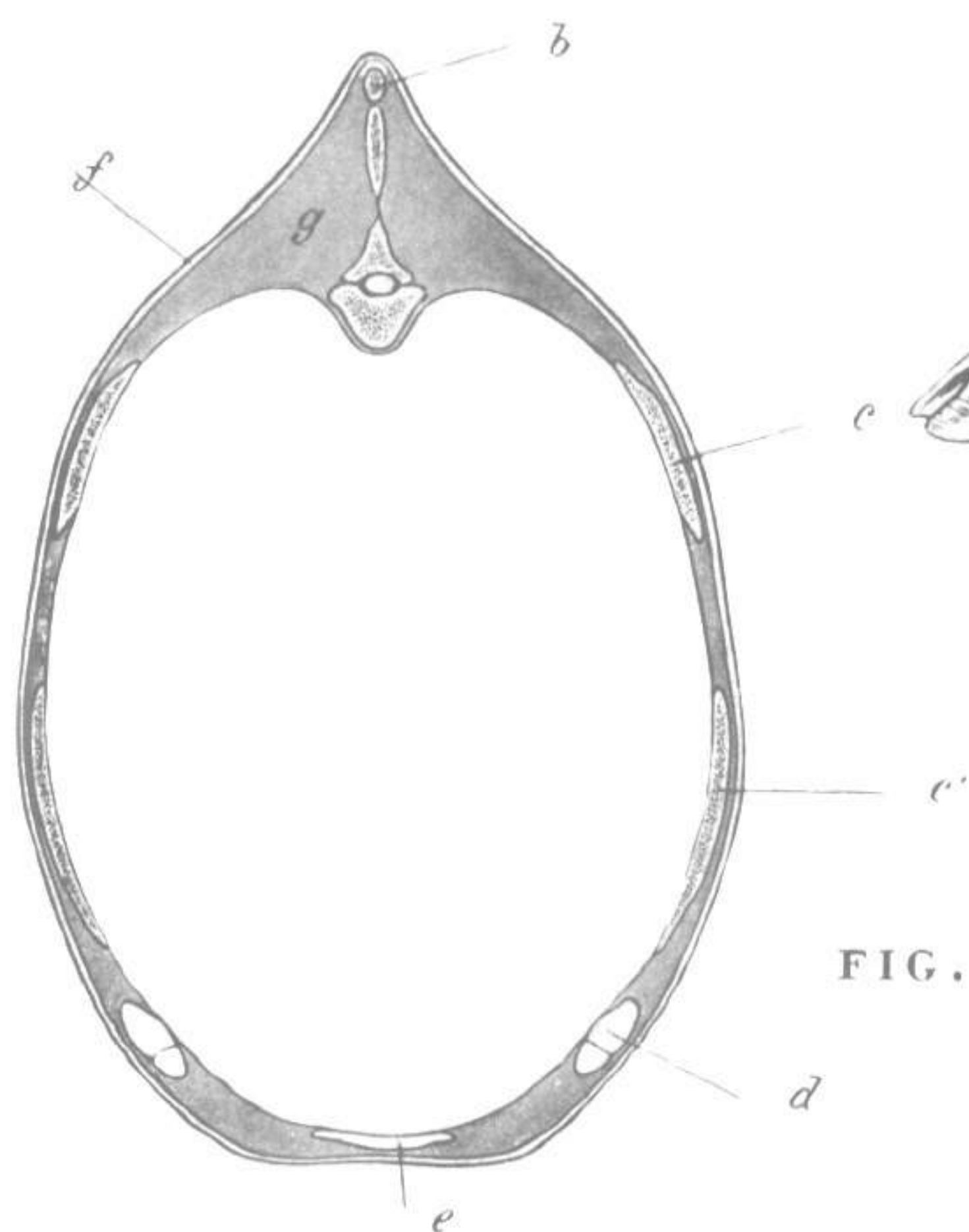


FIG. 64

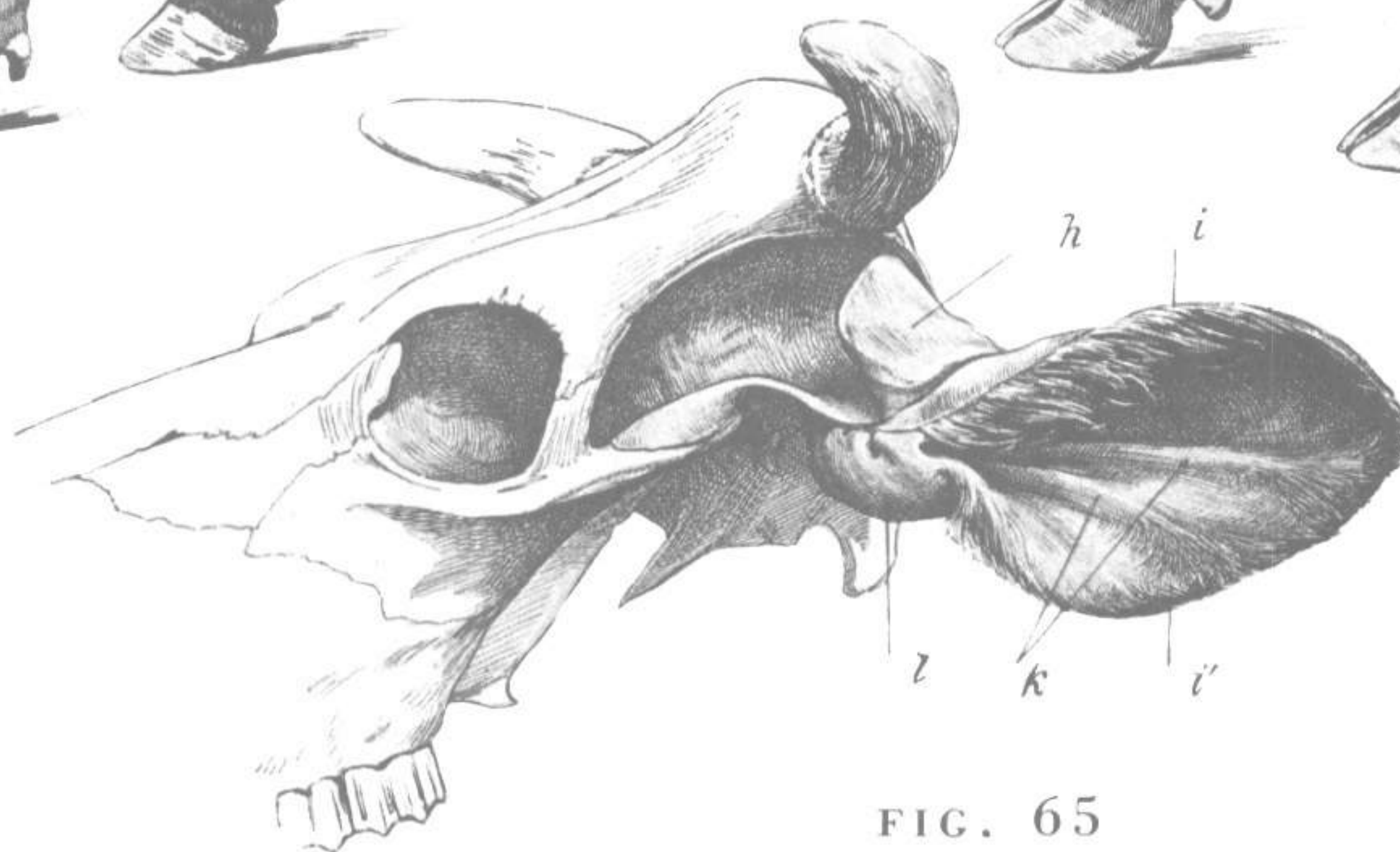


FIG. 65

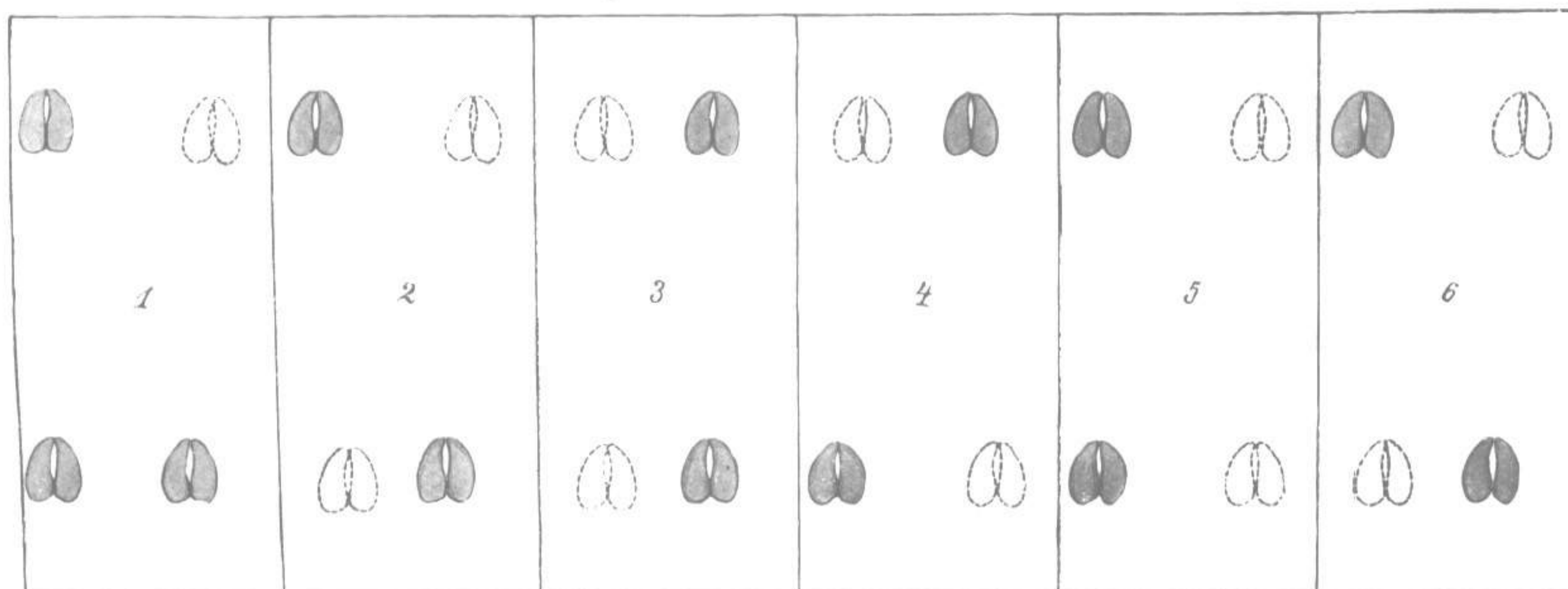


FIG. 66




FIG. 53 (BULL)




FIG. 54 (COW)

The Stag, Roe, Goat

THE STAG, ROE, GOAT - PLATES 1 2 3 4 5 6

FIGURES 1 2 3 4 5 6

- a, a'—*M. trapezius*
 b—Shoulder-transverse-process muscle
 c—*M. brachiocephalicus* (cephalic section)
 c'—*M. brachiocephalicus* (cervical section)
 c''—Lower portion of *M. brachiocephalicus*
 c'''—Tendinous band
 d, d'—*M. sternomandibularis*
 e—*M. deltoideus*
 e'—*M. deltoideus* at the aponeurosis
 f, f'—*M. triceps brachii*
 g, g'—*M. pectoralis major s. superficialis*
 h—Posterior part of *M. pectoralis minor s. profundus*
 i—End teeth of *M. serratus anterior*
 k—*M. latissimus dorsi*
 l—*M. obliquus abdominis externus*
 l'—Aponeurosis
 m—*M. serratus posterior*
 m'—Lumbo-dorsal fascia
 n—A small part of origin of *M. obliquus abdominis internus*
 o, o''—*M. tensor fasciae latae*
 o'—Broad thigh portion of the *M. tensor fasciae latae*
 p—*M. glutaeus medius*
 q, q'—*M. biceps femoris*
 r—*M. semitendinosus*
 s—Edge portion of *M. semimembranosus*
 t—Edge portion of *M. sternothyroideus*
 u—*M. omohyoideus*
 v—*M. sternohyoideus*
 w—A part of *M. scalenus*
 x—Muscle slip from brachiocephalus to pectoralis major
 y—Edge portion of *M. tensor fasciae antebrachii*
 z—*M. tensor fasciae antebrachii*
 z'—Cervical subcutaneous muscle
 1H—1st cervical vertebra (*Atlas*)
 7H—7th cervical vertebra
 K—Sacrum
 6K—Costal cartilage
 1L—1st lumbar vertebra
 6L—6th lumbar vertebra
 7L—7th lumbar vertebra
 1R—1st thoracic (dorsal) vertebra
 6R—6th rib
 12R—12th thoracic (dorsal) vertebra
 13R—13th rib
 S—Caudal vertebra
 *—Ala of *Atlas*
 1—Scapula
 1'—Border of scapular cartilage
 2—Spina scapulae
 3—Acromion
 4—Humerus
 4'—External epicondyle
 5—External tuberosity
 6—Rotator of humerus
 7—Ulna
 8—Olecranon
 9—Radius
 10—Carpus
 11—*Os pisiforme*
 12, 12'—Metacarpus
 13—Phalanx prima
 13'—Phalanx secunda
 13''—Phalanx tertia
 14—Sternum
 14'—Manubrium sterni
 14''—Cartilago xiphoidae
 15—Ossa pelvis
 16—Tuber coxae
 16'—Tuber sacrale
 17—Tuber ischidicum
 18—*Os femoris*
 19—Trochanter major
 20—Patella
 21—Tibia
 21'—External epicondyle of tibia
 21''—Swelling of tibia
 22—Tarsus
 23—*Os malleolare*
 24—Tuber calcanei
 25, 25'—Metatarsus
 26—Phalanx prima
 26'—Phalanx secunda
 26''—Phalanx tertia
 27—Free border of pelvic ligament
 28—End of *M. brachialis internus*
 29—*M. extensor carpi radialis*

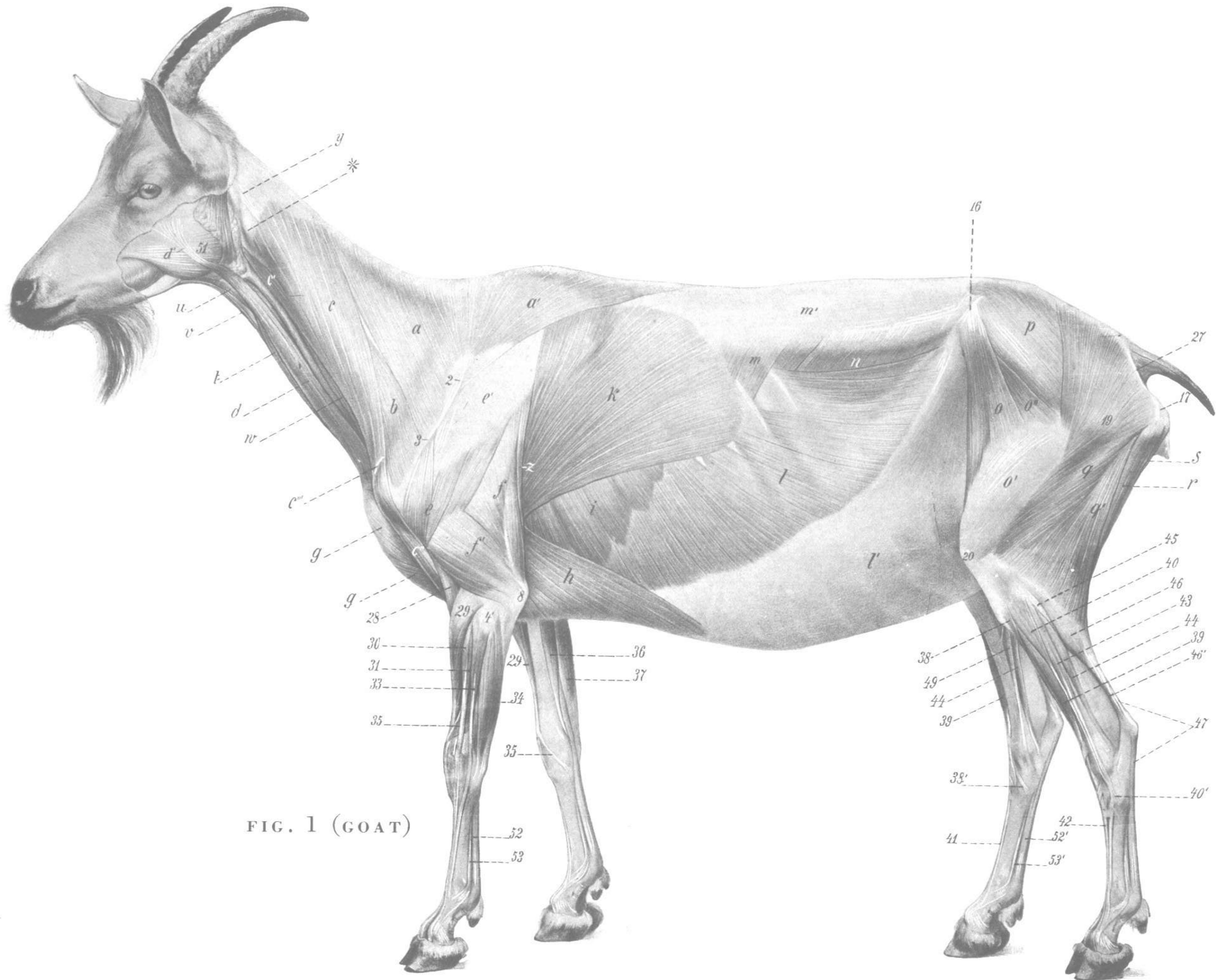


FIG. 1 (GOAT)

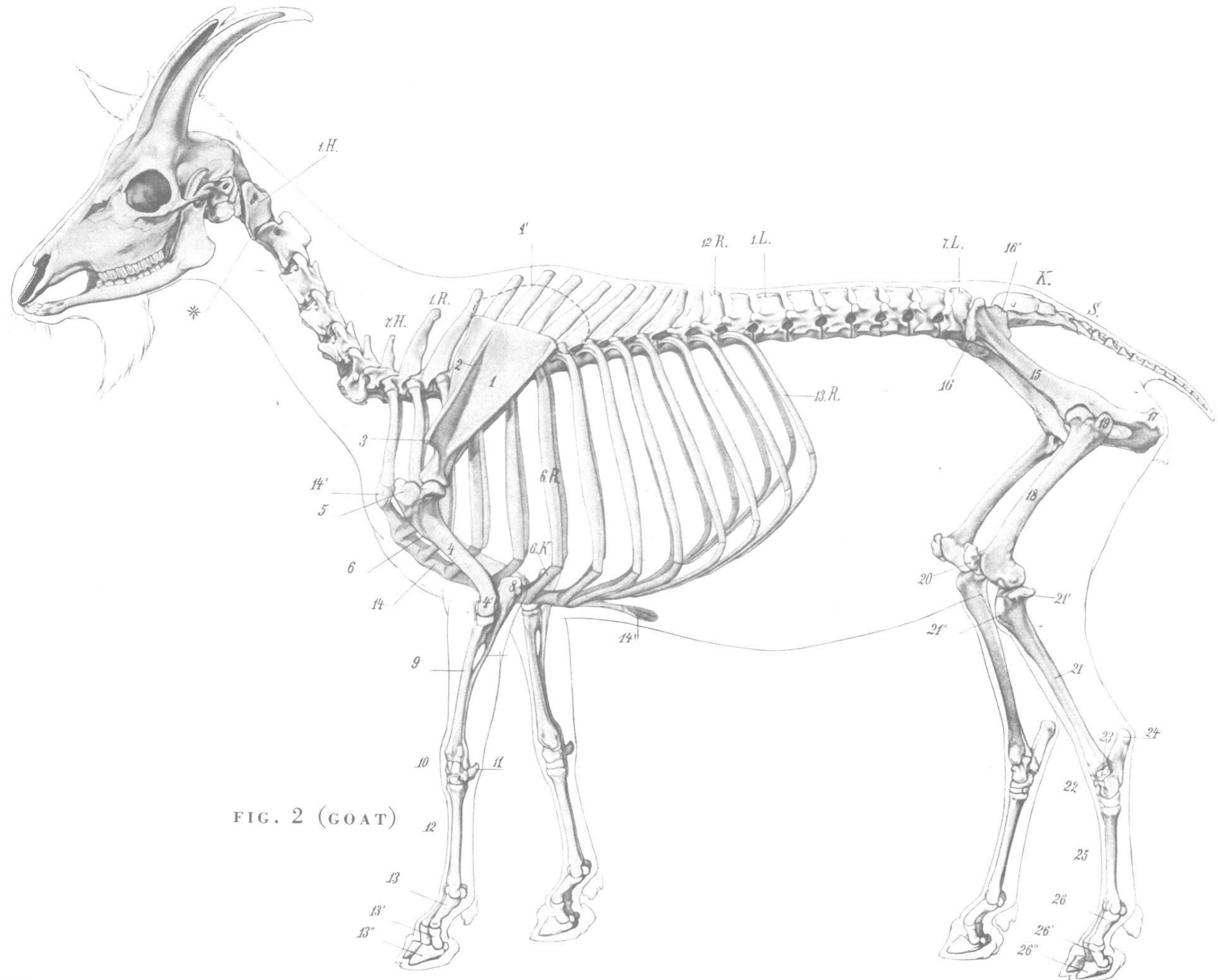


FIG. 2 (GOAT)

THE STAG, ROE, GOAT PLATE 3

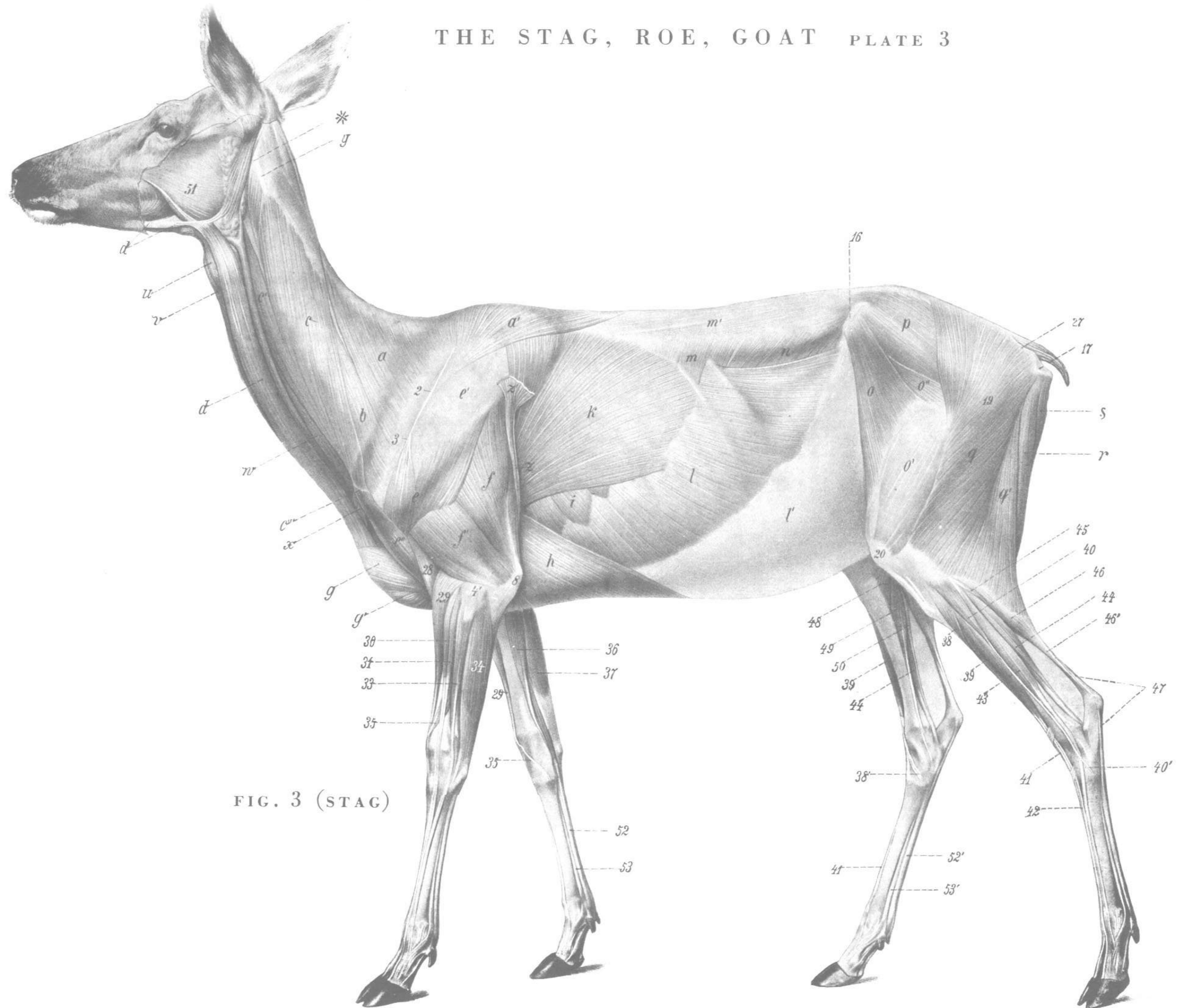


FIG. 3 (STAG)

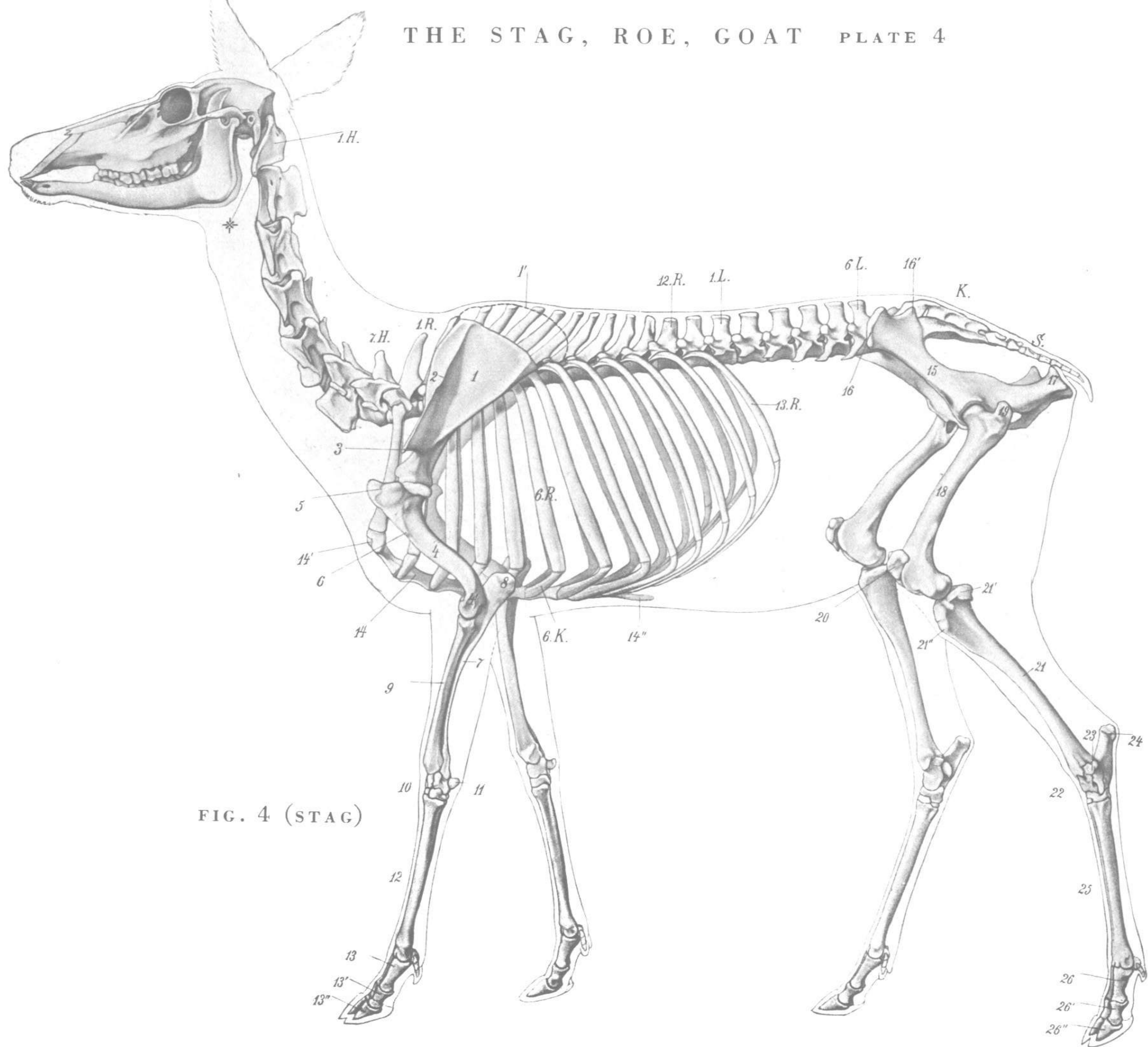
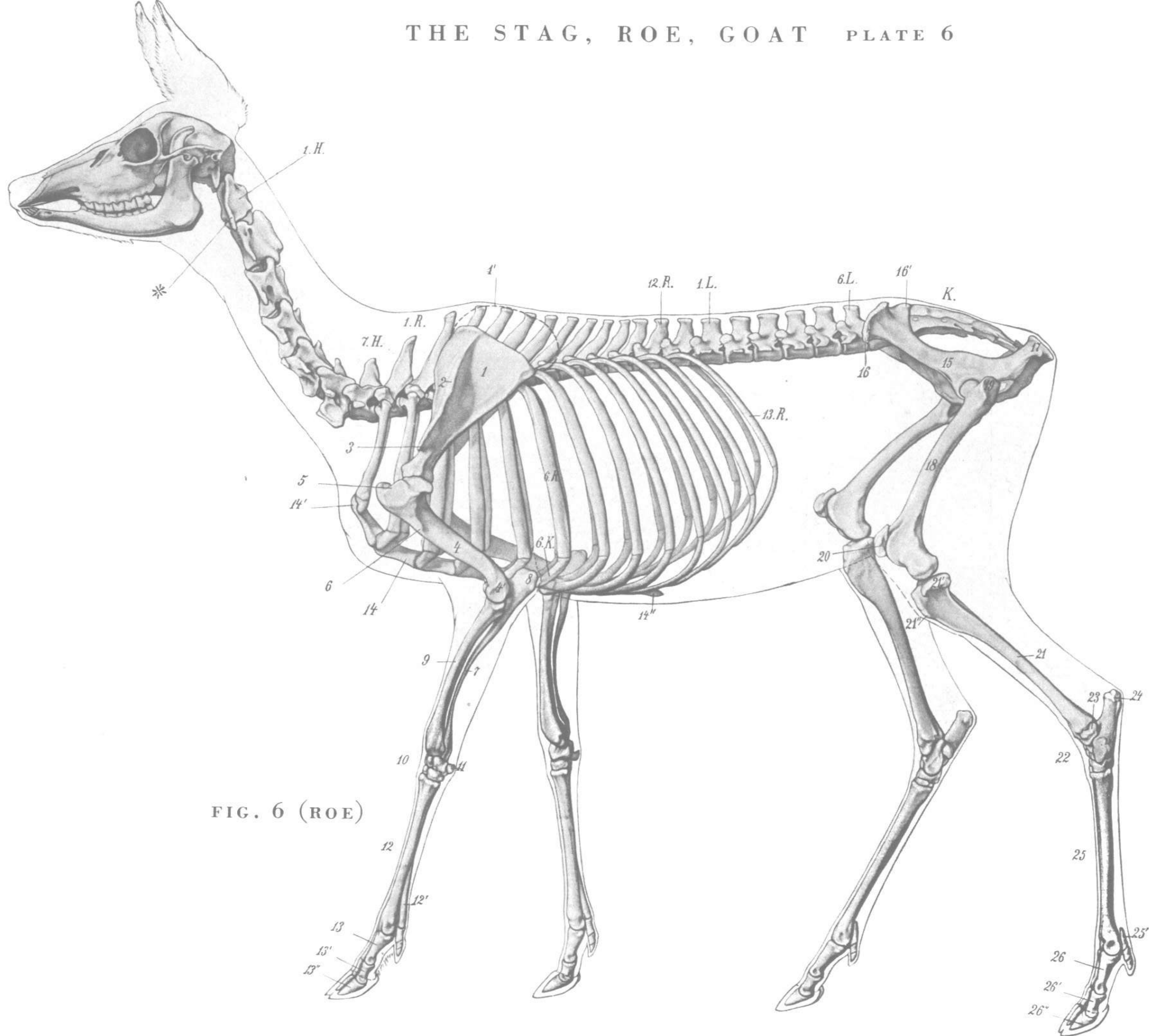


FIG. 4 (STAG)

THE STAG, ROE, GOAT PLATE 5

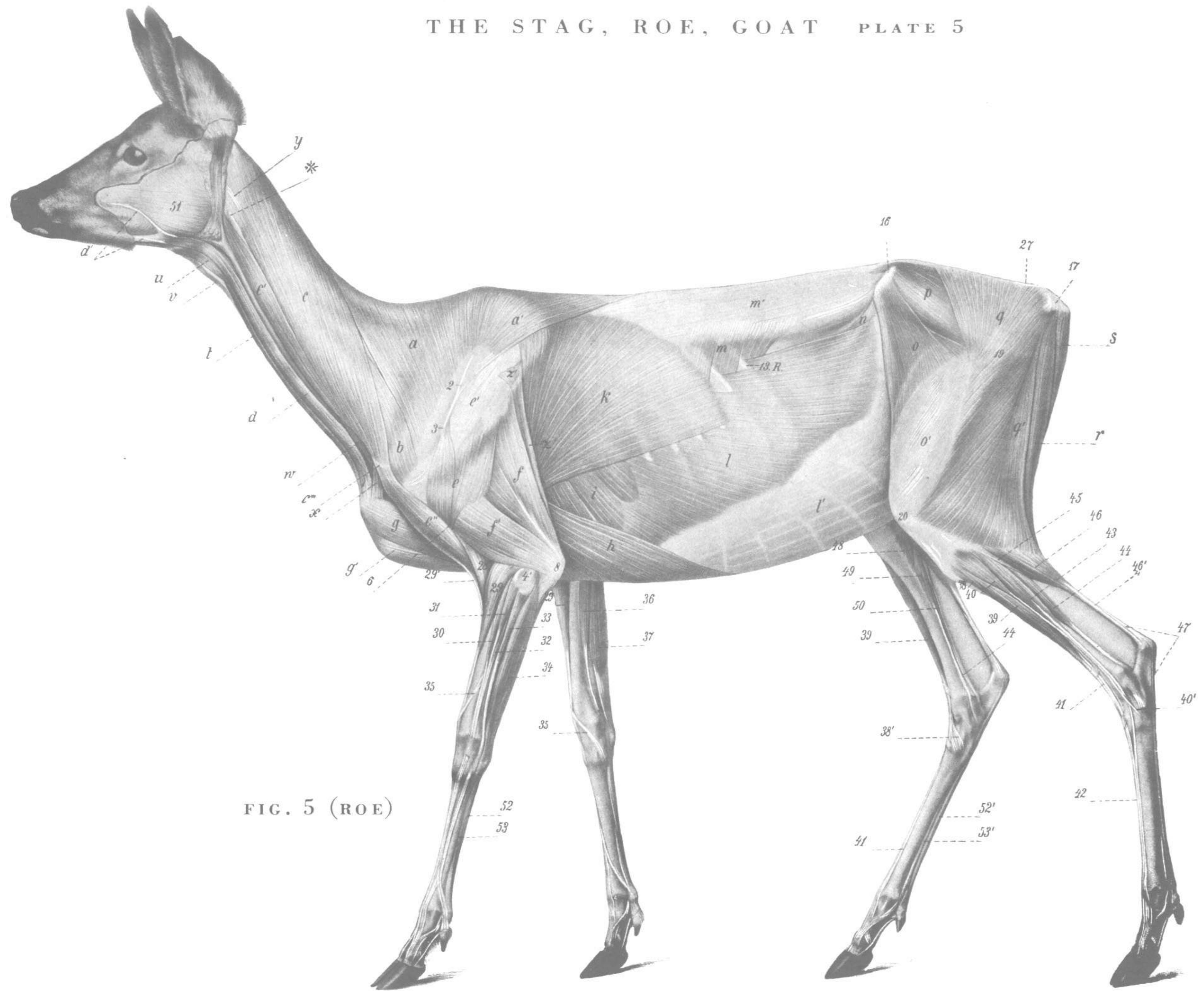

FIG. 5 (ROE)



THE STAG, ROE, GOAT - PLATES 7 8

FIGURES 7 8 9 10 11 12 13 14 15 16 17

- a—*M. levator labii superioris proprius*
 b—*M. levator nasolabialis*
 d, d''—*M. sternomandibularis*
 e—End portion of *M. sternohyoideus*
 f—*M. caninus s. pyramidalis nasi*
 g—*M. zygomaticus*
 g'—*M. malaris*
 h—*M. buccinator*
 i—*M. depressor s. quadratus labii inferioris*
 m—*M. masseter*
 n—Depressor of the auricle
 o'—Inferior adductor of the auricle
 o''—Superior adductor of the auricle
 p, p'—*M. scutularis*
 q—Long abductor of the auricle
 w—*M. mylohoideus*
 y—Tendon of *M. longissimus capitis*
 z—*M. orbicularis oculi*
 z'—*M. corrugator supercilii*
 *—Ala of atlas
 1—Auricula
 2—External resp. posterior edge of auricle
 3—Internal resp. anterior edge of auricle
 8—Scutellum
 9—Arcus zygomaticus
 11—Processus coronoideus of the lower jawbone
 12—Orbital arch
 13, 13', 13'', 13'''—Os occipitale
 14—Os parietale
 15—Os frontale
 15'—Base of antlers
 15''—Horny process of goat
 16—Os temporale
 17—Meatus acusticus externus
 18—Temporo-maxillary articulation
 19—Orbita
 20—Os zygomaticus
 21, 21', 21''—Os lacrimale
 22—Os nasale
 23—Os incisivum
 24'—Lower incisor teeth
 25—Upper canine tooth of the stag
 26—Maxilla
 27—Facial crest
 28—Canine tooth (unpaired) part of the lower jawbone
 28'—Molar tooth (paired) part of the lower jawbone
 30—Branch of the lower jaw
 30'—Mandibular condyle
 31—Condyle process of the lower jaw
 38—End of the jugular vein
 39—*V. facialis*
 44—Glandula parotis
 50—Lower end of glandula submaxillaris
 51—Lower end of metatarsal bone
 52—Phalanx prima
 53—Phalanx secunda
 54—Phalanx tertia
 55—Lower sesamoid bone
 56—An upper sesamoid bone
 57—1st toe joint
 58—2nd toe joint
 59—3rd toe joint
 60—Extensor tendon
 61—*M. interosseus*
 62—Superficial flexor tendon
 63—Deep flexor tendon
 64—Outer skin
 65, 65'—Horny wall of the claw
 66—Plantar surfaces of the claws
 67—Hind claws

- 29'—*Tendon of brachiocephalicus*
 30—*M. extensor digiti tertii proprius*
 31—*M. extensor digitorum communis*
 32—*A thin muscle only existing with the roe*
 33—*M. extensor digiti quarti proprius*
 34—*M. extensor carpi ulnaris*
 35—*M. abductor pollicis longus*
 36—*M. flexor carpi radialis*
 37—*M. flexor carpi ulnaris*
 38—*M. tibialis anterior*
 38'—*Tendon of M. tibialis anterior*
 39—*M. extensor digitorum pedis longus*
 40, 40'—*M. peronaeus longus*
 41—*Tendon*
 42—*Tendon*
 43—*M. extensor digiti quarti pedis proprius*
 44—*M. flexor digitorum profundus*
 45—*M. soleus*
 46—*Mm. gastrocnemii*
 46'—*Tendo Achillis*
 47—*Superficial flexor tendon*
 48—*M. popliteus*
 49—*M. flexor digitorum pedis longus*
 50—*M. tibialis posterior*
 51—*M. masseter*
 52—*Superficial and deep flexor tendon of anterior metatarsus*
 52'—*Superficial and deep flexor tendon of metatarsus*
 53—*M. interosseus of anterior metatarsus*
 53'—*M. interosseus of posterior metatarsus*

THE STAG, ROE, GOAT PLATE 7

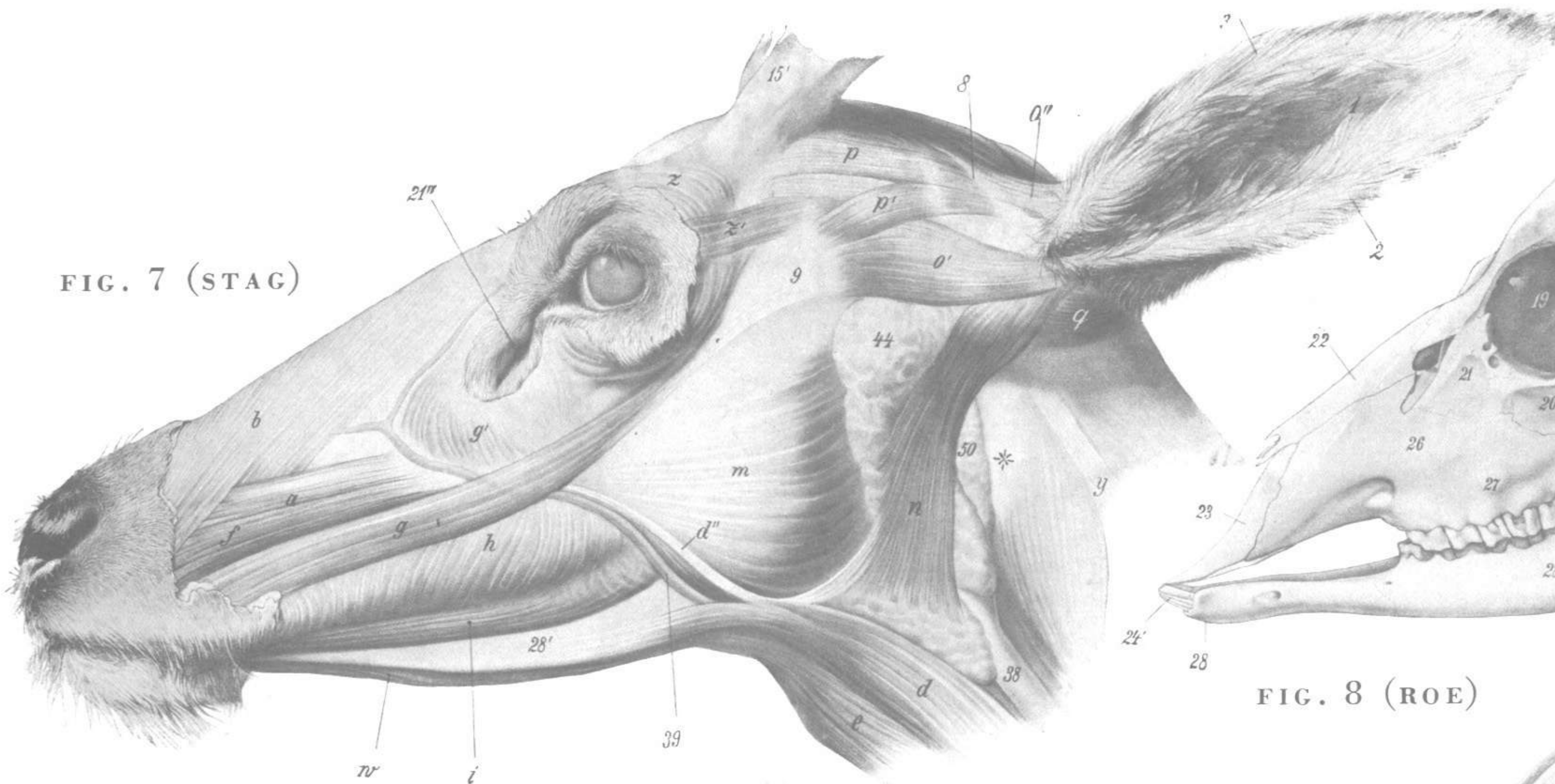


FIG. 7 (STAG)

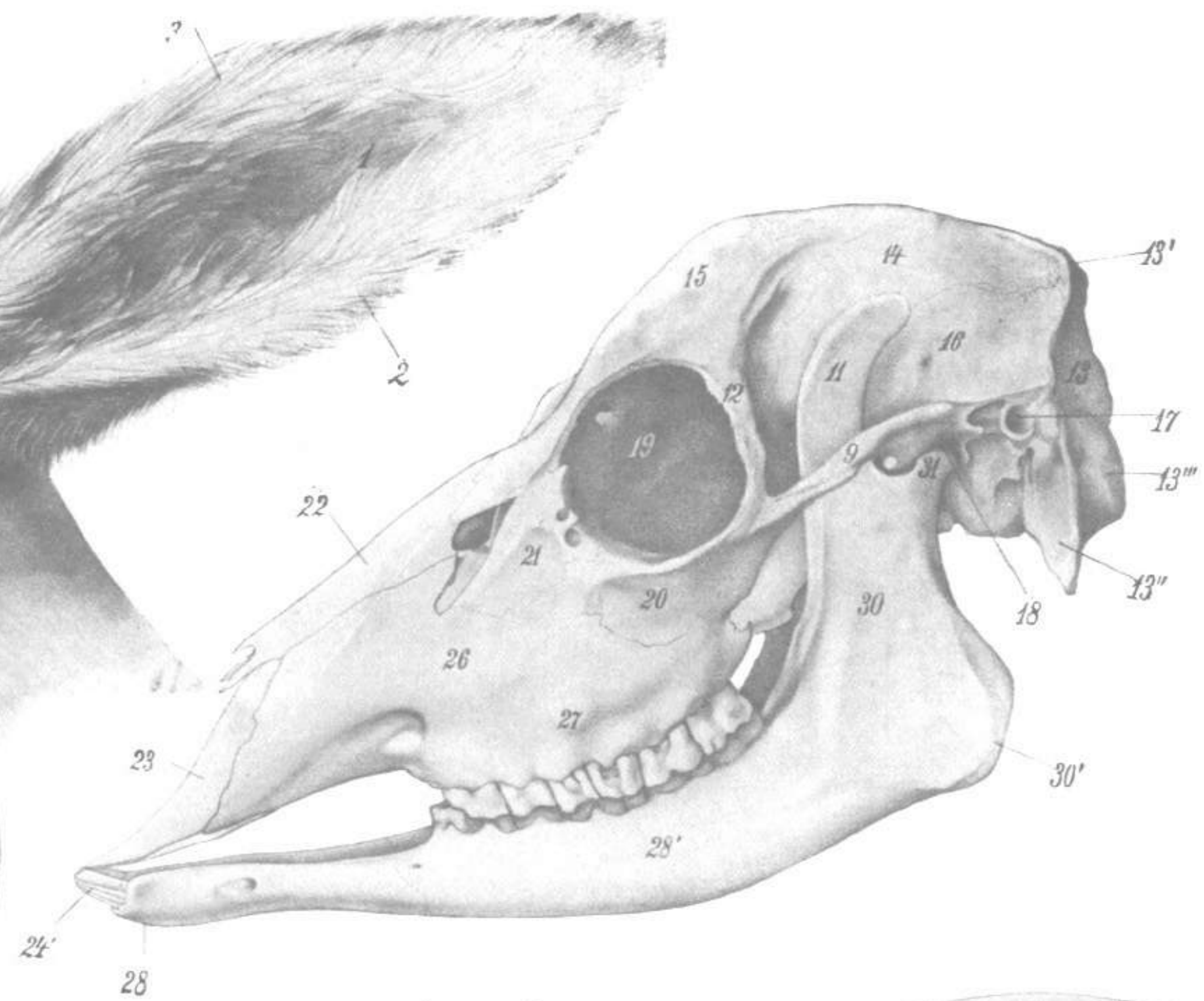


FIG. 8 (ROE)

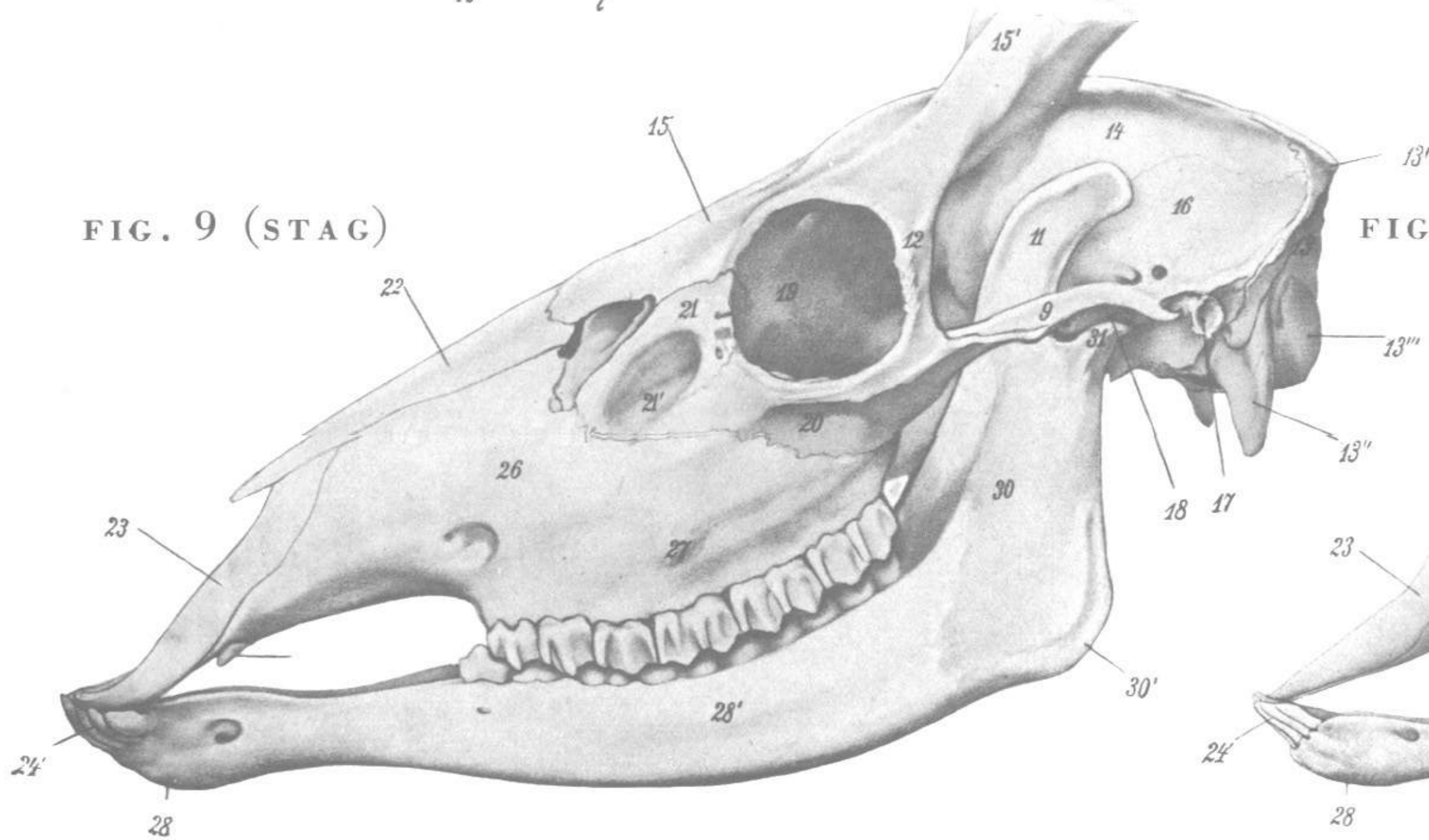


FIG. 9 (STAG)

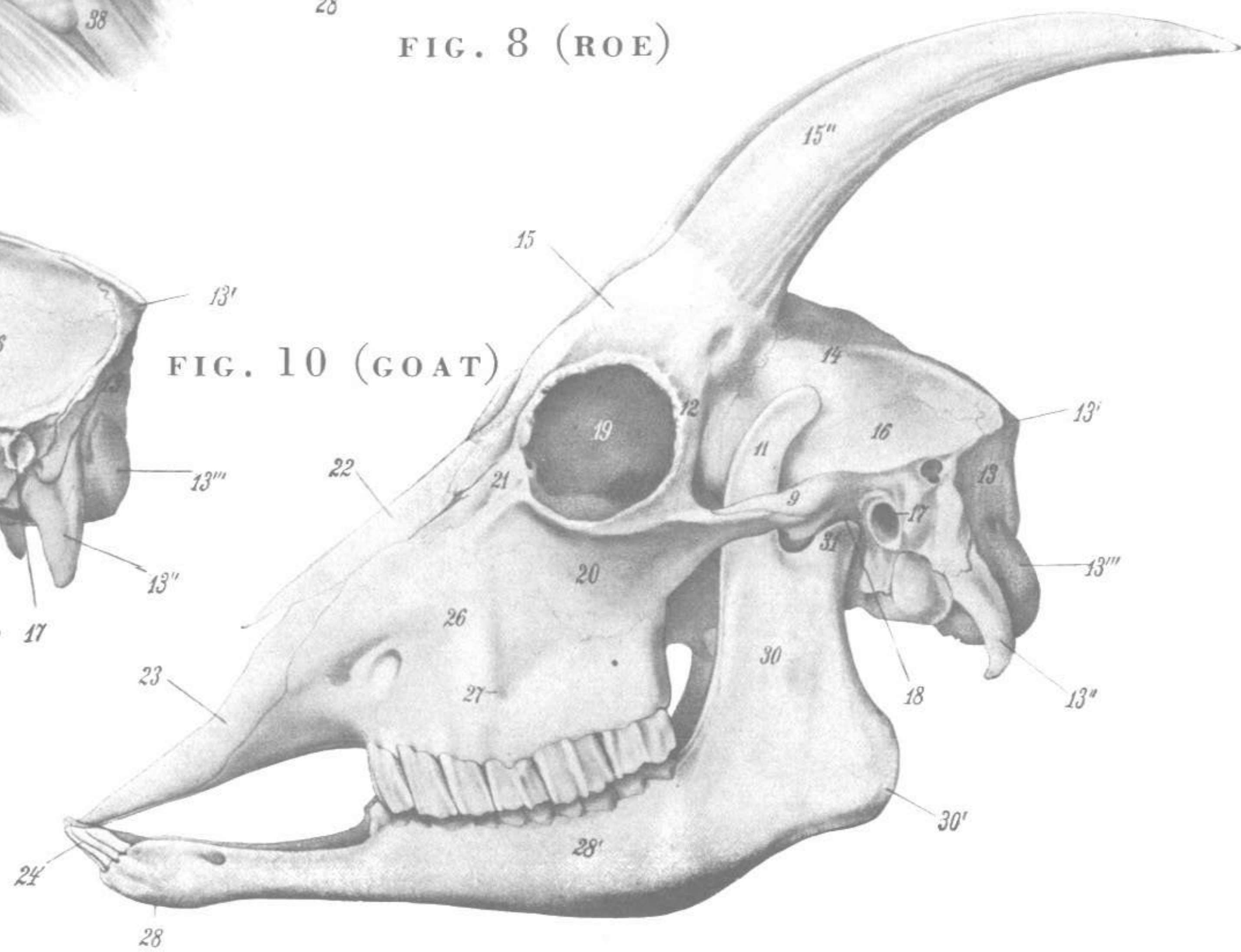


FIG. 10 (GOAT)

FIG. 11 (STAG)

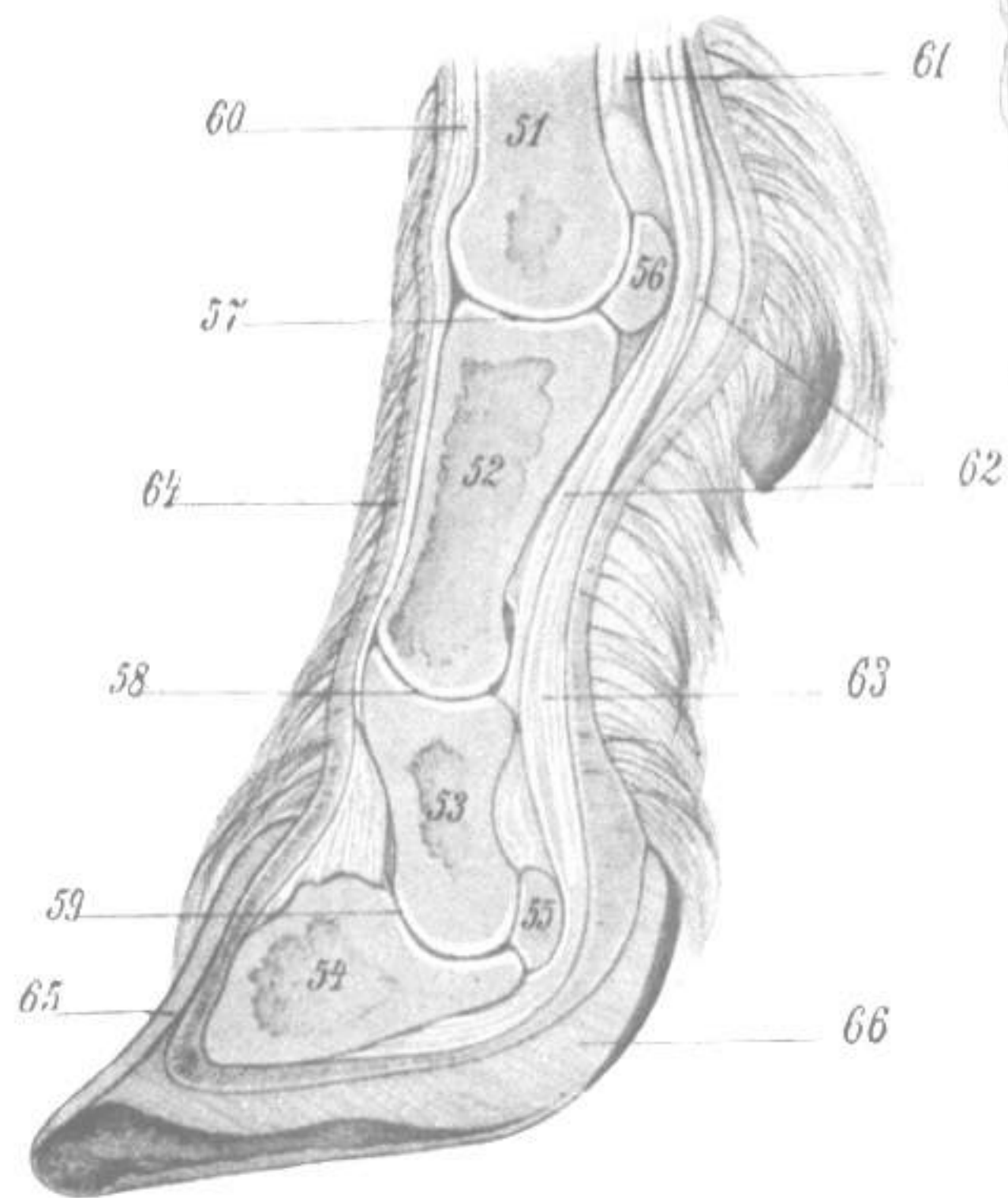
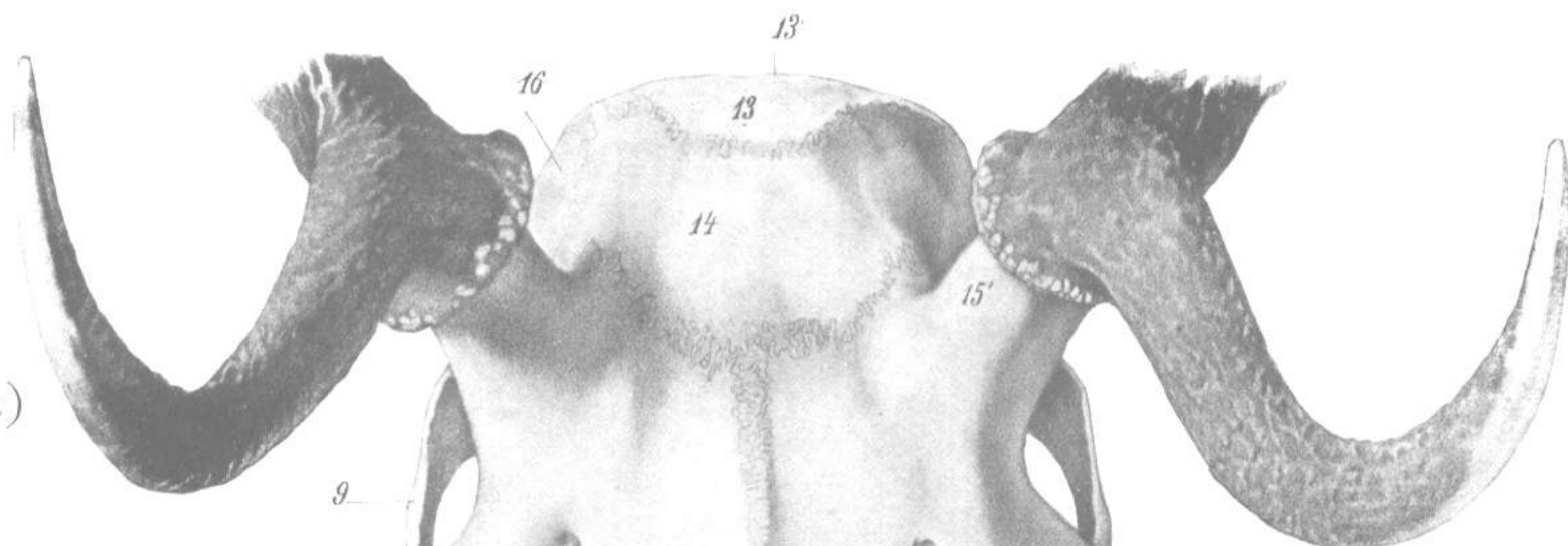


FIG. 12 (GOAT)

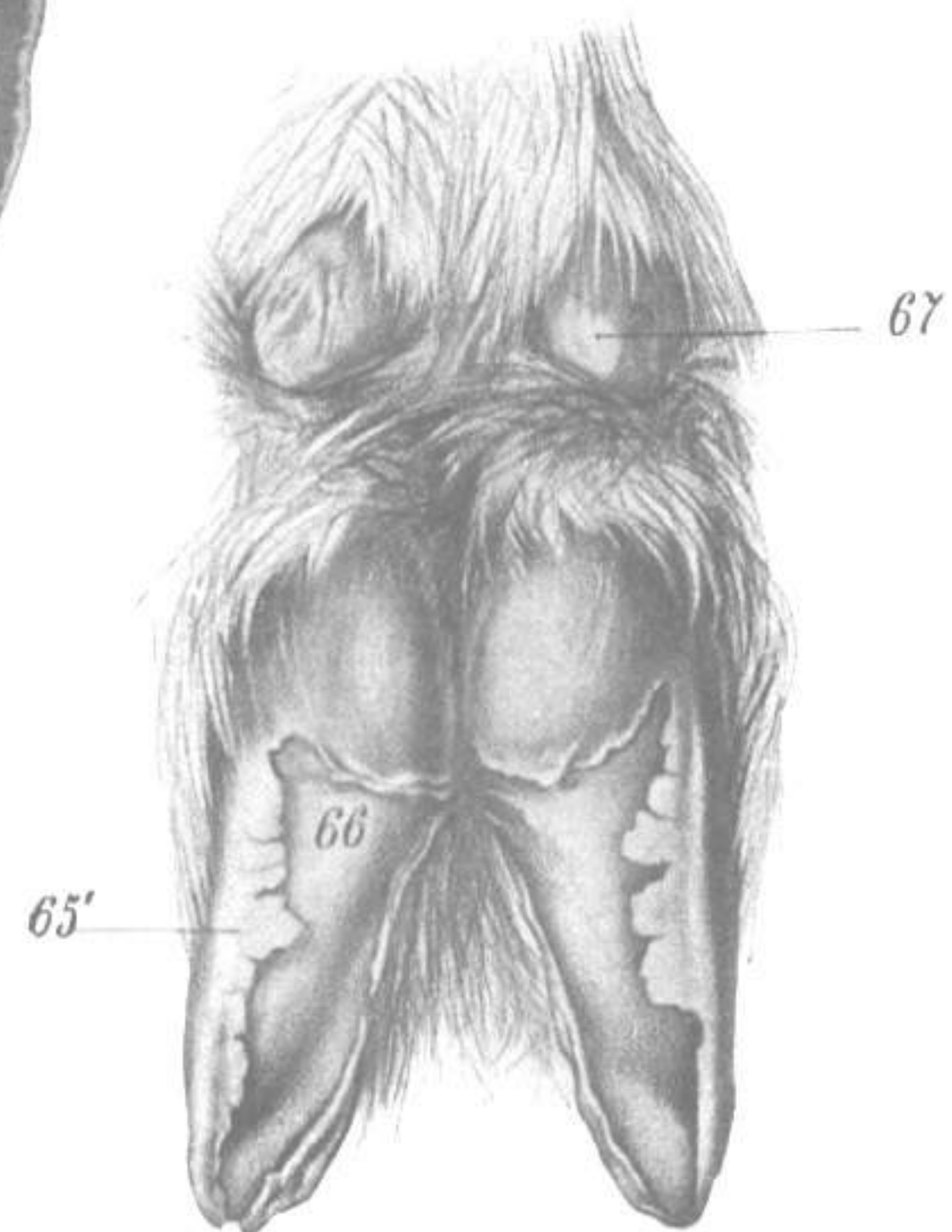


FIG. 13 (GOAT)

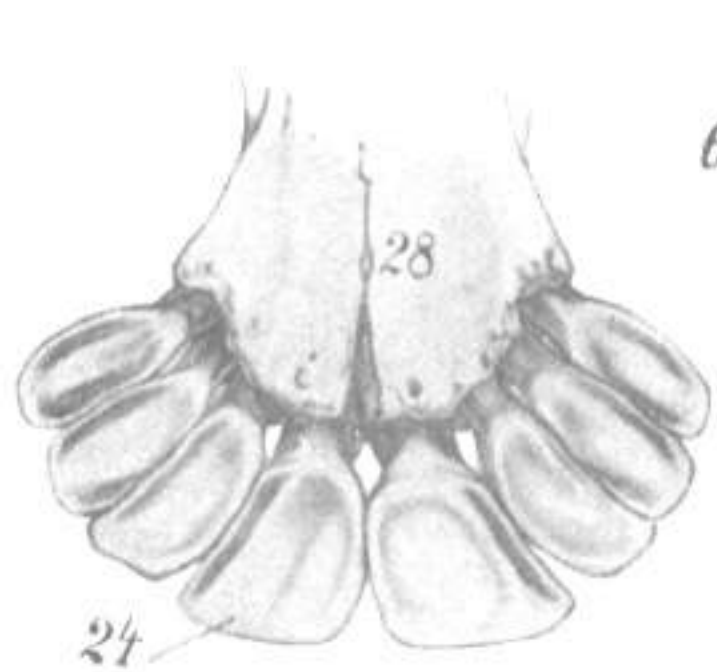


FIG. 14 (STAG)

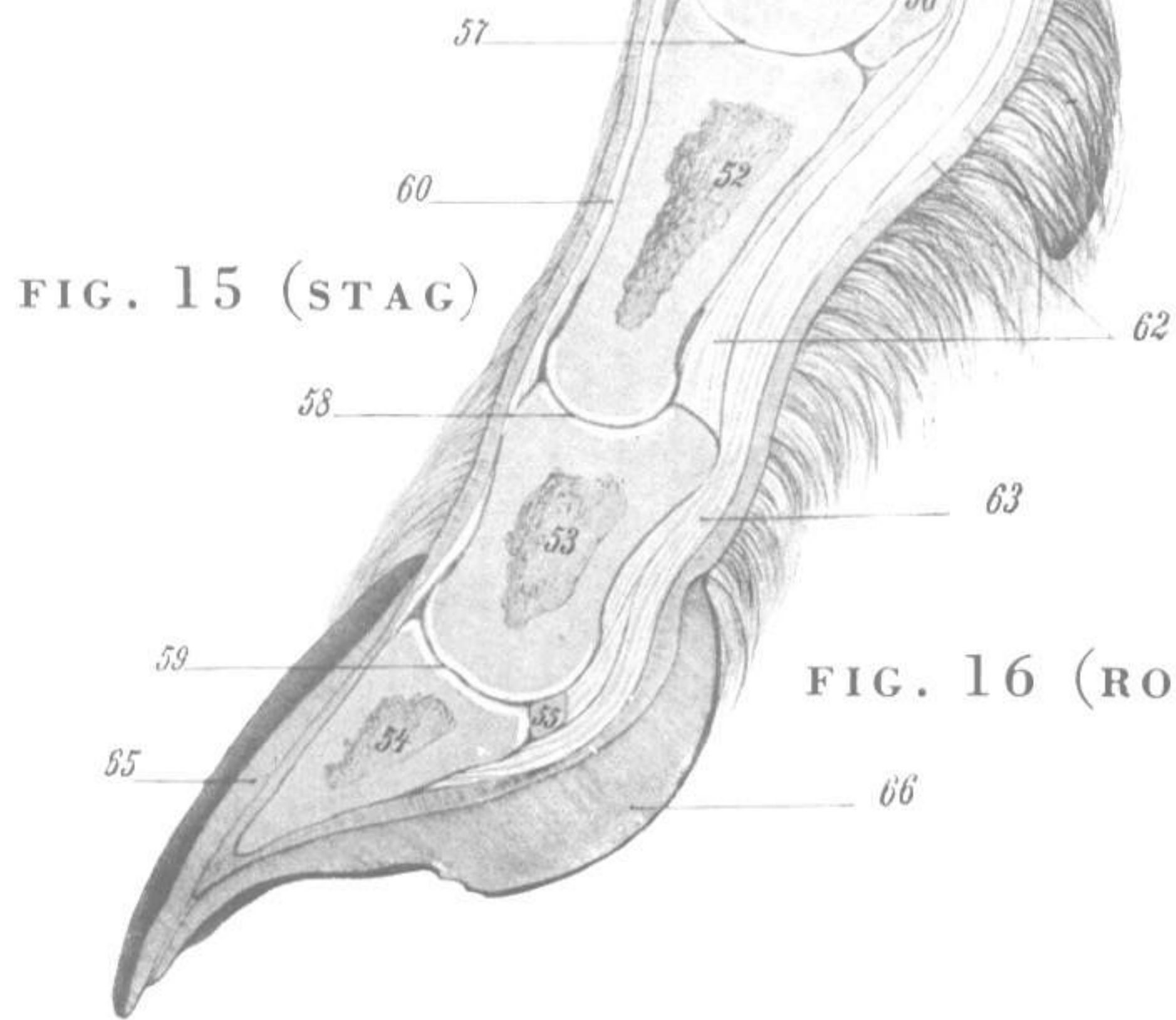
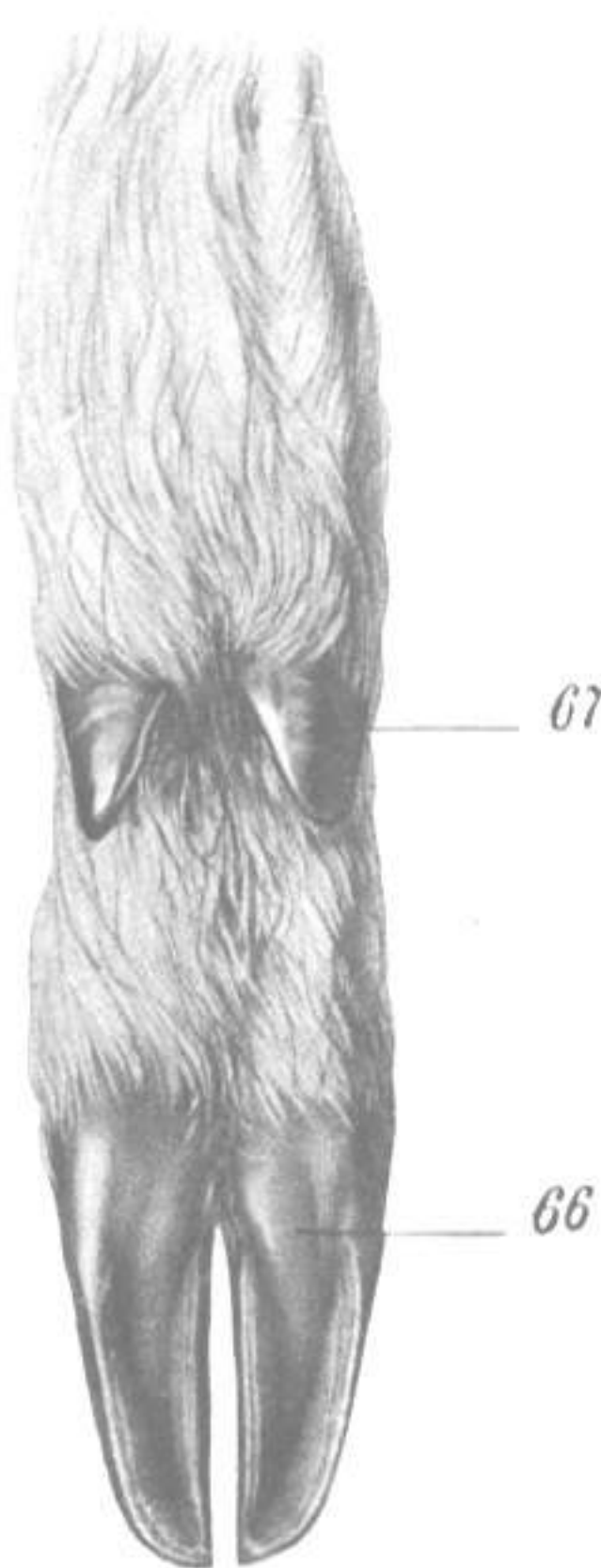

FIG. 15 (STAG)

FIG. 16 (ROE)

FIG. 17 (STAG)

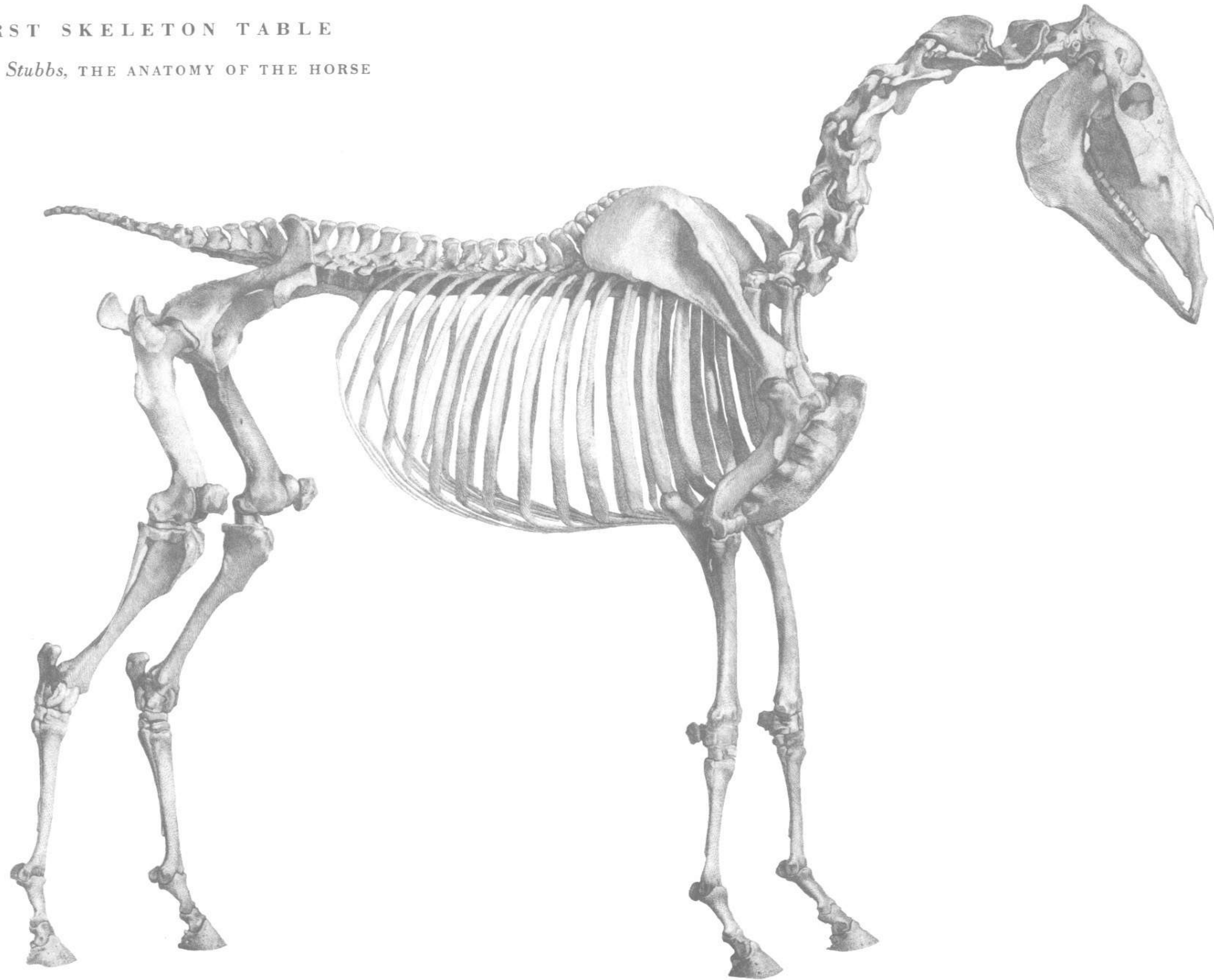


Appendix

THE HORSE (STUBBS—PLATE 1)

FIRST SKELETON TABLE

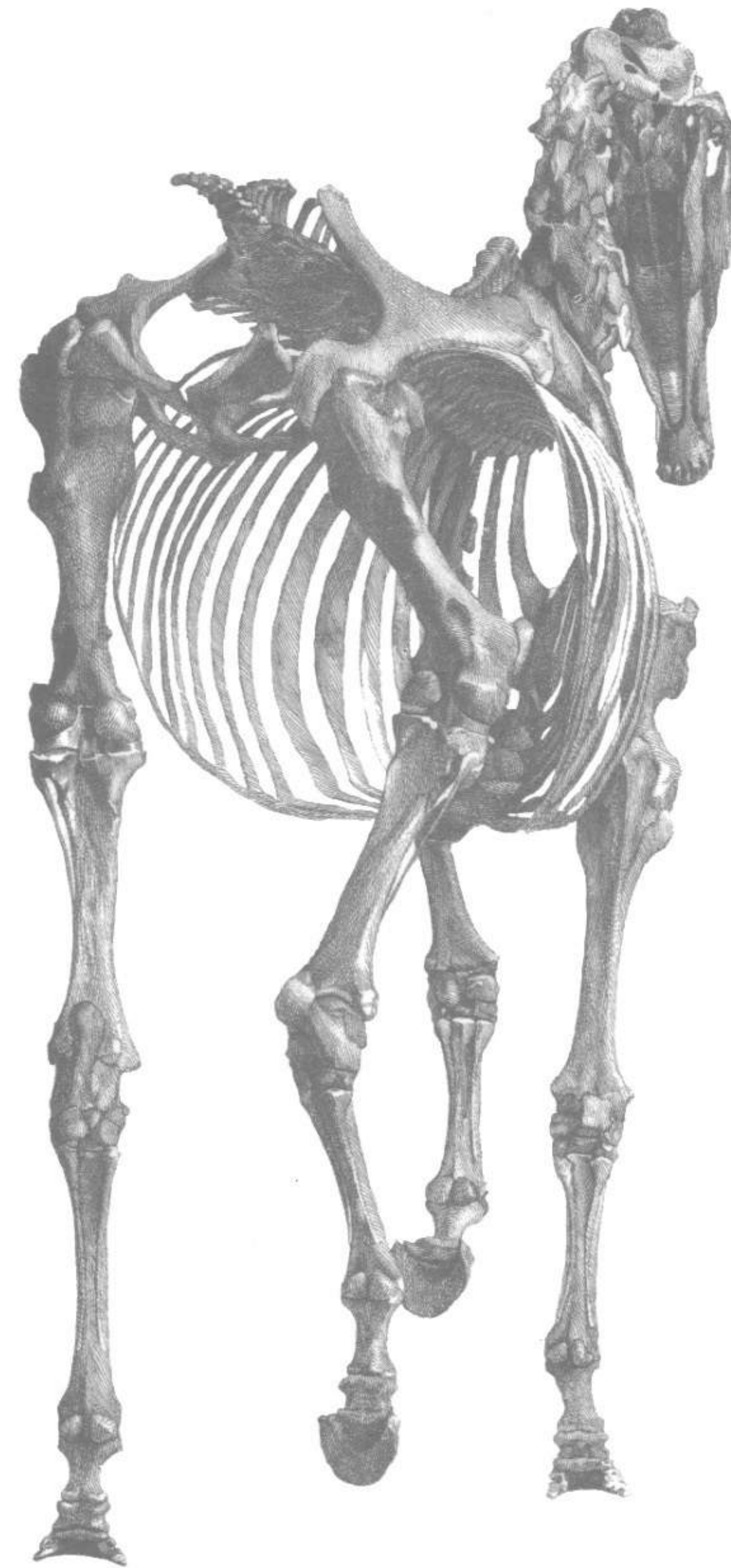
from Stubbs, THE ANATOMY OF THE HORSE



THE HORSE (STUBBS—PLATE 2)

SECOND AND THIRD SKELETON TABLES


from Stubbs, THE ANATOMY OF THE HORSE



THE HORSE (STUBBS—PLATE 3)

FIRST ANATOMICAL TABLE

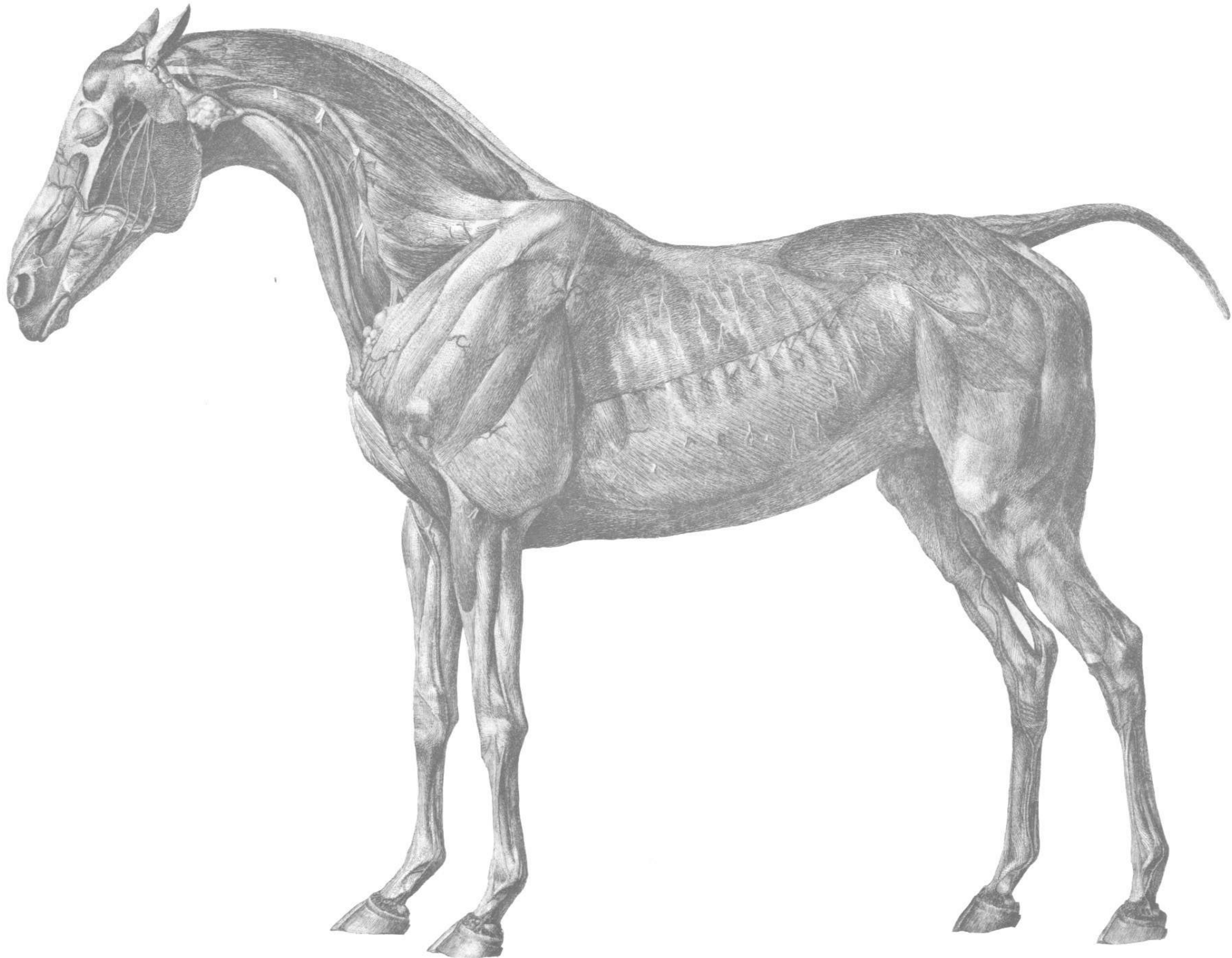
from Stubbs, THE ANATOMY OF THE HORSE



THE HORSE (STUBBS—PLATE 4)

SECOND ANATOMICAL TABLE

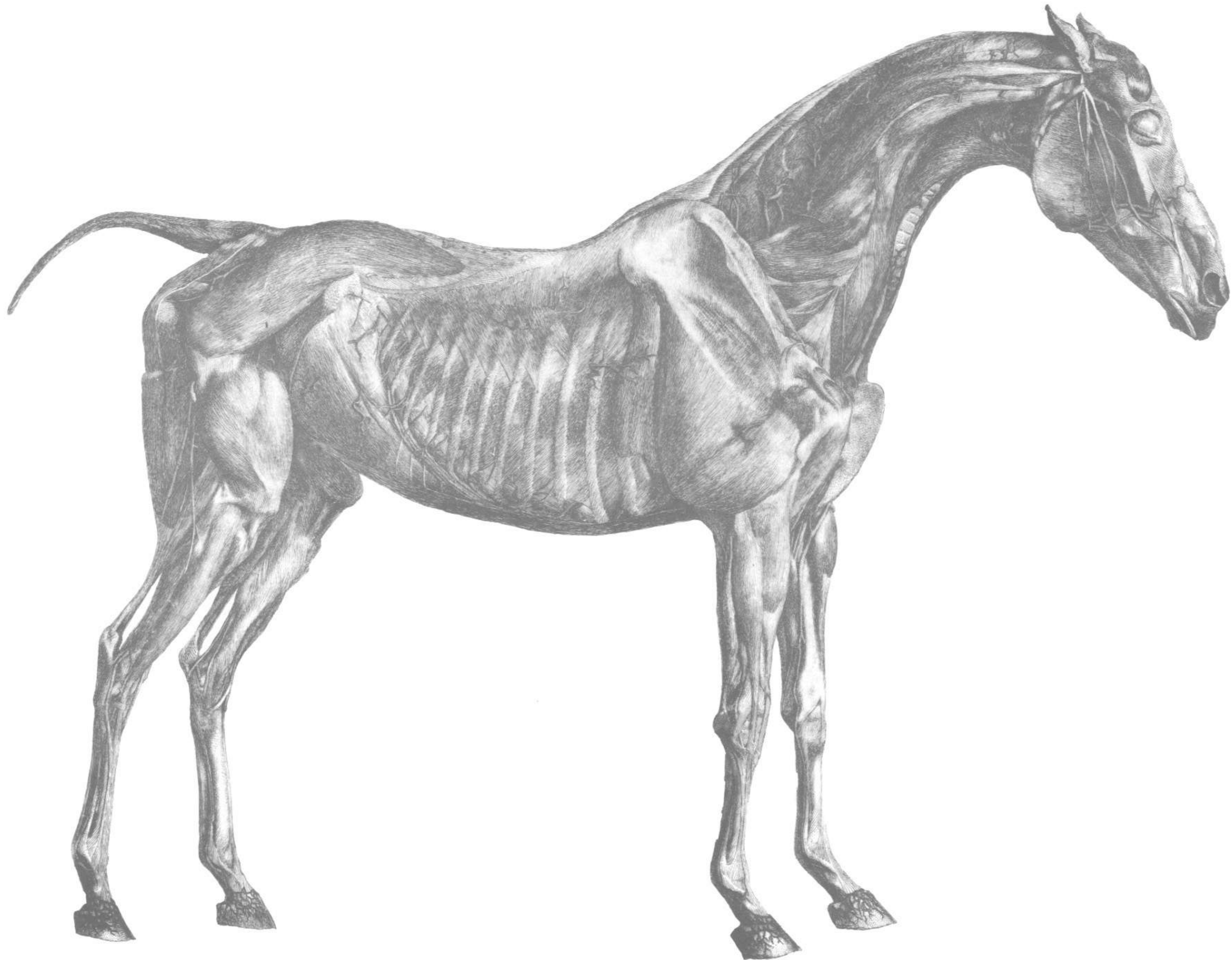
from Stubbs, THE ANATOMY OF THE HORSE



THE HORSE (STUBBS—PLATE 5)

THIRD ANATOMICAL TABLE

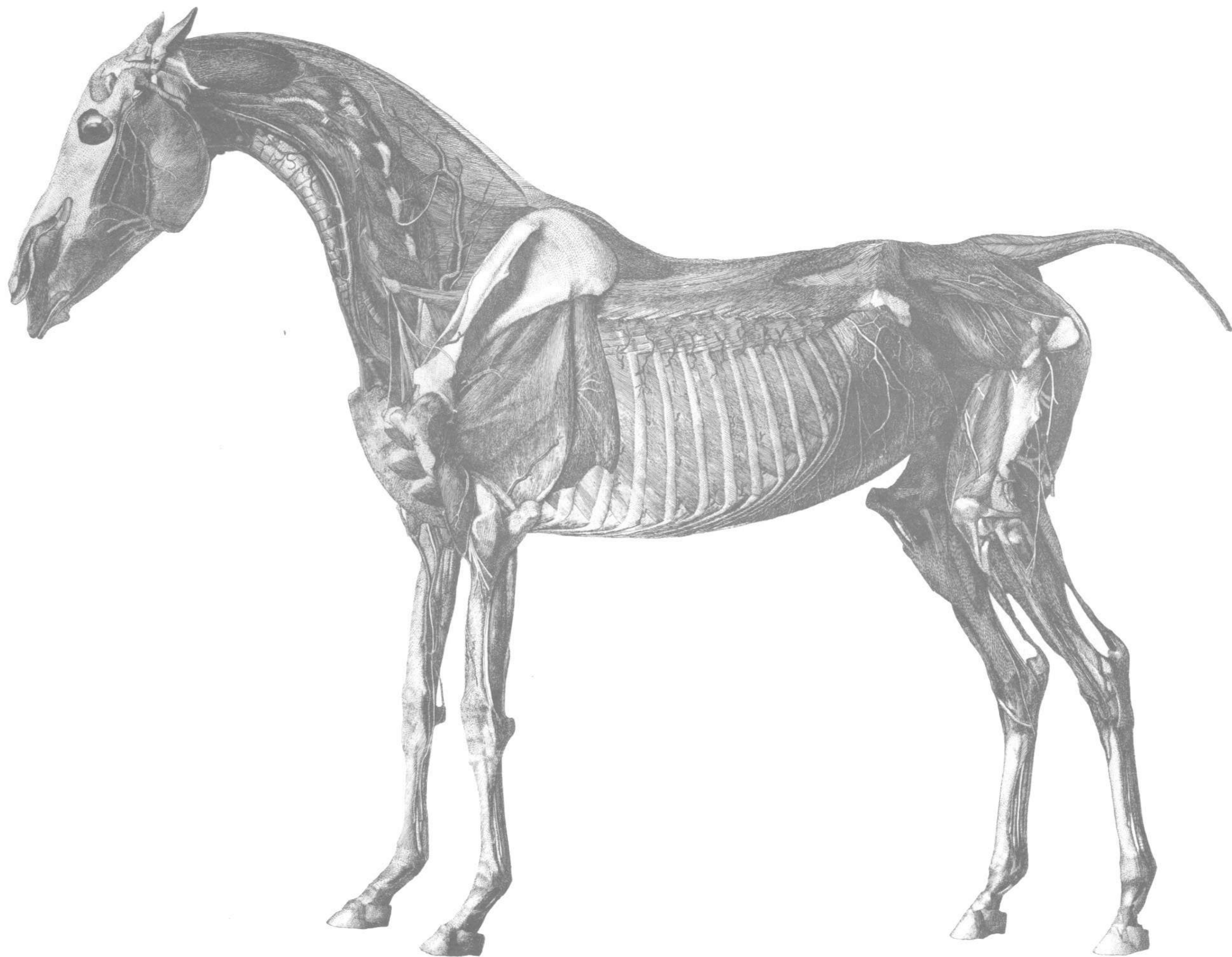
from Stubbs, THE ANATOMY OF THE HORSE



THE HORSE (STUBBS—PLATE 6)

FOURTH ANATOMICAL TABLE

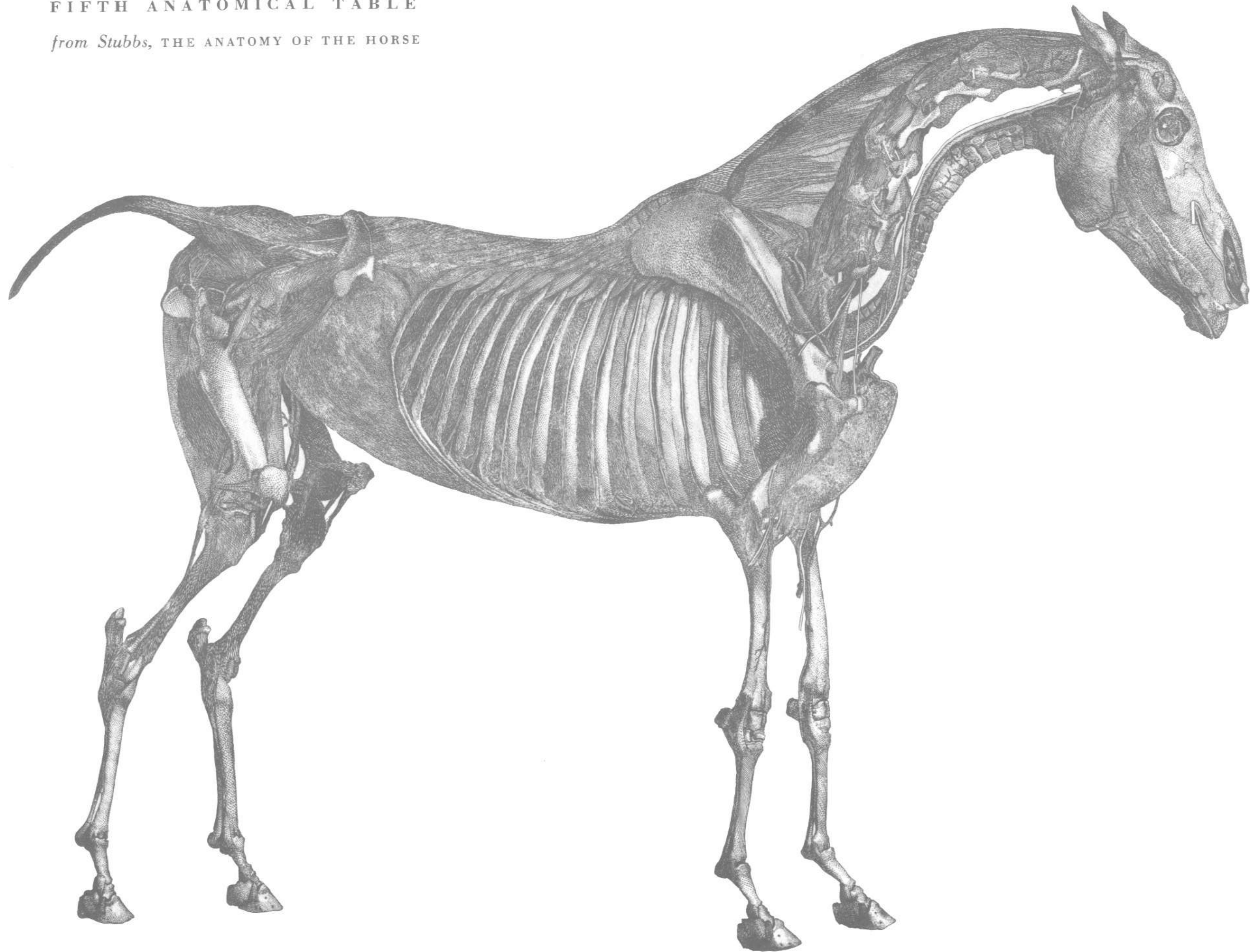
from Stubbs, THE ANATOMY OF THE HORSE



THE HORSE (STUBBS—PLATE 7)

FIFTH ANATOMICAL TABLE

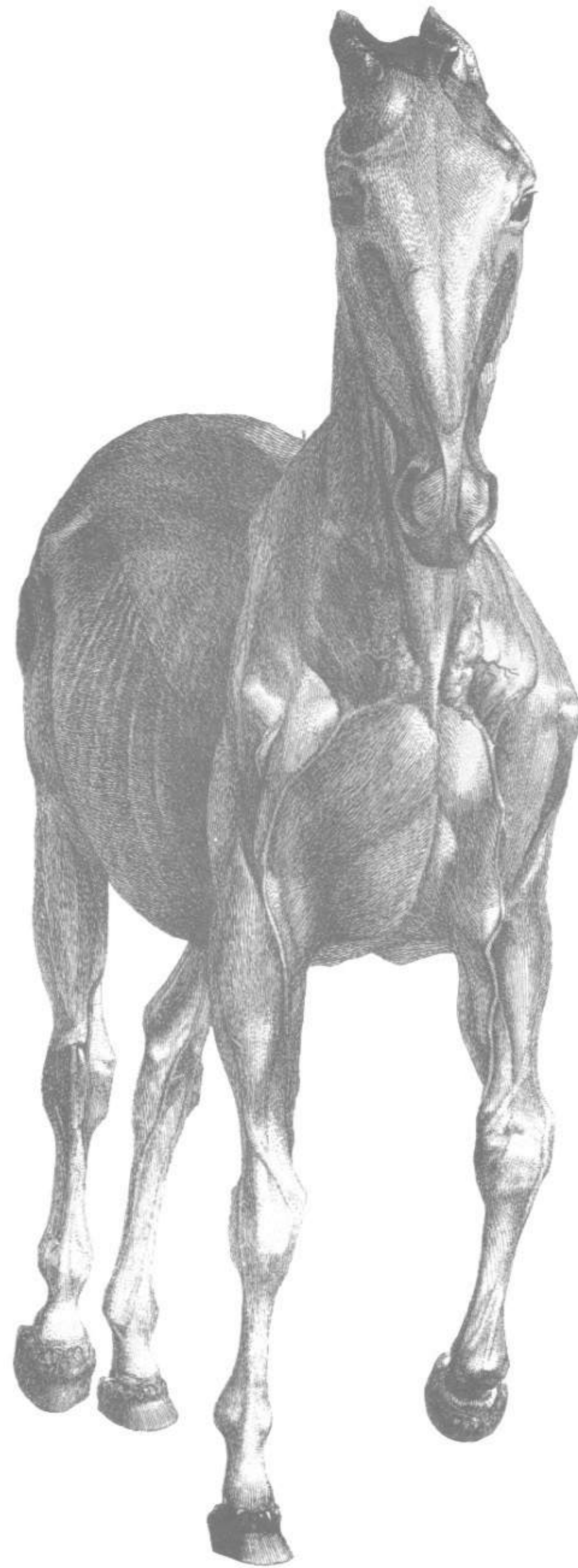
from Stubbs, THE ANATOMY OF THE HORSE



THE HORSE (STUBBS—PLATE 8)

SIXTH AND SEVENTH ANATOMICAL TABLES


from Stubbs, THE ANATOMY OF THE HORSE



THE HORSE (STUBBS—PLATE 9)

EIGHTH AND NINTH ANATOMICAL TABLES

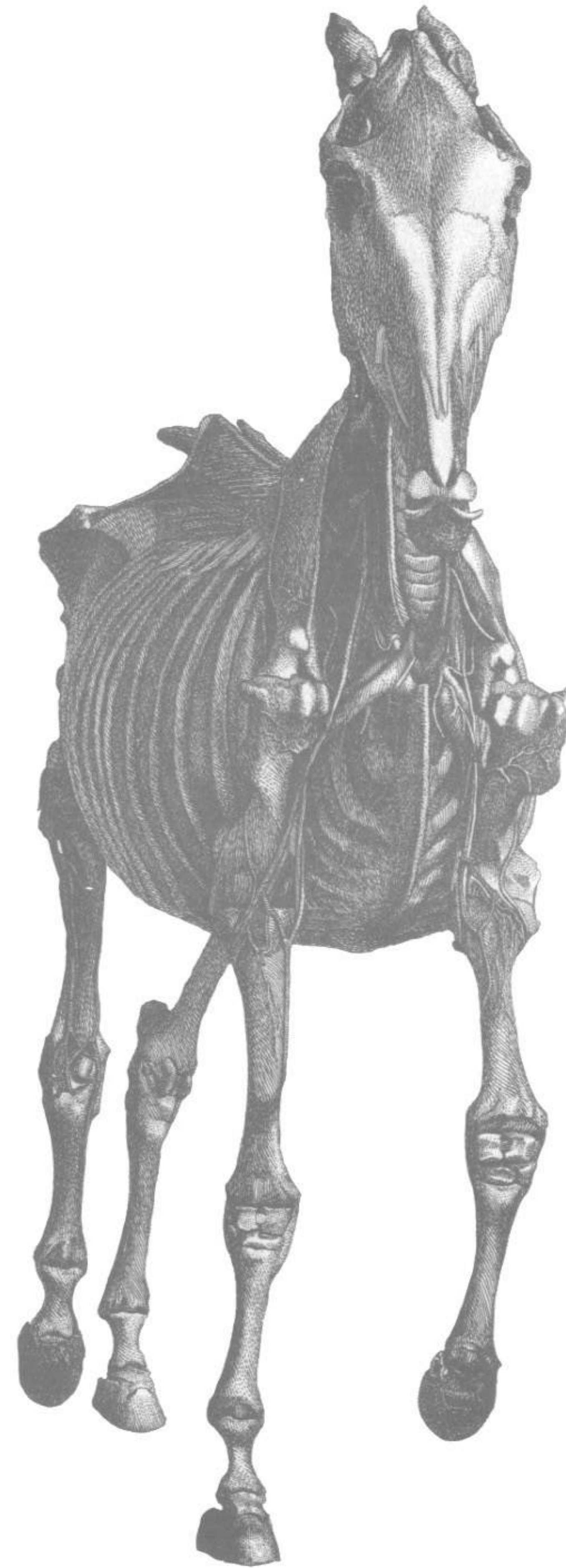

from Stubbs, THE ANATOMY OF THE HORSE



THE HORSE (STUBBS—PLATE 10)

TENTH AND ELEVENTH ANATOMICAL TABLES



from Stubbs, THE ANATOMY OF THE HORSE



THE HORSE (STUBBS—PLATE 11)

TWELFTH AND THIRTEENTH ANATOMICAL TABLES

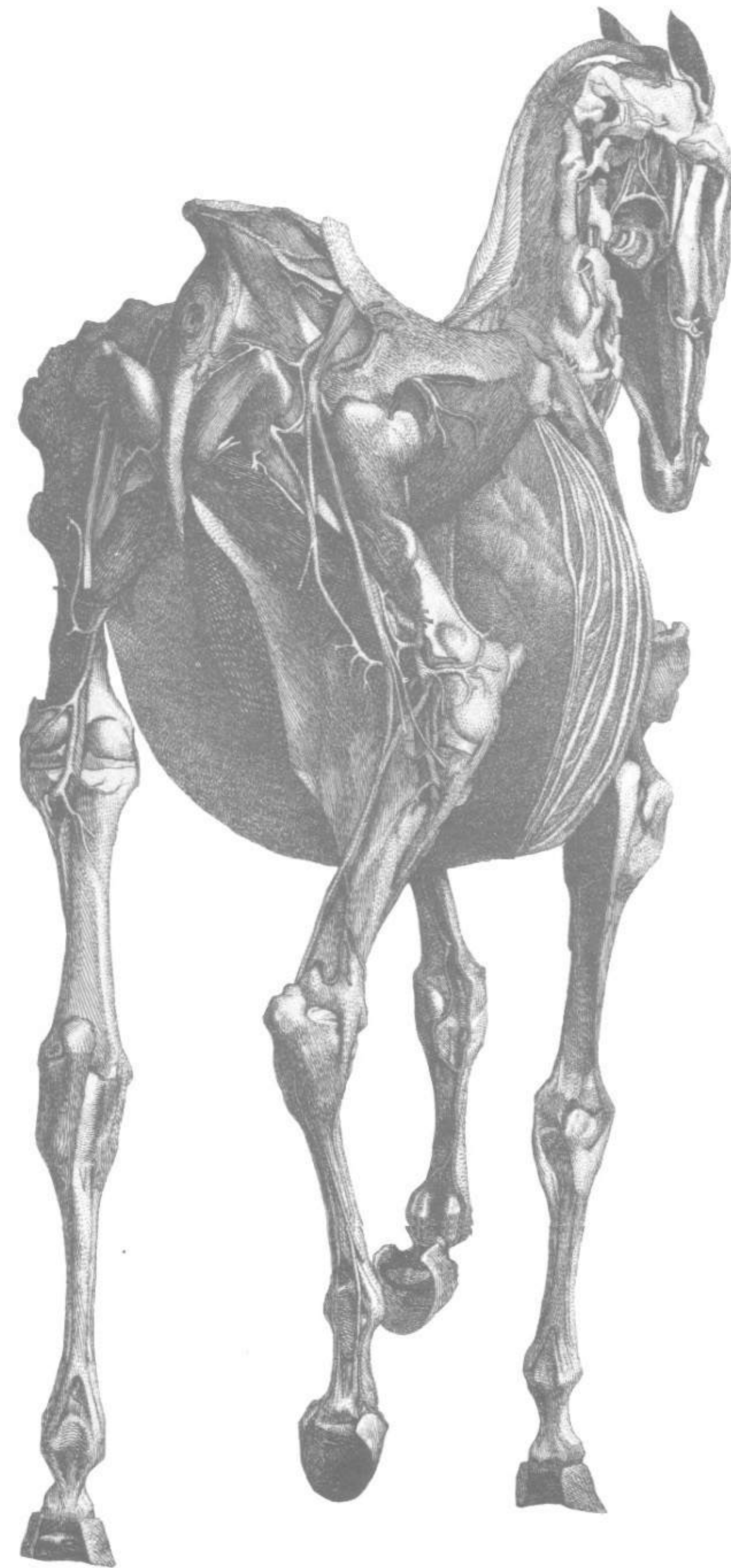

from Stubbs, THE ANATOMY OF THE HORSE



THE HORSE (STUBBS—PLATE 12)

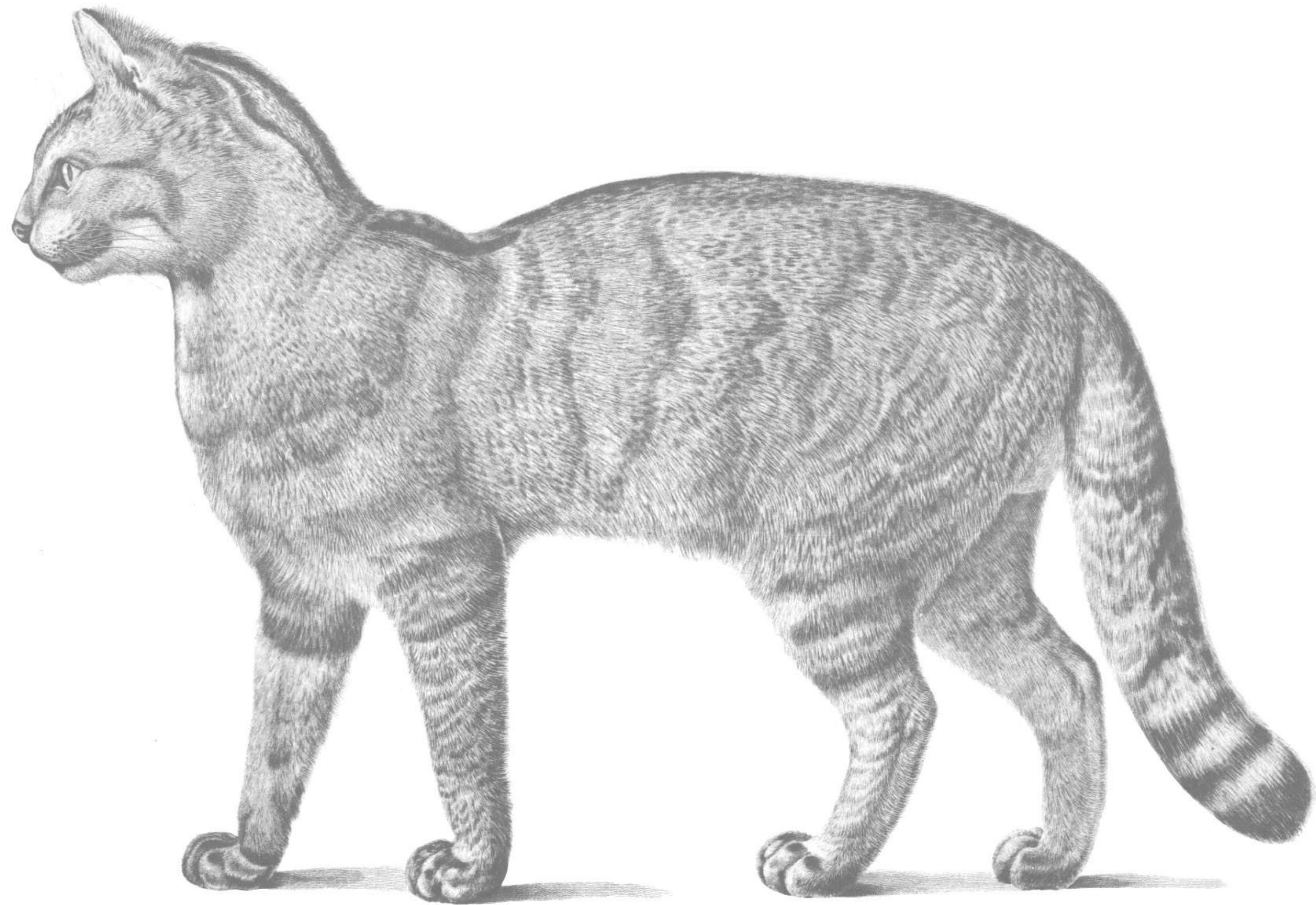
FOURTEENTH AND FIFTEENTH ANATOMICAL TABLES

from Stubbs, THE ANATOMY OF THE HORSE



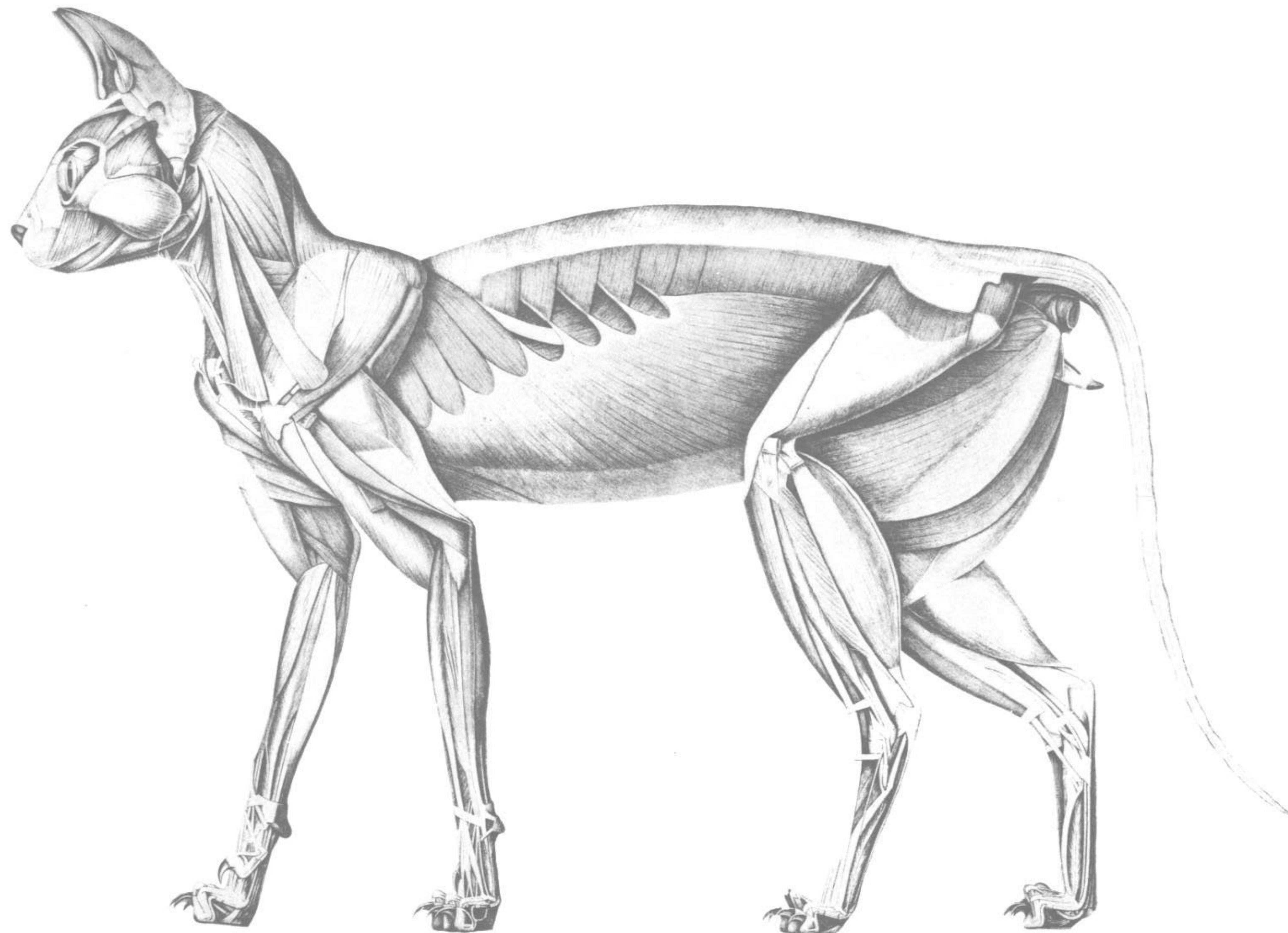
THE CAT (STRAUS-DURCKHEIM — PLATE 1)

from Straus-Durckheim, ANATOMIE DESCRIPTIVE ET COMPARATIVE DU CHAT



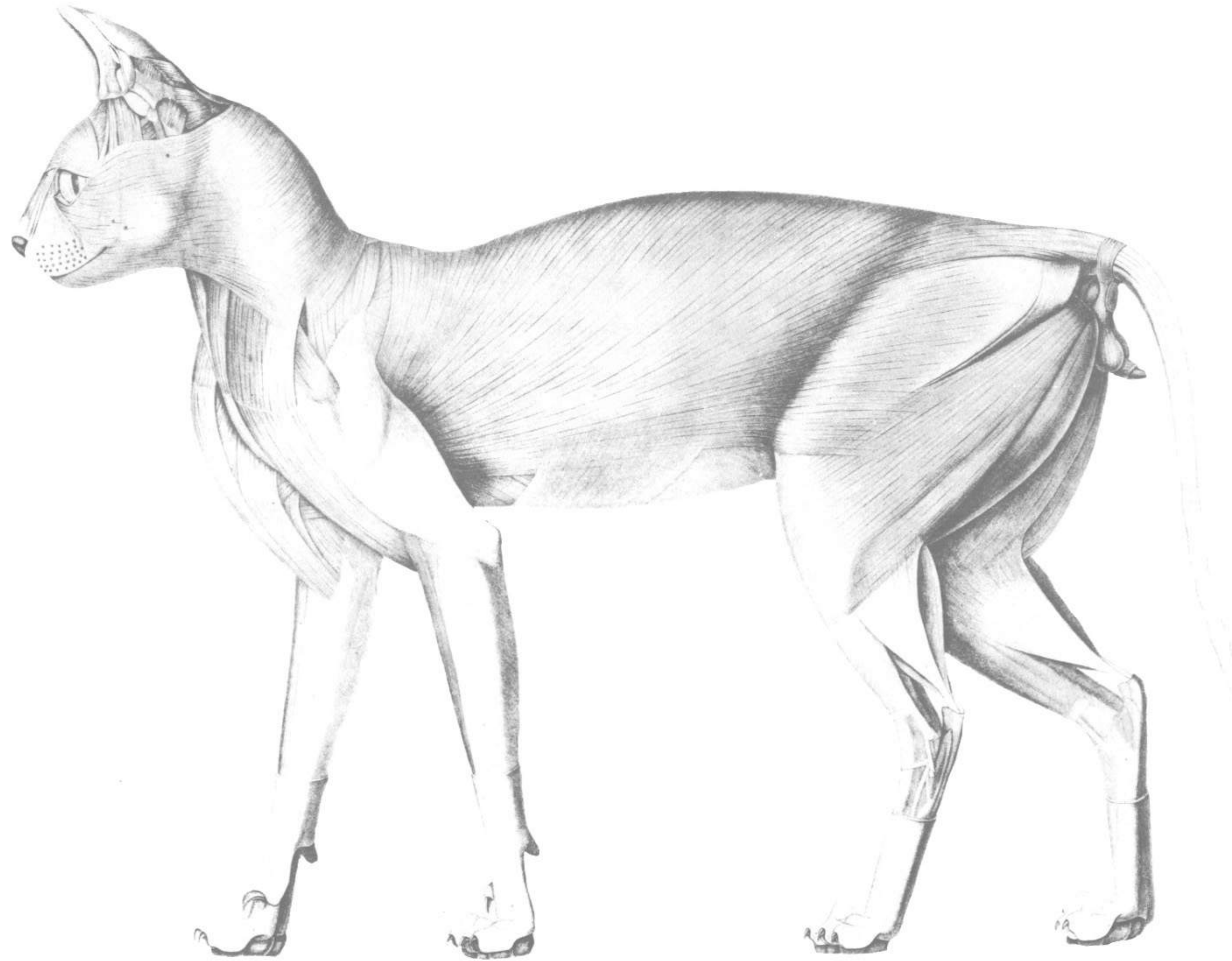
THE CAT (STRAUS-DURCKHEIM — PLATE 2)

from Straus-Durckheim, ANATOMIE DESCRIPTIVE ET COMPARATIVE DU CHAT



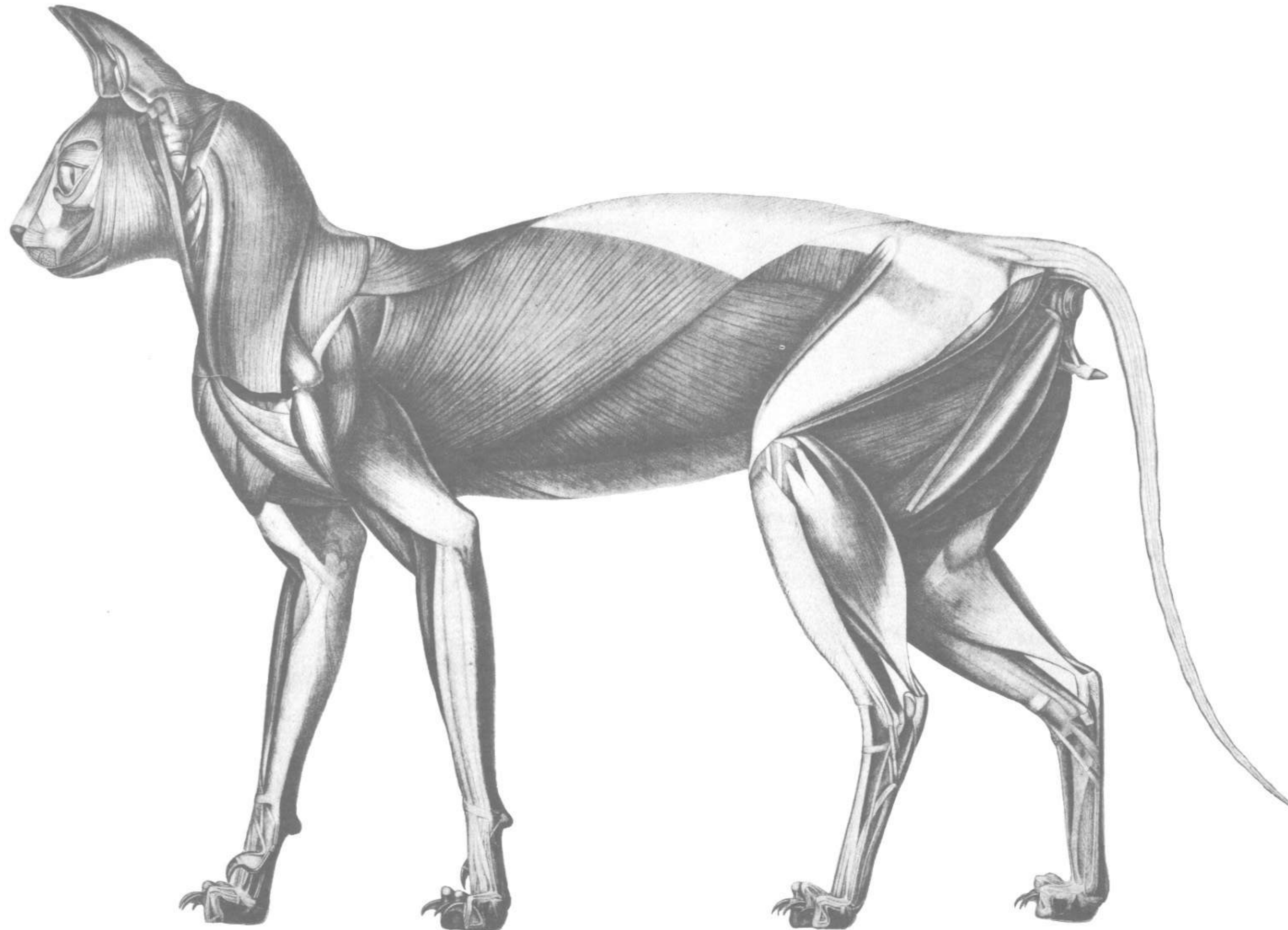
THE CAT (STRAUS-DURCKHEIM—PLATE 3)

from Straus-Durckheim, ANATOMIE DESCRIPTIVE ET COMPARATIVE DU CHAT



THE CAT (STRAUS-DURCKHEIM—PLATE 4)

from Straus-Durckheim, ANATOMIE DESCRIPTIVE ET COMPARATIVE DU CHAT



THE MONKEY, SEAL, HARE, RAT KANGAROO, FLYING SQUIRREL, AND BAT (CUVIER)

IDENTIFYING SYMBOLS USED IN THE FOLLOWING CUVIER PLATES

MUSCLES OF THE HEAD

t—temporal
o—orbicularis oculi
l—dilator naris lateralis
h—zygomaticus minor
z—zygomaticus
m—masseter
b—buccinator
o—orbicularis oris
d—digastricus
r—parotido-auricularis
*r*²—scutulo-auricularis superioris
Φ—scutulo-auricularis inferioris
π—scutularis
γ—auditory passage

MUSCLES OF THE NECK AND SHOULDER

a—trapezius (in monkey); brachiocephalicus
 cleido-cervicalis and cleido-
 mastoideus (in seal)
*a*¹, *a*²—trapezius
b—sterno-mastoideus sterno-cephalicus
*b*¹—sterno-mandibularis sterno-cephalicus
e—omo-hyoideus
d—omo
*k*¹—deltoid
g—mylo-hyoideus
x—sterno-thyro-hyoideus
L, *L*¹—complexus

MUSCLES OF THE BODY

5^a—cutaneus maximus, scapular portion (skin
 muscle)
5^b—cutaneus maximus, dorsal portion (skin
 muscle)
5^c—cutaneus maximus, lateral portion (skin
 muscle)
5^d—cutaneus maximus, ventral portion (skin
 muscle)
7—external intercostal
8—internal intercostal
10, *11*—small denticulated muscle
13, *13*²—obliquus abdominis externus
14—transversus abdominis
15—rectus abdominis
a—gluteus maximus
*a*¹—gluteus medius
*c*²—rhomboideus
g—serratus thoracis
i—latissimus dorsi
j—superficial pectoral
*j*¹—posterior deep pectoral
*j*²—anterior pectoral
k—deltoid
n—subscapularis
o—infraspinatus
r—supraspinatus
N^o—testicle
6—scalenus, exterior portion
6^a—scalenus, middle portion

6^b—scalenus, interior portion

A—spinalis dorsi

B—longissimus dorsi

C—longissimus costarum

D—longissimus cervicis

MUSCLES OF THE FRONT LEG (OUTSIDE VIEW)

t, *t*³—triceps (long head)

*t*²—triceps (lateral head)

v—long supinator

*v*¹—short supinator

δ—exterior corpi radialis

ε—common digital extensor

ε—extensor of little finger

6—ulnaris lateralis

*6*¹—flexor carpi ulnaris

ζ—long extensor of thumb

*μ*²—deep flexor

6—long common flexor

MUSCLES OF THE FRONT LEG (MEDIAL VIEW)

i—long abductor of the thumb

j—pectoral

L—long common flexor

m—short abductor of the thumb

n—subscapularis

o—*teres major*
 r—*biceps*
 t, t³—*triceps (long head)*
 t²—*triceps (lateral head)*
 u—*extensor of forearm*
 v—*brachialis*

MUSCLES OF THE HAND

p—*adductor of thumb*
 v¹—*interosseus dorsalis*
 ε¹—*extensor indicis*
 3—*extensor pollicis brevis*
 6—*abductor digiti quinti*

MUSCLES OF THE BACK LEG
(SUPERFICIAL)

a¹—*gluteus medius*
 a—*gluteus maximus*

q¹, q²—*biceps femoris*
 r—*semi-tendinosis*
 s—*semi-membranosis*
 x—*fascia lata*
 ρ—*sphincter ani externus*
 m—*vastus lateralis*
 p—*rectus femoris*

MUSCLES OF THE BACK LEG
(MEDIAL VIEW)

α—*gastrocnemius*
 i—*iliopsoas*
 p—*rectus femoris*
 n—*vastus medialis*
 s—*semi-membranosis*
 f—*adductor brevis*
 u—*gracilis*
 3—*extensor digitorum longi*

MUSCLES OF THE BACK LEG (DEEPER)

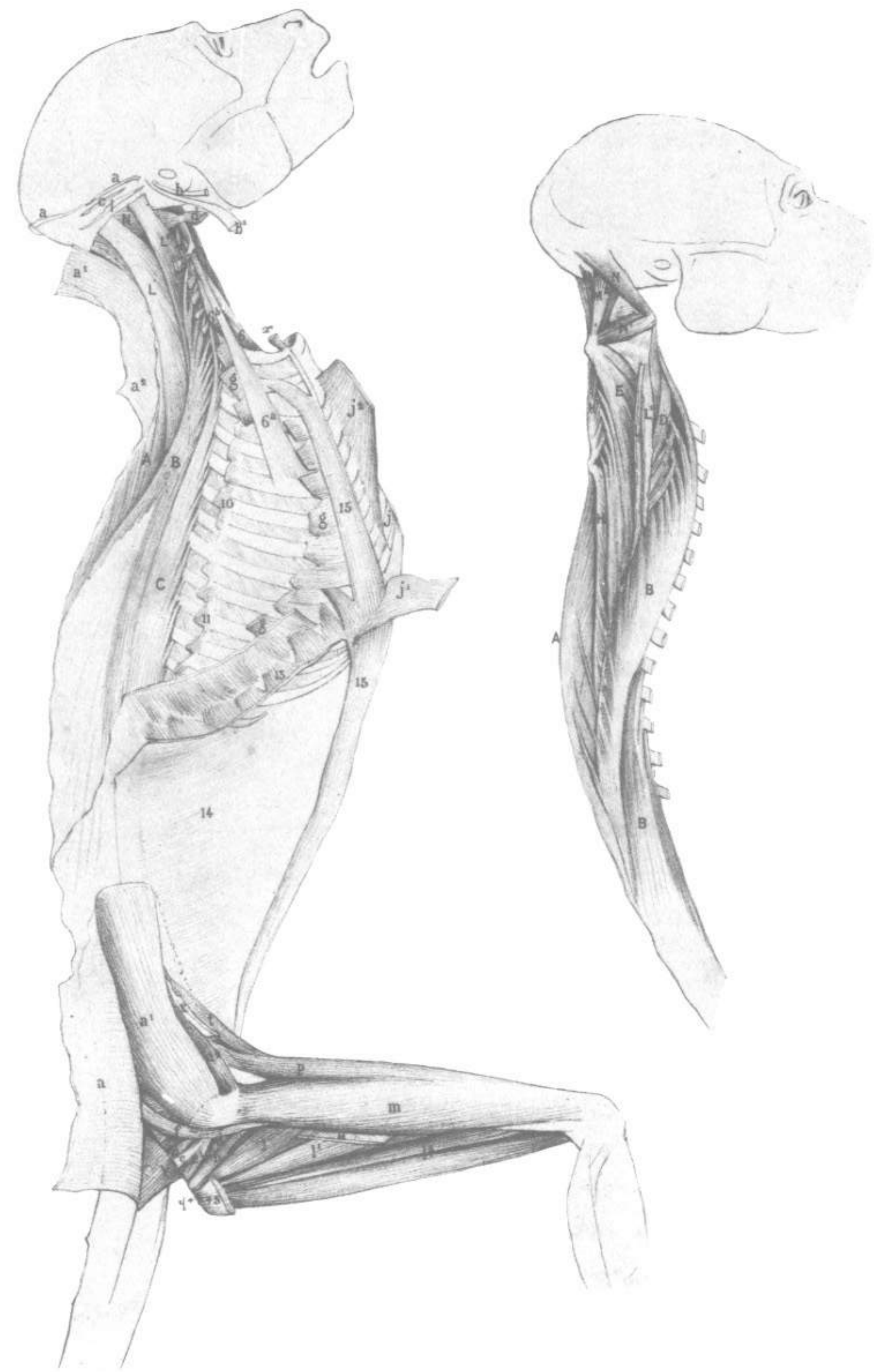
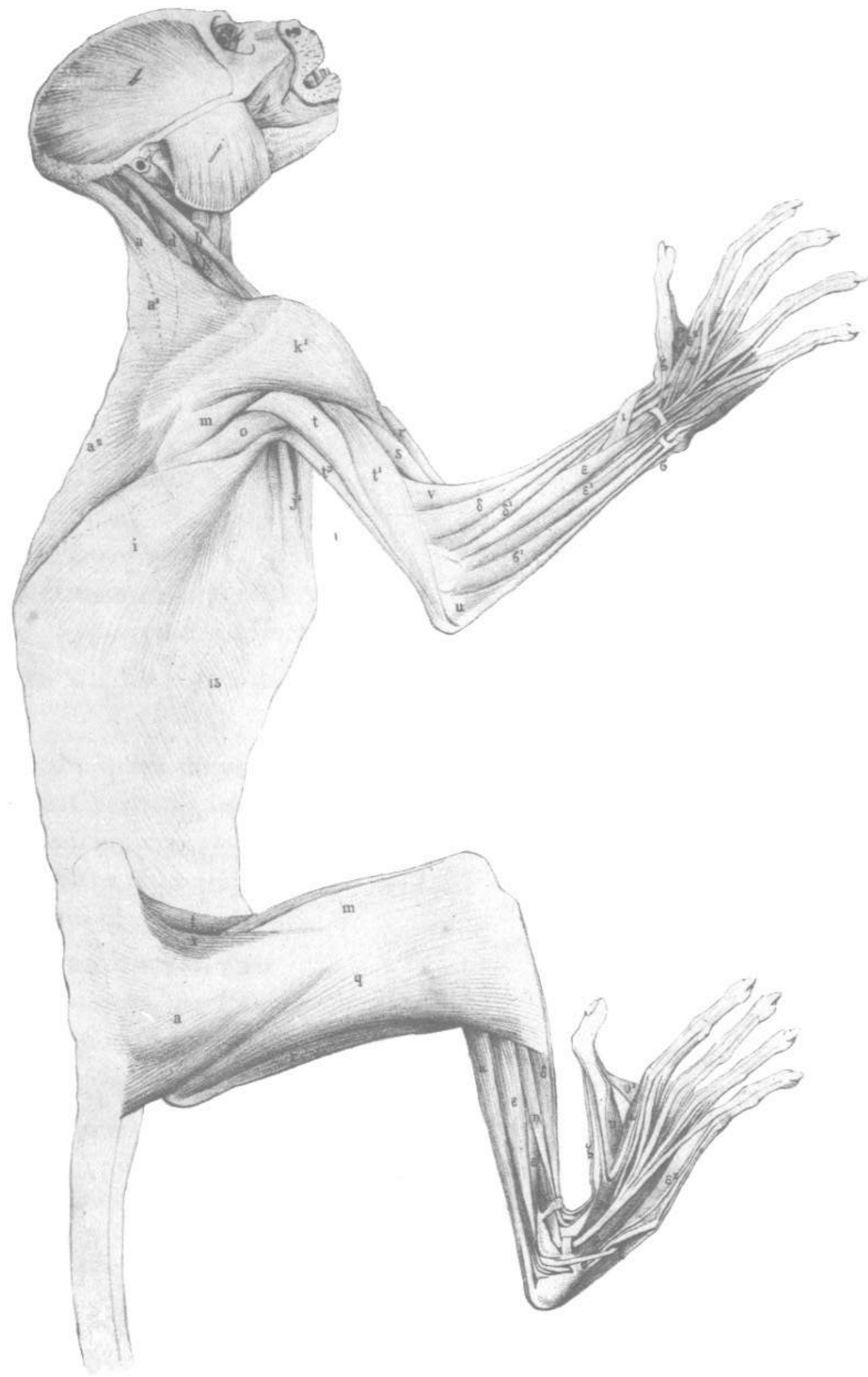
ε—*peroneus longus*
 ε¹—*peroneus tertius*
 ε²—*peroneus brevis*
 ζ—*long common extensor*
 ζ₂—*long digital extensor*
 ρ—*short common extensor*

MUSCLES OF THE FOOT

α—*gastrocnemius*
 ε, ε¹—*peroneus longus*
 ε²—*peroneus brevis*
 η—*interossei dorsales*
 v—*adductor obliquus*
 v¹—*adductor transversus*
 μ—*extensor hallucis brevis*
 3—*extensor digitorum longi*

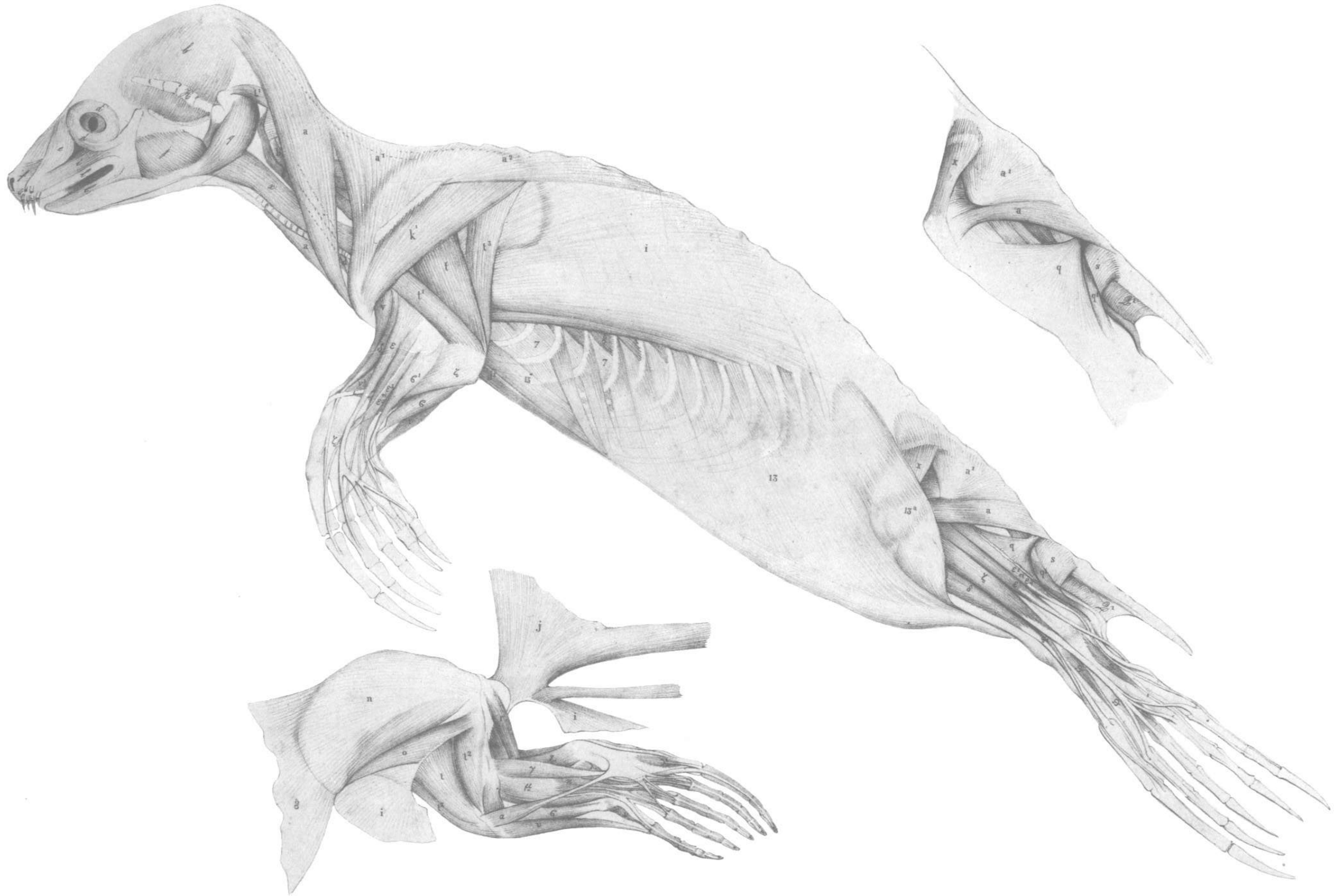
THE MONKEY (CUVIER)

from Cuvier, *Laurillard*, ANATOMIE COMPARÉE



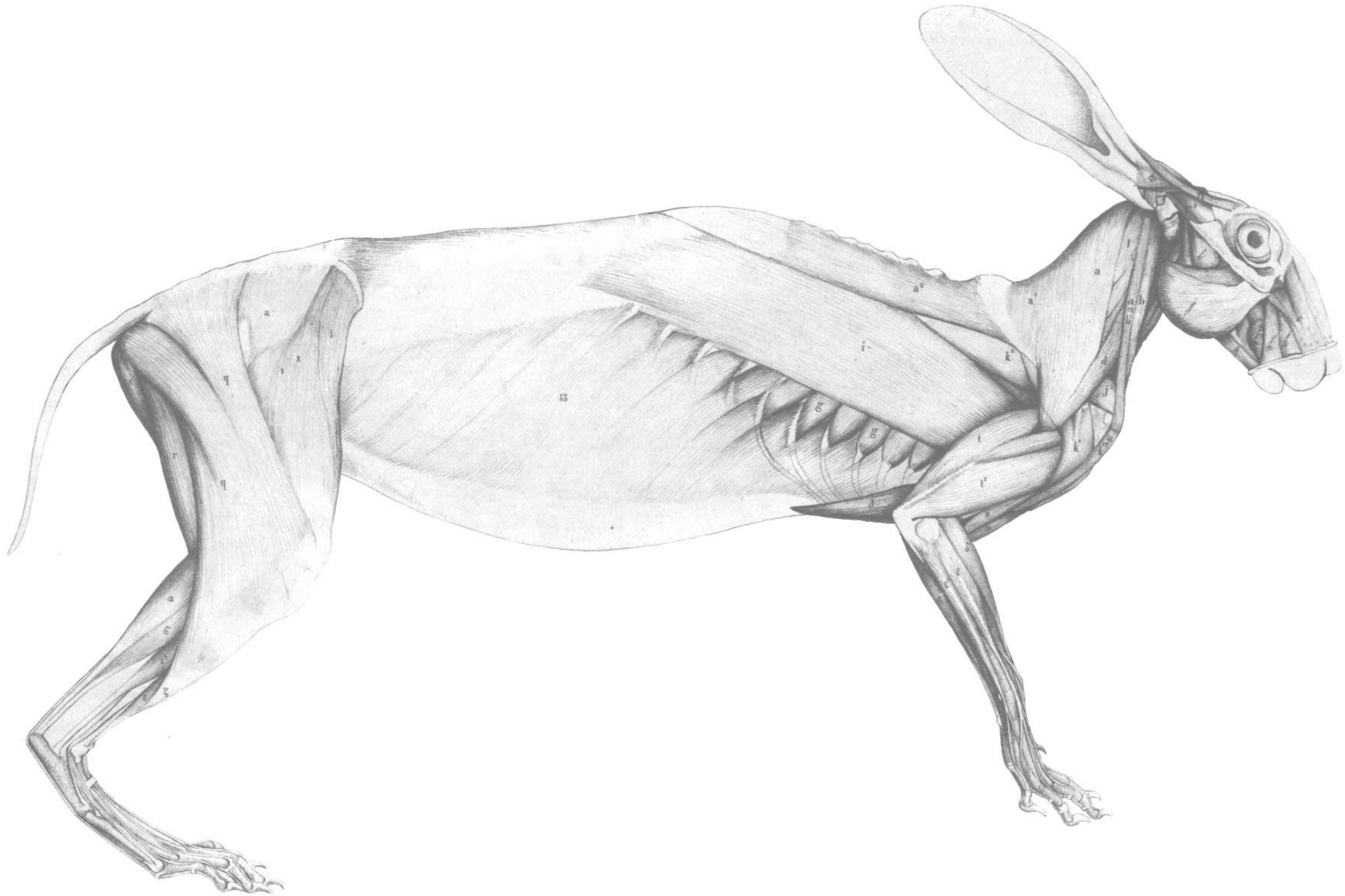
THE SEAL (CUVIER)

from Cuvier, Laurillard, ANATOMIE COMPARÉE



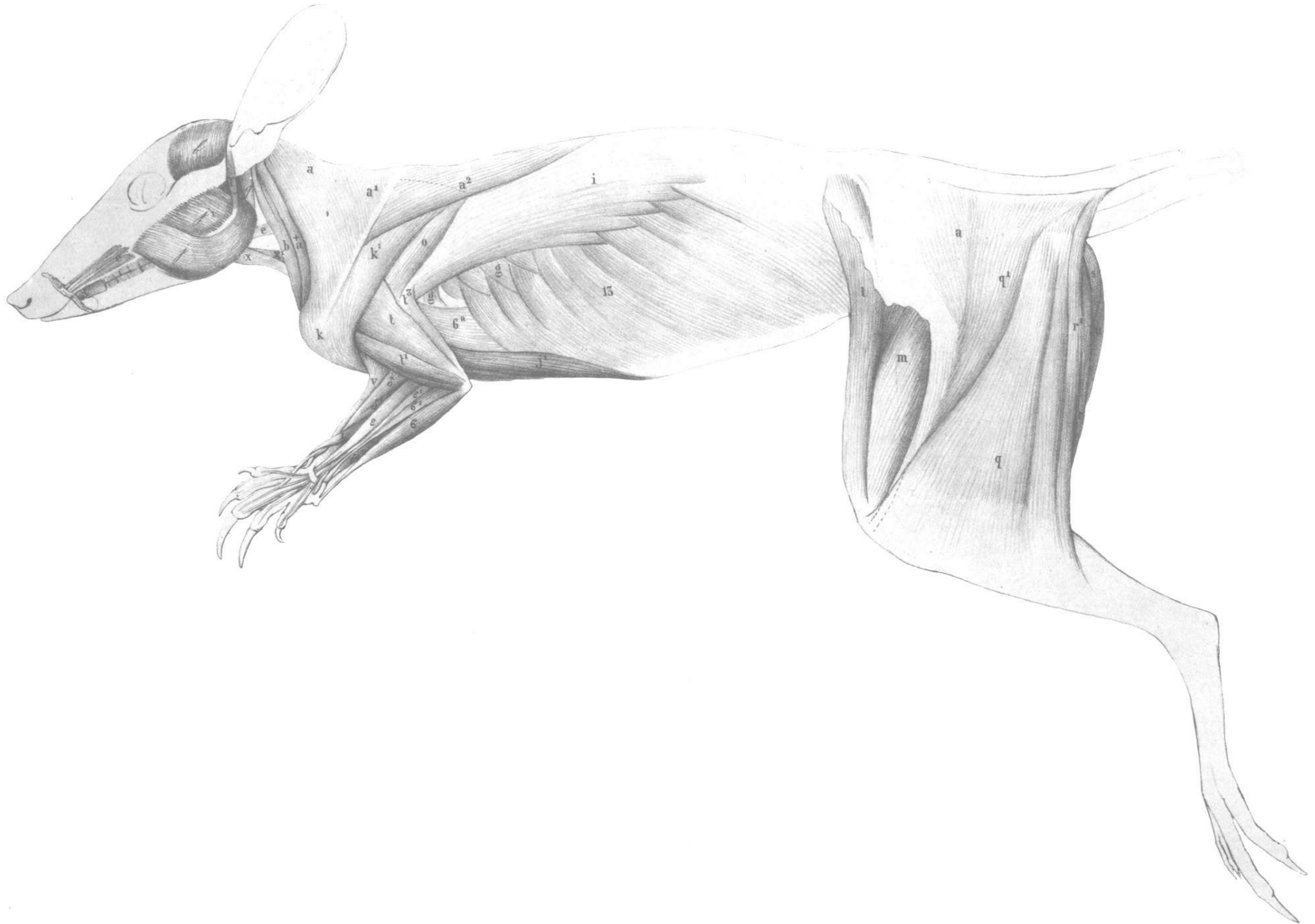
THE HARE (CUVIER)

from Cuvier, Laurillard, ANATOMIE COMPARÉE



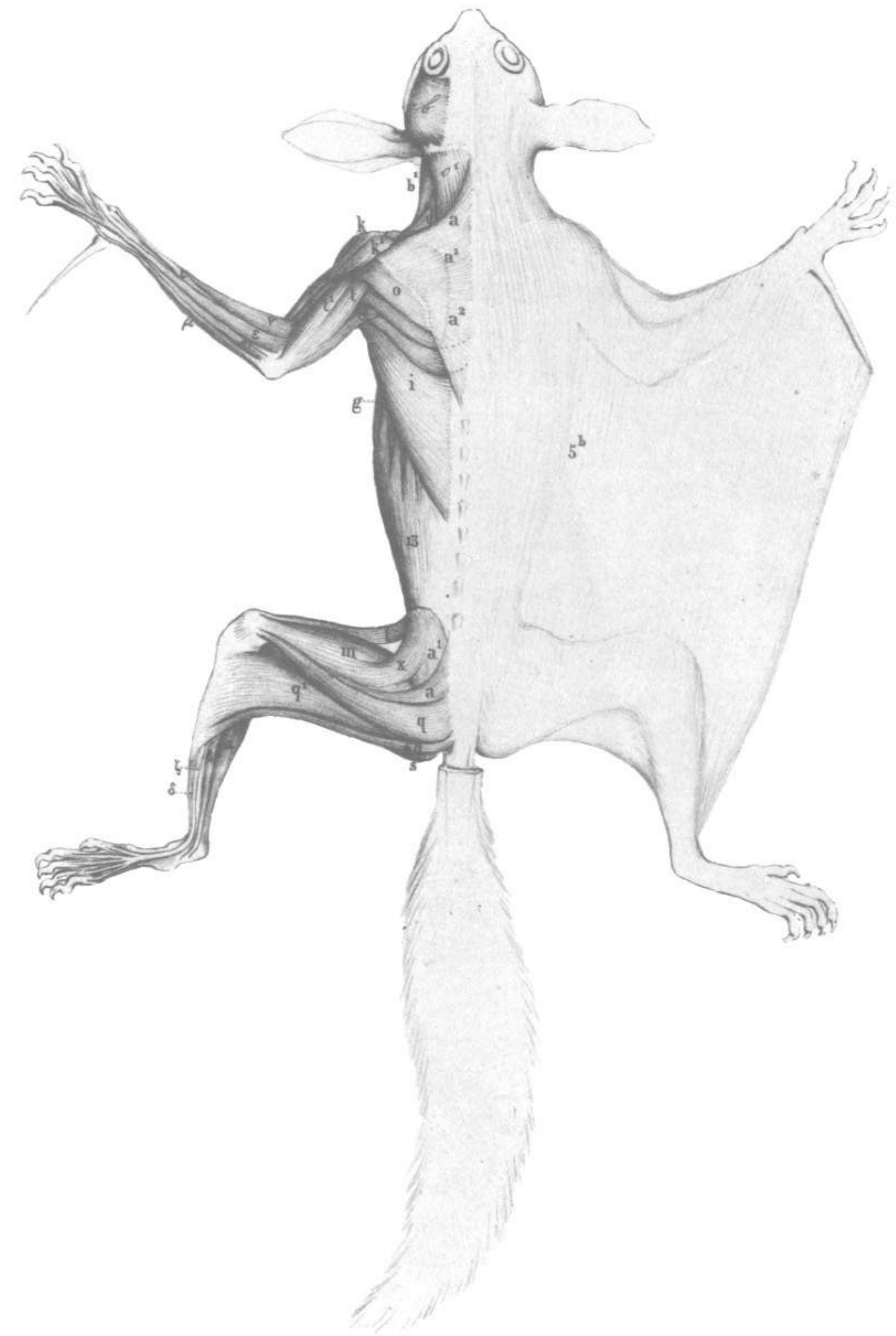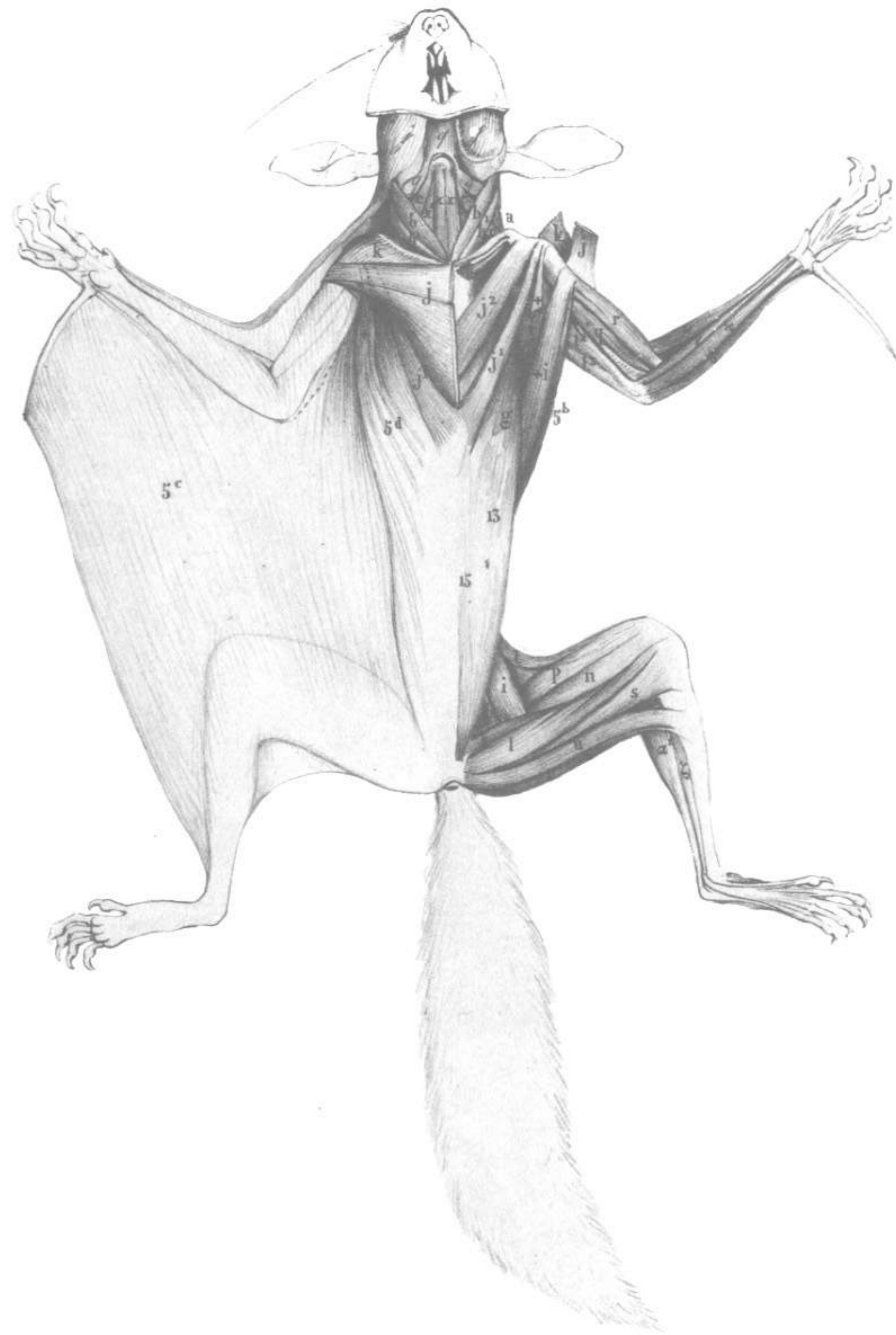THE RAT KANGAROO (CUVIER)

from Cuvier, Laurillard, ANATOMIE COMPARÉE



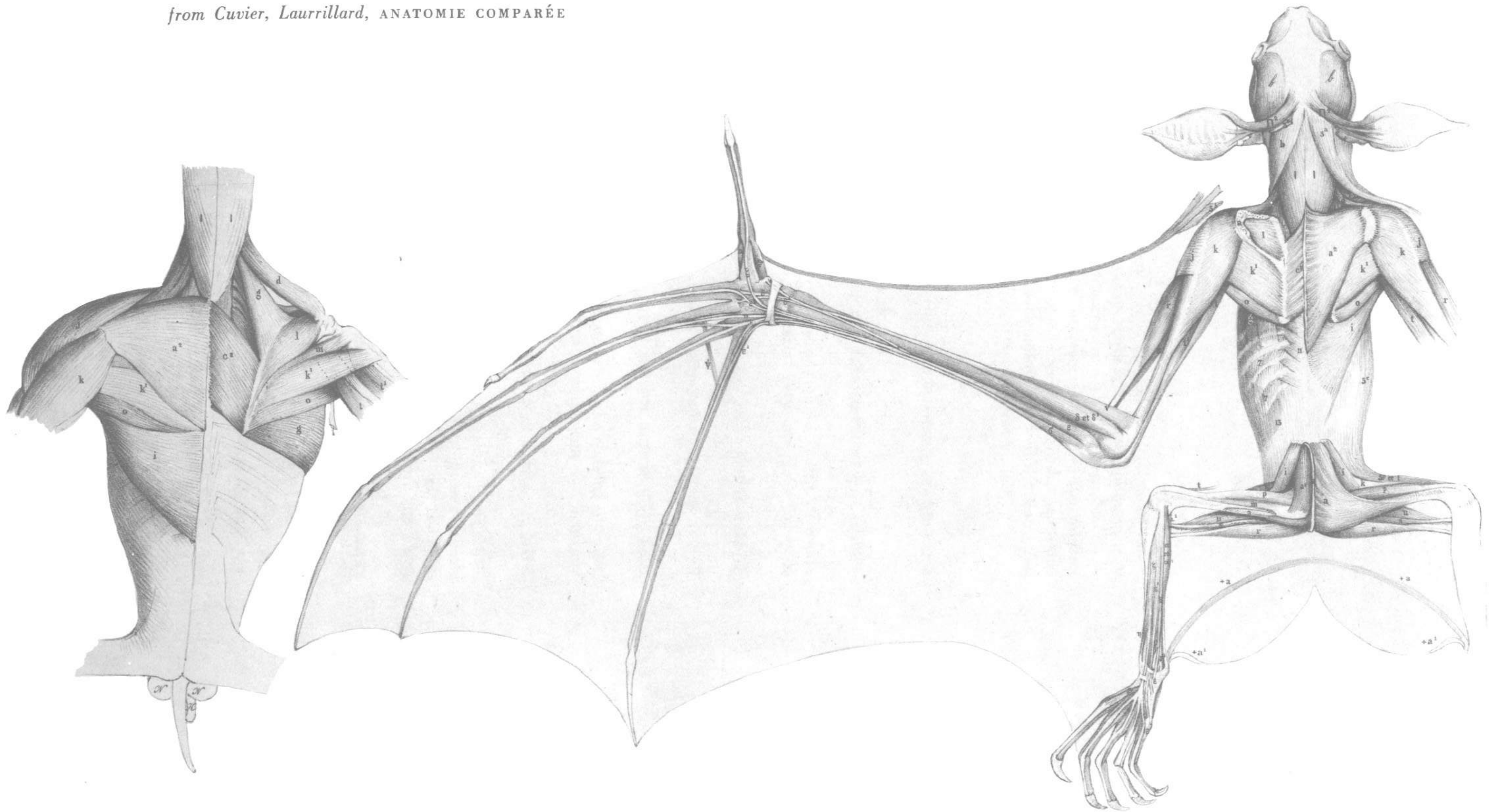
THE FLYING SQUIRREL (CUVIER)

from Cuvier, *Laurrillard*, ANATOMIE COMPARÉE



THE BAT (CUVIER)

from Cuvier, Laurillard, ANATOMIE COMPARÉE



Bibliography

For those who wish to go beyond the necessarily limited scope of this book, this annotated list of books is included. Unfortunately, some of the better anatomical works are not easily accessible. Some are out of print, and many are in foreign languages. The volumes selected are those which have, for one reason or another, appealed to me. Most of the works are non-technical or so well illustrated that a large part of them can be grasped by the artist visually.

ANATOMY

Baum, Hermann; Zietzmann, Otto. HANDBUCH DER ANATOMIE DES HUNDES. Berlin, 1936.

Very good material on the dog.

Boas, J. E. V.; Paulli, Simon. THE ELEPHANT'S HEAD. Carlsburg Fund. Copenhagen, 1908.

Studies in the comparative anatomy of an Indian elephant's head and those of other mammals. Very fine plates, many in full color. 2 volumes.

Bronn, H. G. KLASSEN UND ORDNUNGEN DES THIER-REICHS. Leipzig, 1876.

A good and extensive series of comparative skeletons as well as some good muscle plates.

Brown, Lewis S. ANATOMY OF THE HORSE FOR ARTISTS. New York, 1948.

A comparison of the human and horse forms showing structure, proportion, and action. Contains measurements for light and heavy breeds.

Camper, Pierre. DESCRIPTION ANATOMIQUE D'UN ÉLÉPHANT, MÂLE. Paris, 1802.

Cuvier, George; Laurillard M. ANATOMIE COMPARÉE. Paris, 1849.

Contains fine anatomical drawings of many different animals from man to mouse, bat to elephant. One of the best comparative anatomies for artists. The volume from which the plates in this book were taken.

Ellenberger, W.; Baum, H.; Dittrich, H. HANDBOOK OF ANATOMY OF ANIMALS FOR ARTISTS. London, 1901. 5 vols.

Text on the horse in English, French, and German; text on other animals in German. This book rightly remains the standard in the field. Source of the plates in the present volume.

Ellenberger, W.; Baum, H. HANDBUCH DER VERGLEICHENDEN ANATOMIE DER HAUSTIERE. Berlin, 1908.

Excellent book on the anatomy of bovines.

- ANATOMIE DES HUNDES. Berlin, 1891.
Excellent work on the anatomy of dogs.
- ANATOMIE DES PFERDES. Berlin, 1893.
Excellent work on the anatomy of horses.
- Friedenthal, H.* DAS HAARKLEID DES MENSCHEN. Jena, 1908.
Shows the hair patterns of men and animals. Many plates in color.
- BEITRÄGE ZUR NATURGESCHICHTE DES MENSCHEN. Jena, 1910.
- TIERHAARATLAS. Jena, 1911. 5 volumes.
Good for skin and fur textures. Many color plates.
- Knight, C. R.* ANIMAL ANATOMY AND PSYCHOLOGY. New York, 1947.
A good work on comparative anatomy by a master draftsman.
- Leisering, A. G. T.* ATLAS DER ANATOMIE DES PFERDES. Leipzig, 1861.
Some Ellenberger anatomy plates of domestic animals; dogs, horses, pigs, cows.
- Matthew, W. D.; Chubb, S. H.* EVOLUTION OF THE HORSE. American Museum of Natural History, Guide Leaflet Series 36.
One of the best brief accounts of the evolution of the horse. Contains photographs of skeletons of both early and recent horse forms found in the American Museum of Natural History. Mr. Chubb spent over 45 years at the museum on equine osteology and is one of the great authorities.
- Pander, C. H.* ATLAS VERGLEICHENDE OSTEOLOGIE. Bonn, 1828.
Bone structure of many animals as shown in relation to the outer form.
- Reighard, Jacob; Jennings, H. S.* ANATOMY OF THE CAT. New York, 1902.
- Ruge, George.* DIE GESICHTSMUSKULATUR DER PRIMATEN. Leipzig, 1887.
- Schmaltz, Reinhold.* ATLAS DER ANATOMIE DES PFERDES. Berlin, 1927.
- Schaeffer, Maximilian.* TIERFORMEN (ATLAS). Berlin, 1899. 2 volumes.
Comparative anatomy.
- Sisson, S.* THE ANATOMY OF THE DOMESTIC ANIMALS. Third edition revised by J. D. Grossman. Philadelphia, 1938.
Standard work on anatomy for veterinarians. Contains many Ellenberger plates and excellent photographs. Includes the horse, cow, dog, sheep, pig, and an appendix on the chicken. The best source of information on the action of muscles.
- Straus-Durckheim, Hercule.* ANATOMIE DESCRIPTIVE ET COMPARATIVE DU CHAT. Paris, 1845.
Complete and excellent work on the cat. Many plates. This is the volume from which the cat plates in this book were taken.
- Stubbs, George.* THE ANATOMY OF THE HORSE. London, 1776. Reprinted London, 1938.
A monumental work on the horse. This is the volume from which the Stubbs plates in this book were taken.
- Tschaggeny, Edmond.* ATLAS D'ANATOMIE DE L'ESPÈCE BOVINE. Bruxelles, 1921. 2 volumes.
Plates on domestic cattle.
- Wolton, Elizah.* THE CAMEL. London, 1865.
Anatomy and proportions of the camel.

ANIMAL MOTION

Howell, A. Brazier. SPEED IN ANIMALS. Chicago, 1944.

A very good work on the way animals move. Rather technical.

Muybridge, Eadweard. ANIMALS IN MOTION. London, 1899. Reprinted in 1925. (*Dover reprint*)

The classic work for artists on animal motion and still the best on the subject. Most subsequent studies have been drawn from it.

Stillman, J. A. B. THE HORSE IN MOTION. Boston, 1882.

Based on Muybridge observations, but Muybridge's book is greatly preferred.

ANIMAL PROPORTION AND MEASUREMENTS

Boone and Crocket Club. NORTH AMERICAN BIG GAME. New York, 1939.

Chubb, S. Harstead. MAN O' WAR AND GALLANT FOX. New York, 1931. Museum of Natural History Publication.

Exact measurements of two of America's greatest thoroughbred racehorses, taken as three year olds at racing peak.

Mochi, Ugo; Carter, T. Donald. HOOVED MAMMALS OF THE WORLD. New York, 1953.

Illustrated with silhouettes of hundreds of different animals reproduced at exactly 1/32 life size. Text by one of world's authorities on mammals.

Seton, Ernest Thomson. ART ANATOMY OF ANIMALS. London, 1896.

This is listed here because the best information seems to me to be on measurements and proportion rather than on general anatomy. This was one of Seton's earliest works, and the drawings are not in all cases to be relied upon.

Ward, Roland. RECORDS OF BIG GAME. London, 1928.

The most authoritative and complete work on animals for descriptions and exact measurements. Very useful information for the artist.

ANIMAL DRAWING AND PAINTING

LES ANIMAUX. Ed. by A. Dayot, Lt. Chollet, H. Neuville and others. Maison d'édition. Paris. 2 volumes.

Animals in legend, science, work, sport, art and their utilization by man. Many interesting illustrations.

Brown, Paul. THE HORSE. New York, 1943.

A good book of sketches of the horse showing gaits and conformation by one of America's best horse artists. Many other books on horses written and illustrated by Mr. Brown are both easily available and excellent.

Dayot, Armand. ANIMAUX DESCRIPTIFS. Paris, 1930. 4 volumes.

Excellent paintings, drawings, and sculpture both realistic and simplifies.

Keller, Otto. DIE ANTIKE TIERWELT. Leipzig, 1909. 2 volumes.

Animals as represented in art through the ages.

Kley, Heinrich. THE DRAWINGS OF HEINRICH KLEY. Los Angeles, 1941.
2 volumes. (*Dover reprint*)

Beautiful drawings by one of the great draftsmen of both people and animals.

Knight, Charles R. LIFE THROUGH THE AGES. New York, 1946.

One of America's great animal artists. His paintings and sculpture enrich many natural history museums.

Kuhnert, Wilhelm. FARBIGE TIERBILDER. Berlin. n.d.

Many good reproductions in color.

Lydekker, Richard. ANIMAL PORTRAITURE. London. n.d.

Fifty studies of birds and animals in full color.

Méheut, M. ÉTUDES D'ANIMAUX. Paris, 1911. 2 volumes.

Very good animal drawings.

Morris, George Ford. PORTRAITS OF HORSES. Shrewbury, N. J. 1953.

A leading American portrait painter of horses.

Munnings, Alfred. AUTOBIOGRAPHY. London, 1950. 3 volumes.

The work of England's best present-day painter of the horse.

New York Zoological Society. GALLERY OF WILD ANIMAL PAINTINGS IN THE ZOOLOGICAL PARK. New York, 1930.

Paintings by Carl Rungius, Charles R. Knight, and others.

Schaldach, William J. CARL RUNGIUS, A BIG GAME PAINTER. West Hartford, 1945.

A beautiful volume of Rungius' animal paintings. An animal painter of the first rank.

GOOD PUBLICATIONS ON MAMMALS

THE BOOK OF THE DOG. Edited by Brian Vesey-Fitzgerald. Los Angeles, 1948.

DISCOVERY REPORTS ON WHALES. Discovery Committee, Colonial Office, London. Cambridge University Press. 1929.

A treatise on elephant seals and whales. Well illustrated.

Encyclopedia Britannica. MAMMALS AND BIRDS. Britannica booklet No. 3. New York, 1933.

A selection of articles from the 14th edition of the Encyclopedia Britannica. Profusely and well illustrated.

National Geographic Society. WILD ANIMALS OF NORTH AMERICA. Edward W. Nelson. Washington, D. C., 1918.

Paintings by Louis Agassig-Fuertes.

—BOOK OF FISHES. Ed. by John Oliver La Gorce.

—BOOK OF DOGS. Ernest Harold Baynes.

Illustrated in color by Louis Agassig-Fuertes and Hashime Murayuma.

—CATTLE OF THE WORLD. Alvin H. Sanders.

Full color paintings by Edward Herbert Miner.

Seton, Ernest Thompson. LIVES OF GAME ANIMALS. New York, 1927. 4 volumes.

Illustrated largely with the author's drawings. Good reference on animal tracks among a lot of other things.

SMITHSONIAN SCIENTIFIC SERIES. Charles Greenley Abbott, editor.

THE HORSE

Brown, W. R. HORSE OF THE DESERT. New York, 1929. Reprinted New York, 1947.

A much cited book on the Arabian horse. Well illustrated.

Carter, W. H. HORSES OF THE WORLD. Washington, D. C., 1923.

Originally appeared as "The Story of the Horse" in the National Geographic Magazine, volume 44, 1923. Well illustrated in black and white and color.

Davenport, Homer. MY QUEST OF THE ARAB HORSE. New York, 1909.

Derhardt, R. M. THE HORSE OF THE AMERICAS. Norman, Oklahoma, 1947.

Harper, M. W. MANAGEMENT AND BREEDING OF HORSES. New York, 1913.

A book I have found very useful for general information on all breeds.

Hervey, John. THE AMERICAN TROTTER. Toronto, 1947.

An excellent reference book on the standard-bred.

—RACING IN AMERICA. New York, 1944.

Lamb, A. J. R. HORSE FACTS. Chicago, 1948.

Simpson, George Gaylord HORSES. New York, 1951.

The story of the horse family in the modern world and through sixty million years of history. Doctor Simpson heads the Department of Paleontology at the American Museum of Natural History. Written to be readily understood by the layman. No other book covers the subject so fully or authentically.

Sporting Life and Biographical Press. BRITISH HUNTS AND HUNSMEN. London, 1909. 4 volumes.

A vast collection of photographs of British horses, hounds and huntsmen.

Vesey-Fitzgerald, Brian, editor. THE BOOK OF THE HORSE. London, 1946.

Text in places is at variance with accepted fact, but beautifully illustrated.

Most horse breeding societies publish periodicals and pamphlets on their breeds, and such magazines as the *Thoroughbred Record*, the *Harness Horse*, *Horse World*, to mention a few, are good. The departments of agriculture, state and federal, also publish material. Information can be obtained from the Horse and Mule Association of America.

DOVER BOOKS ON ART INSTRUCTION

- PRINCIPLES OF PATTERN DESIGN, Richard M. Proctor. (26349-5) \$8.95
PATTERN DESIGN, Archibald H. Christie. (22221-7) \$9.95
PRACTICAL PORTRAIT PAINTING, Frank Slater. (Available in United States only) (26133-6) \$7.95
PENCIL DRAWING, Michael Woods. (Available in United States and Canada only) (25886-6) \$7.95
OIL PAINTING TECHNIQUES AND MATERIALS, Harold Speed. (25506-9) \$8.95
DESIGN YOUR OWN REPEAT PATTERNS, V. Ann Waterman. (25132-2) \$4.95
PRACTICAL GUIDE TO ETCHING AND OTHER INTAGLIO PRINTMAKING TECHNIQUES, Manly Banister. (25165-9) \$7.95
MODELLING AND SCULPTING THE HUMAN FIGURE, Edouard Lanteri. (25006-7) \$10.95
MODELLING AND SCULPTING ANIMALS, Edouard Lanteri. (25007-5) \$8.95
ETCHING, ENGRAVING AND OTHER INTAGLIO PRINTMAKING TECHNIQUES, Ruth Leaf. (24721-X) \$12.95
FIGURE SCULPTURE IN WAX AND PLASTER, Richard McDermott Miller. (Available in United States only) (25354-6) \$9.95
THE WAY TO SKETCH, Vernon Blake. (24119-X) \$4.95
ANIMAL SKETCHING, Alexander Calder. (20129-5) \$3.50
CARLSON'S GUIDE TO LANDSCAPE PAINTING, John F. Carlson. (22927-0) \$8.95
THE ARTISTIC ANATOMY OF TREES, Rex Vicat Cole. (21475-3) \$8.95
PERSPECTIVE FOR ARTISTS, Rex Vicat Cole. (22487-2) \$6.95
ABSTRACTION IN ART AND NATURE, Nathan Cabot Hale. (27482-9) \$15.95
ABSTRACT DESIGN AND HOW TO CREATE IT, Amor Fenn. (27673-2) \$6.95
PAINTING MATERIALS: A SHORT ENCYCLOPEDIA, Rutherford J. Gettens and George L. Stout. (21597-0) \$8.95
WILLIAM MORRIS HUNT ON PAINTING AND DRAWING, W. M. Hunt. (23398-7) \$4.95
HAWTHORNE ON PAINTING, Charles W. Hawthorne. (20653-X) \$3.95
THE PAINTER'S METHODS AND MATERIALS, A. P. Laurie. (21868-6) \$8.95
COMPOSITION IN ART, Henry R. Poore. (23358-8) \$8.95
THE ELEMENTS OF DRAWING, John Ruskin. (22730-8) \$6.95
TECHNIQUES OF DRAWING, Howard Simon. (21578-4) \$7.95
THE MATERIALS AND METHODS OF SCULPTURE, Jack C. Rich. (25742-8) \$12.95
SCULPTURE: PRINCIPLES AND PRACTICE, Louis Slobodkin. (22960-2) \$10.95
SCULPTURE IN WOOD, Jack C. Rich. (27109-9) \$8.95

Paperbound unless otherwise indicated. Prices subject to change without notice. Available at your book dealer or write for free catalogues to Dept. 23, Dover Publications, Inc., 31 East 2nd Street, Mineola, N.Y. 11501. Please indicate field of interest. Each year Dover publishes over 200 books on fine art, music, crafts and needlework, antiques, languages, literature, children's books, chess, cookery, nature, anthropology, science, mathematics, and other areas.

Manufactured in the U.S.A.

AN ATLAS OF ANIMAL ANATOMY FOR ARTISTS

W. ELLENBERGER H. DITTRICH H. BAUM

Edited by Lewis S. Brown

Here are 288 remarkably life like drawings of animals, furnishing artists and students with an easy-to-follow method of instruction in the drawing of horses, dogs, lions, cows and bulls, stags, roes, and goats. So detailed and so accurate are these drawings that this book has long been a classic work of its kind.

The animals are shown in three ways: external full views and dozens of details (paws, head, eyes, legs, etc.); beneath-the-skin drawings of musculature and of the positions and insertions of each muscle; and skeleton drawings of the bone structures that support and determine surface contours and configurations. In addition, special cross-sections dissect those portions of the animal—such as the head and limbs—that are most important to the artist.

For this edition, Lewis S. Brown of the American Museum of Natural History collected 25 plates from George Stubbs' *Anatomy of the Horse*, long unavailable; Straus-Durckheim's *Anatomie Descriptive et Comparative du Chat*; and Cuvier and Laurillard's *Anatomie Comparée*. These plates, as fully annotated as the plates that make up the original book, supplement Ellenberger, Baum and Dittrich with anatomical drawings of the monkey, the bat, the flying squirrel, the rat kangaroo, the seal, and the hare. Mr. Lewis also provided a new preface and added to the annotated bibliography, which now contains 66 items.

"Highly recommended as one of the very few books on the subject worthy of being used as an authoritative guide," *Design*. "Illustrators, sculptors, and taxidermists who draw or model animals will welcome this new revised edition," *Natural History*.

Enlarged (1956) edition, revised by Lewis S. Brown, American Museum of Natural History. New Preface. 99 full-page plates. 288 figures. Two charts of standard horse measurements. Annotated bibliography. viii + 151pp. 9 $\frac{3}{4}$ × 12 $\frac{1}{4}$. Paperbound.

A DOVER EDITION DESIGNED FOR YEARS OF USE!

We have made every effort to make this the best book possible. Our paper is opaque, with minimal show-through; it will not discolor or become brittle with age. Pages are bound in signatures, in the method traditionally used for the best books, and will not drop out. Books open flat for easy reference. The binding will not crack or split. This is a permanent book.

Free Dover Fine Art and Art Instruction Catalog (58283-3) available upon request.

ISBN 0-486-20082-



\$10.95 IN USA

9 780486 200828